

SNS COLLEGE OF PHYSIOTHERAPY

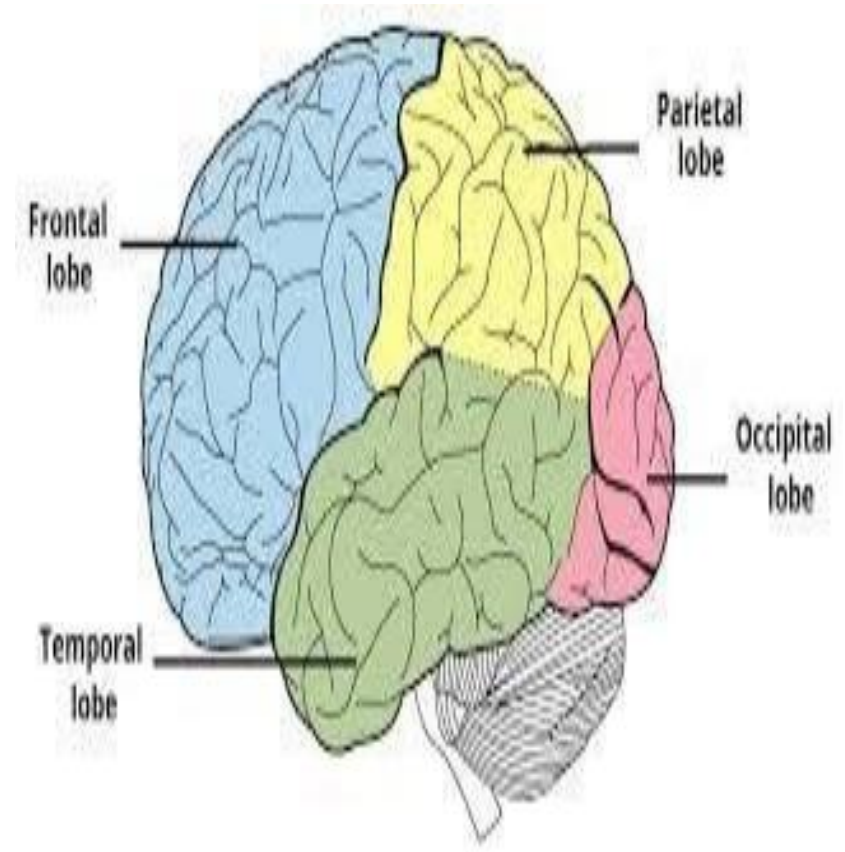
COIMBATORE - 641035

COURSE NAME: PHYSIOTHERAPY IN NEUROLOGICAL SCIENCES
IV YEAR

TOPIC: STRUCTURE AND FUNCTION OF CEREBRAL HEMISPHERE

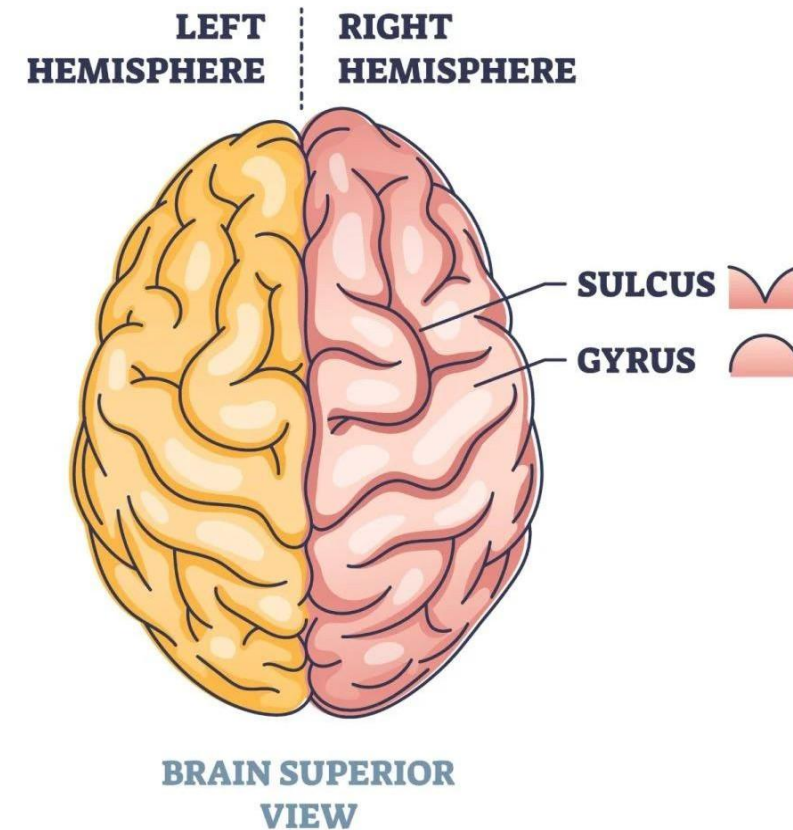
Overview of the Human Brain

- The brain is divided into forebrain, midbrain, and hindbrain.
- Forebrain includes the cerebrum, which makes up ~80% of brain mass.
- Cerebrum consists of two cerebral hemispheres connected by the corpus callosum.
- Key roles: Higher cognition, sensory processing, motor control.



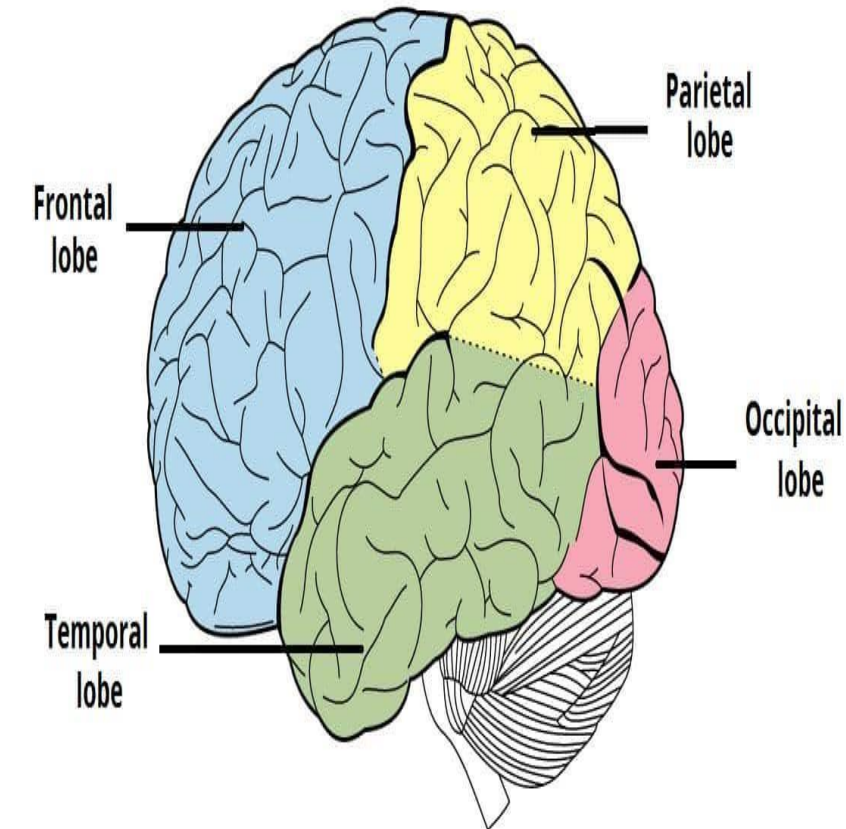
Surface Anatomy: Gyri and Sulci

- Gyri: Elevated ridges on the cerebral surface.
- Sulci: Grooves between gyri; increase surface area for neurons.
- Major sulci: Central sulcus (separates frontal and parietal lobes), lateral sulcus (separates temporal lobe).
- Fissures: Deeper grooves, e.g., longitudinal fissure.



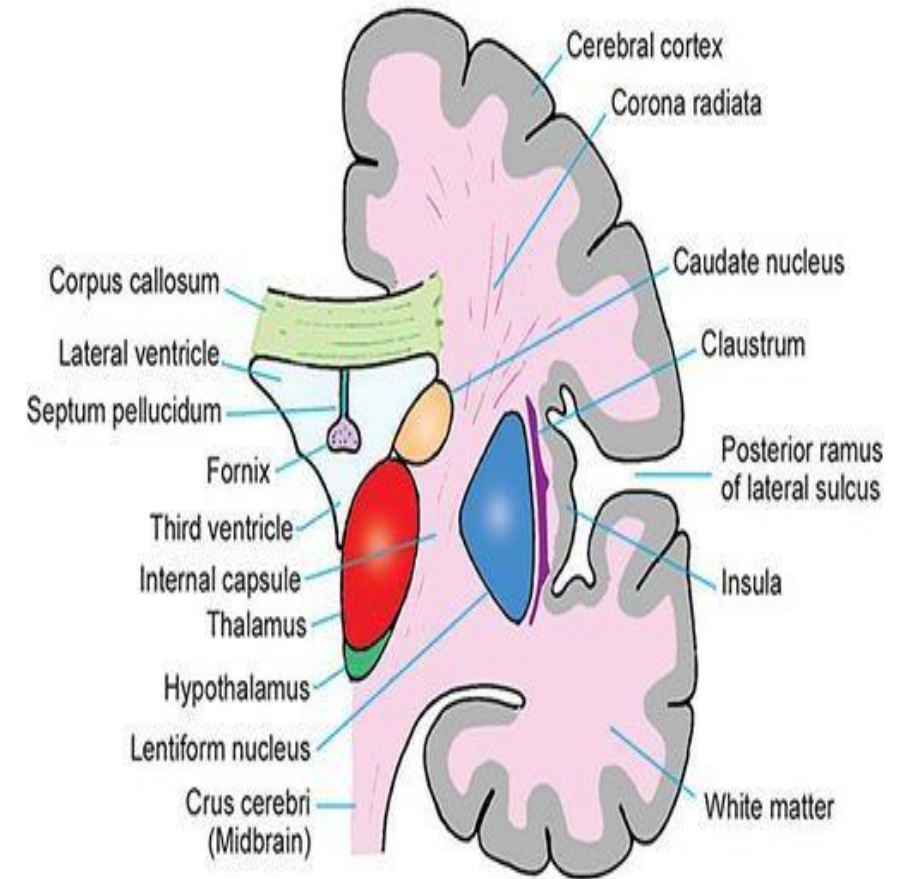
Division into Lobes

- Each hemisphere divided into four lobes: Frontal, Parietal, Temporal, Occipital.
- Boundaries defined by major sulci and fissures.
- Insula: Hidden lobe deep within lateral sulcus.
- Limbic lobe: Medial aspect, involved in emotion and memory.



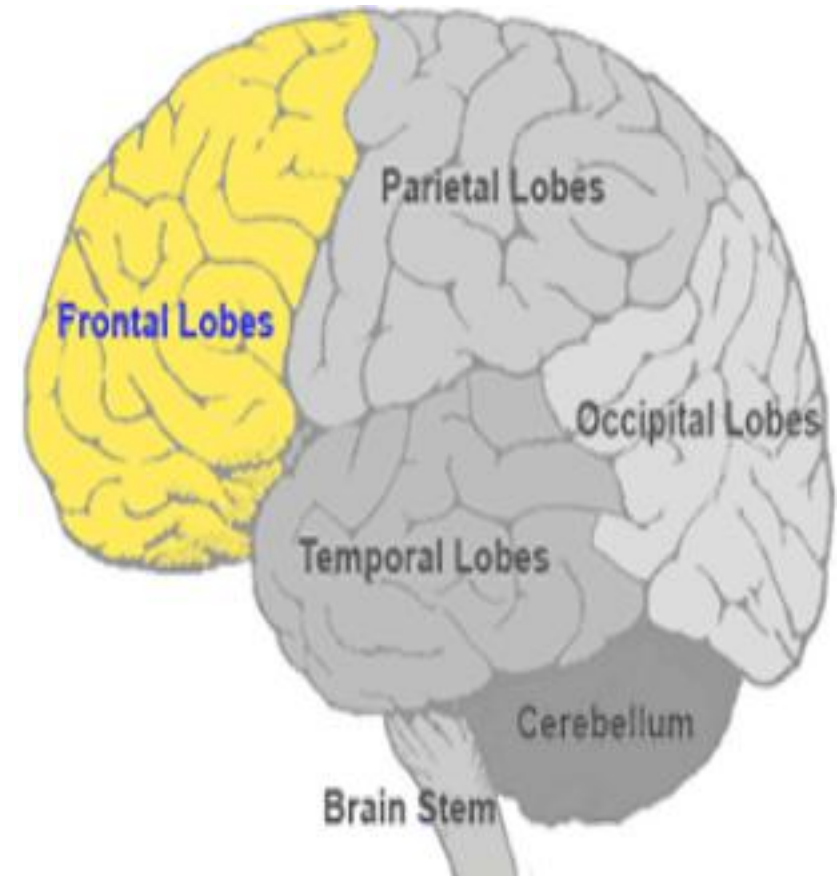
Internal Structure Overview

- Gray matter: Cerebral cortex (outer layer) and basal nuclei.
- White matter: Fiber tracts connecting regions (association, commissural, projection fibers).
- Ventricles: Lateral ventricles within each hemisphere.
- Blood supply: Via carotid and vertebral arteries.



Frontal Lobe - Structure

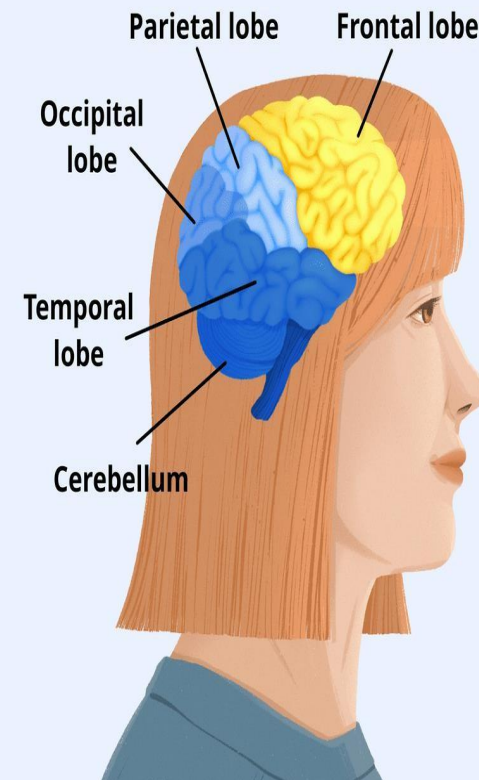
- Largest lobe, anterior to central sulcus.
- Key areas: Precentral gyrus (primary motor cortex), prefrontal cortex.
- Broca's area (left hemisphere): Speech production.
- Extends from frontal pole to central sulcus.



Frontal Lobe - Functions

- Motor control: Voluntary movements via primary motor cortex.
- Executive functions: Planning, decision-making, problem-solving.
- Personality and behavior regulation.
- Speech: Broca's area for motor speech.

Functions of the Frontal Lobe

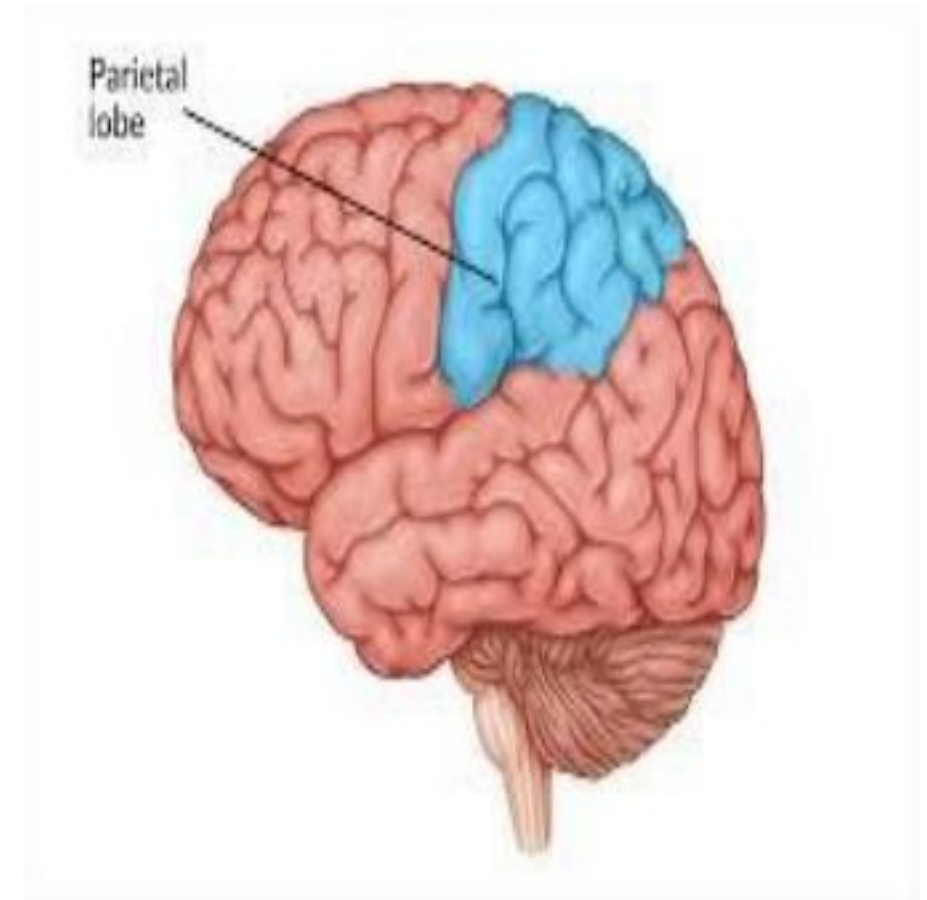


- Motor control
- Thinking
- Memory
- Reasoning
- Self-control
- Maintaining social expectations
- Planning
- Abstract thinking

verywellhealth

Parietal Lobe - Structure

- Posterior to central sulcus, superior to lateral sulcus.
- Key areas: Postcentral gyrus (primary somatosensory cortex).
- Superior and inferior parietal lobules.
- Involved in spatial processing regions.

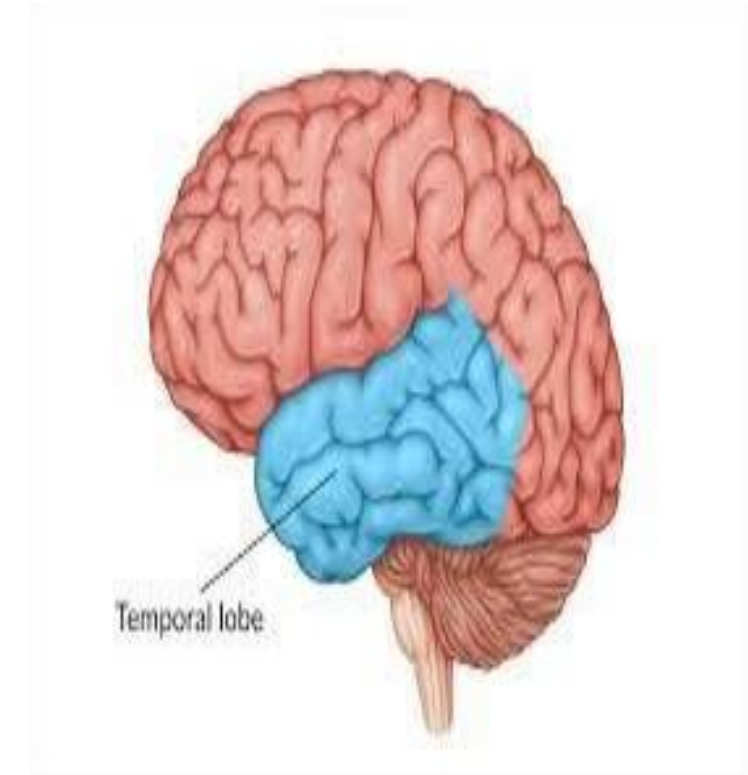


Parietal Lobe - Functions

- Somatosensory processing: Touch, pain, temperature, proprioception.
- Spatial awareness and navigation.
- Integration of sensory information.
- Attention and perception of surroundings.

Temporal Lobe - Structure

- Inferior to lateral sulcus, anterior to occipital lobe.
- Key areas: Superior temporal gyrus (auditory cortex), hippocampus (medial).
- Wernicke's area (left hemisphere): Language comprehension.
- Includes amygdala for emotion.

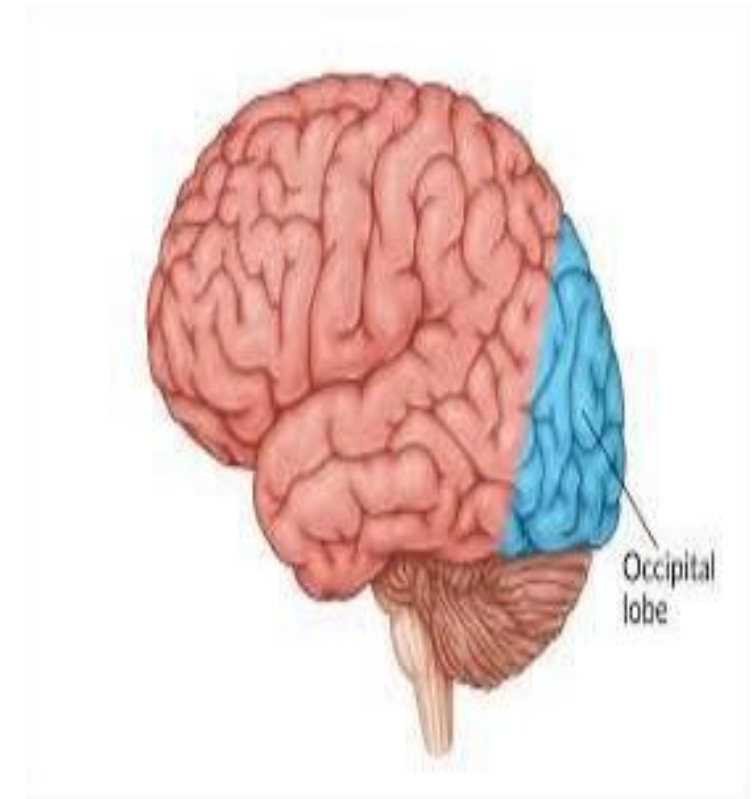


Temporal Lobe - Functions

- Auditory processing: Hearing and sound recognition.
- Memory formation: Hippocampus for long-term memory.
- Language comprehension: Wernicke's area.
- Emotion and olfaction: Amygdala and olfactory cortex.

Occipital Lobe - Structure

- Posterior lobe, separated by parieto-occipital sulcus.
- Key area: Primary visual cortex (calcarine sulcus).
- Visual association areas surround primary cortex.
- Smallest lobe in size.

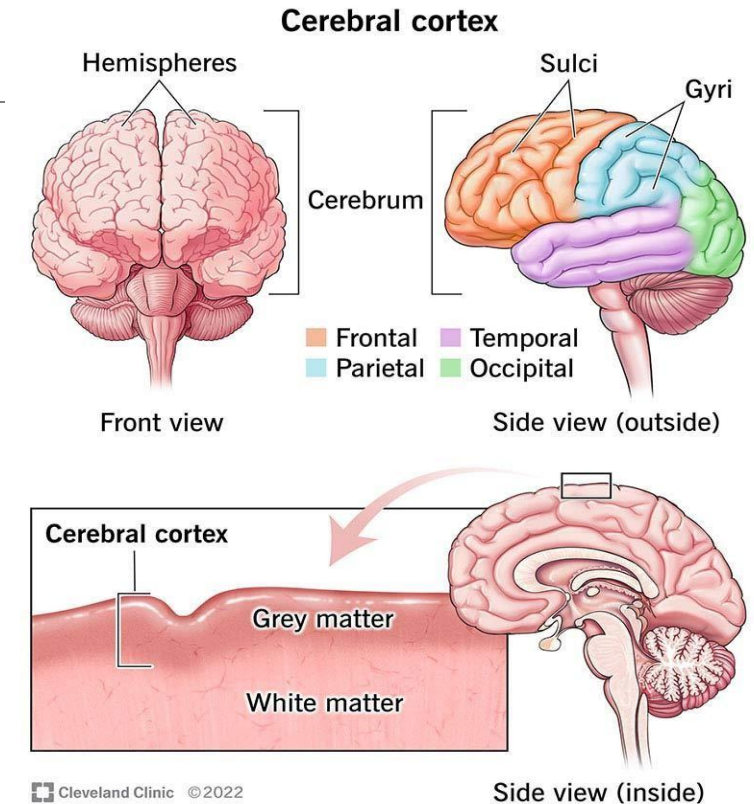


Occipital Lobe - Functions

- Visual processing: Interpretation of sight, color, motion.
- Primary visual cortex: Receives input from optic nerves.
- Association areas: Object recognition, depth perception.
- Integration with other lobes for visuospatial tasks.

Cerebral Cortex Layers

- Six-layered structure (neocortex): Layers I-VI with specific cell types.
- Layer IV: Input from thalamus.
- Pyramidal cells in layers III and V for output.
- Variations by region (e.g., motor cortex has thicker layer V).

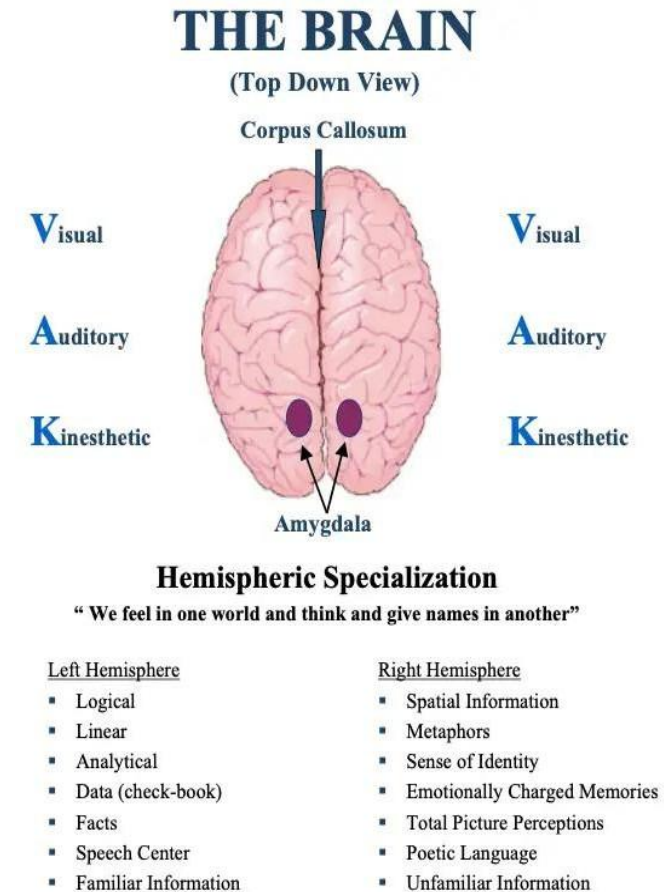


White Matter and Fiber Tracts

- Association fibers: Connect areas within same hemisphere (e.g., arcuate fasciculus).
- Commissural fibers: Connect hemispheres (corpus callosum).
- Projection fibers: Connect cortex to lower brain/spinal cord (corticospinal tract).
- Role in communication and integration.

Hemispheric Specialization

- Lateralization: Left hemisphere - language, logic, analytical thinking.
- Right hemisphere - spatial, creative, emotional processing.
- Corpus callosum enables inter-hemispheric communication.
- Split-brain studies: Insights from severed corpus callosum.



Clinical Correlations

- Lesions: Frontal - personality changes; Parietal - neglect syndrome.
- Temporal - memory loss (e.g., Alzheimer's); Occipital - visual agnosia.
- Stroke: Affects one hemisphere, causing contralateral deficits.
- Epilepsy: Often originates in temporal lobe.

Clinical Correlations

Lobe

Frontal

Parietal

Temporal

Occipital

Common Lesion Effects

Impaired judgment, motor weakness

Sensory loss, spatial disorientation

Auditory hallucinations, amnesia

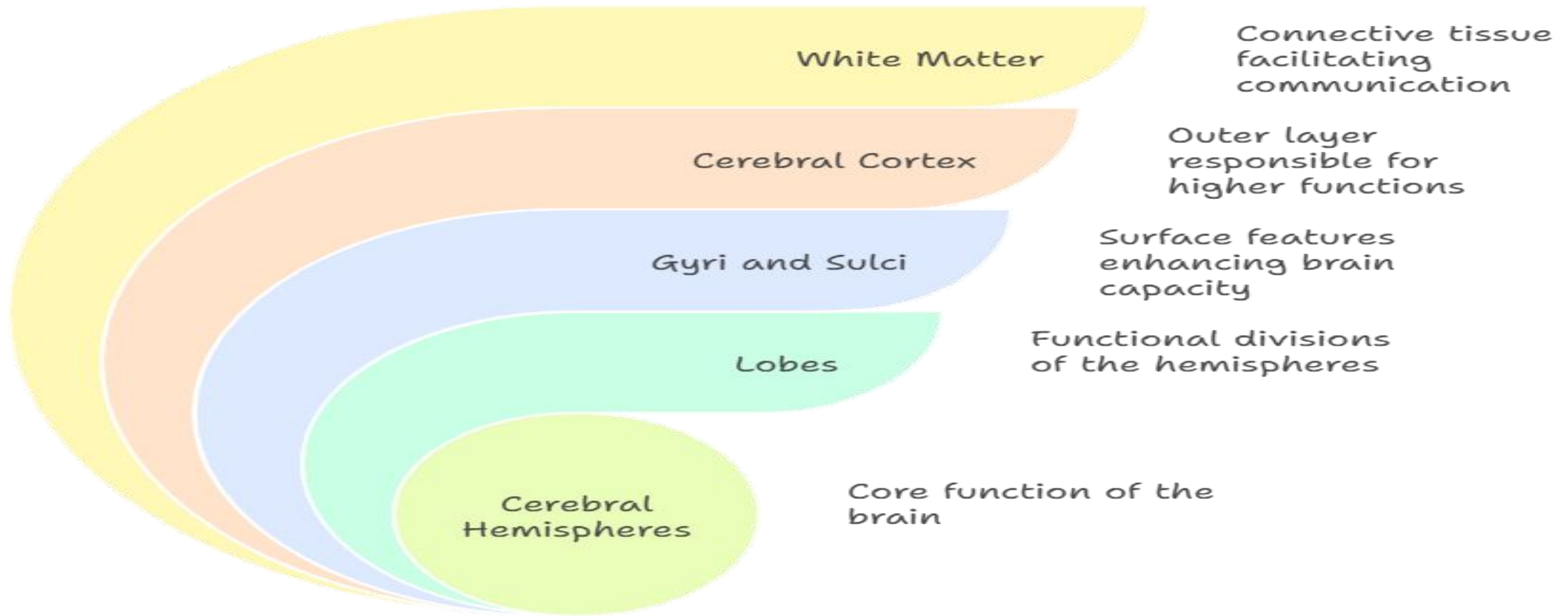
Blindness in visual fields

Summary

- Cerebral hemispheres: Core of higher brain functions.
- Structure: Lobes, cortex, white matter.
- Functions: Sensory, motor, cognitive integration.
- Importance: Basis for human intelligence and behavior.

Thank you

Cerebral Hemisphere Structure and Function



Made with  Napkin