

Forearm and Hand

Anatomy B.P.T 1 year

Region which allows the twisting movement while executing functional movements !

Region which serves as the second/middle part of lever chain in upper limb....

Region where muscles, tendons, bursae, blood vessels and nerves are artistically placed and protected in this region !

Anatomically its denoted as?



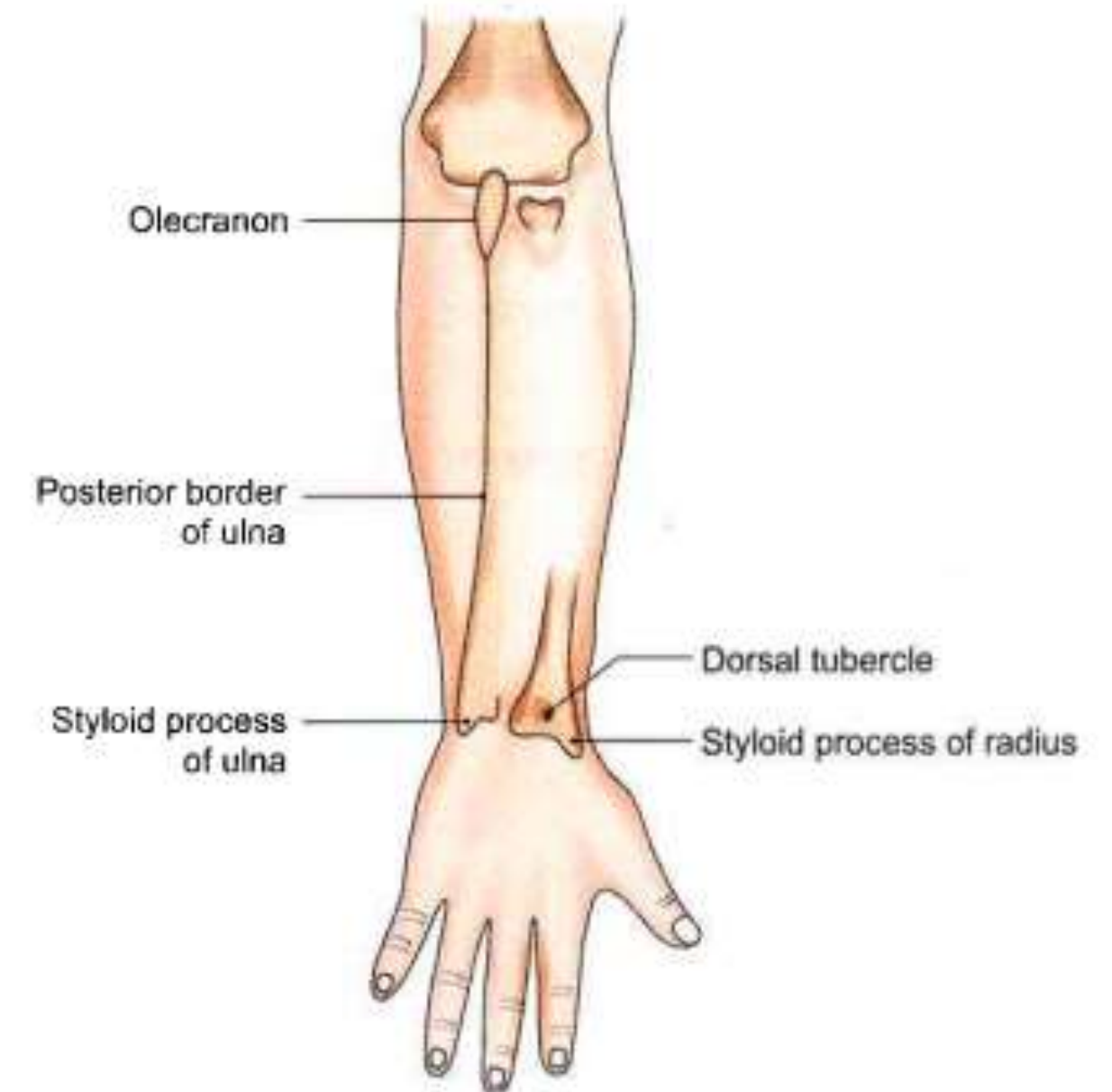
Forearm – Surface landmarks

On the Front of Forearm

1. Medial and lateral epicondyles of the humerus
2. Tendon of biceps brachii
3. Head of radius and olecranon process of the ulna

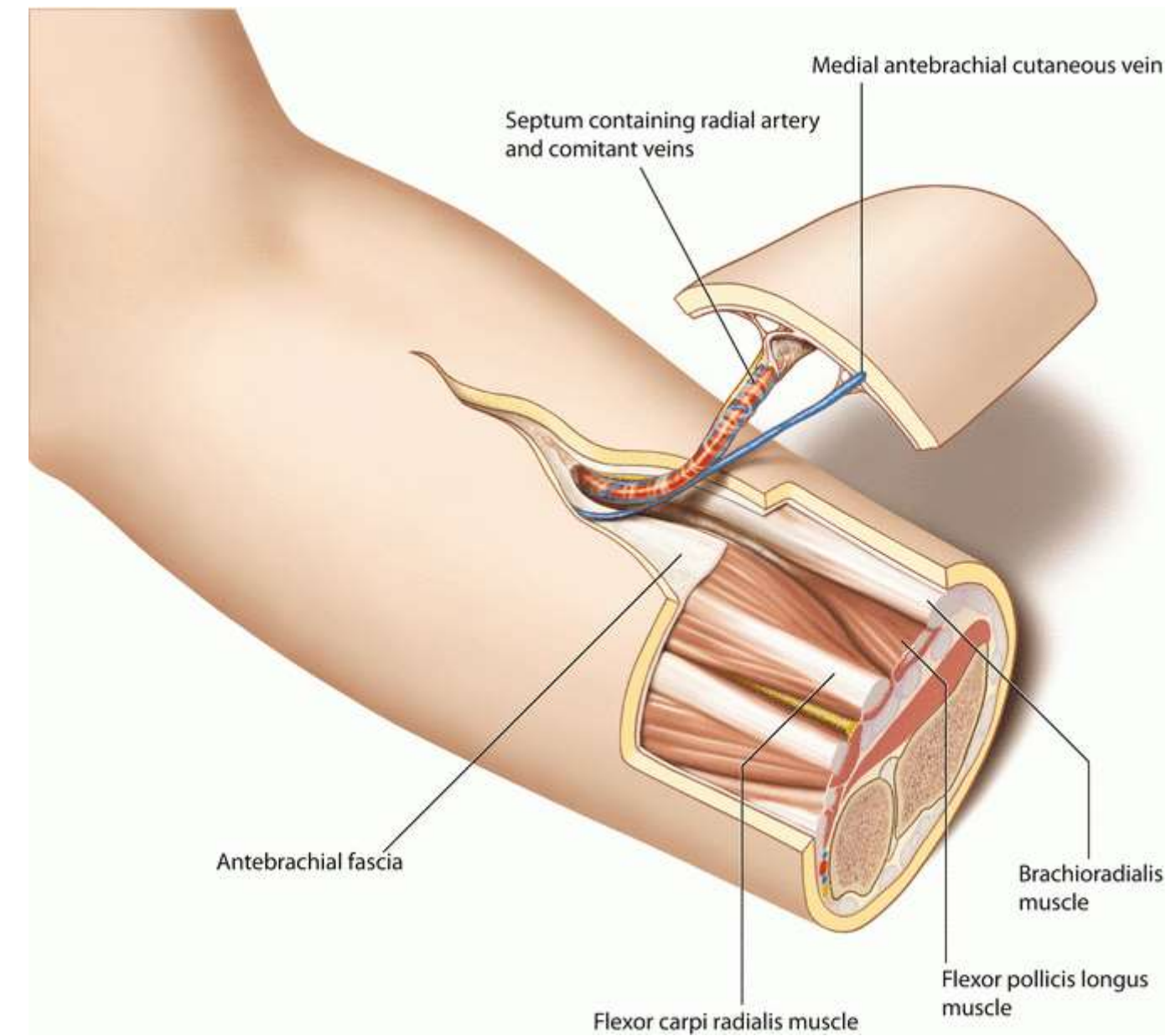
On the Back of Forearm

1. Olecranon process of the ulna
2. Posterior border of the ulna
3. Styloid processes of the radius and ulna
4. Dorsal tubercle of the radius



Fascia

- The forearm is enclosed in sheath of deep fascia of the forearm (antebrachial fascia).
- Attachment → posterior subcutaneous border of the ulna.
- This deep fascia, together with interosseous membrane and fibrous intermuscular septa divide the forearm into several compartments



Compartments of forearm

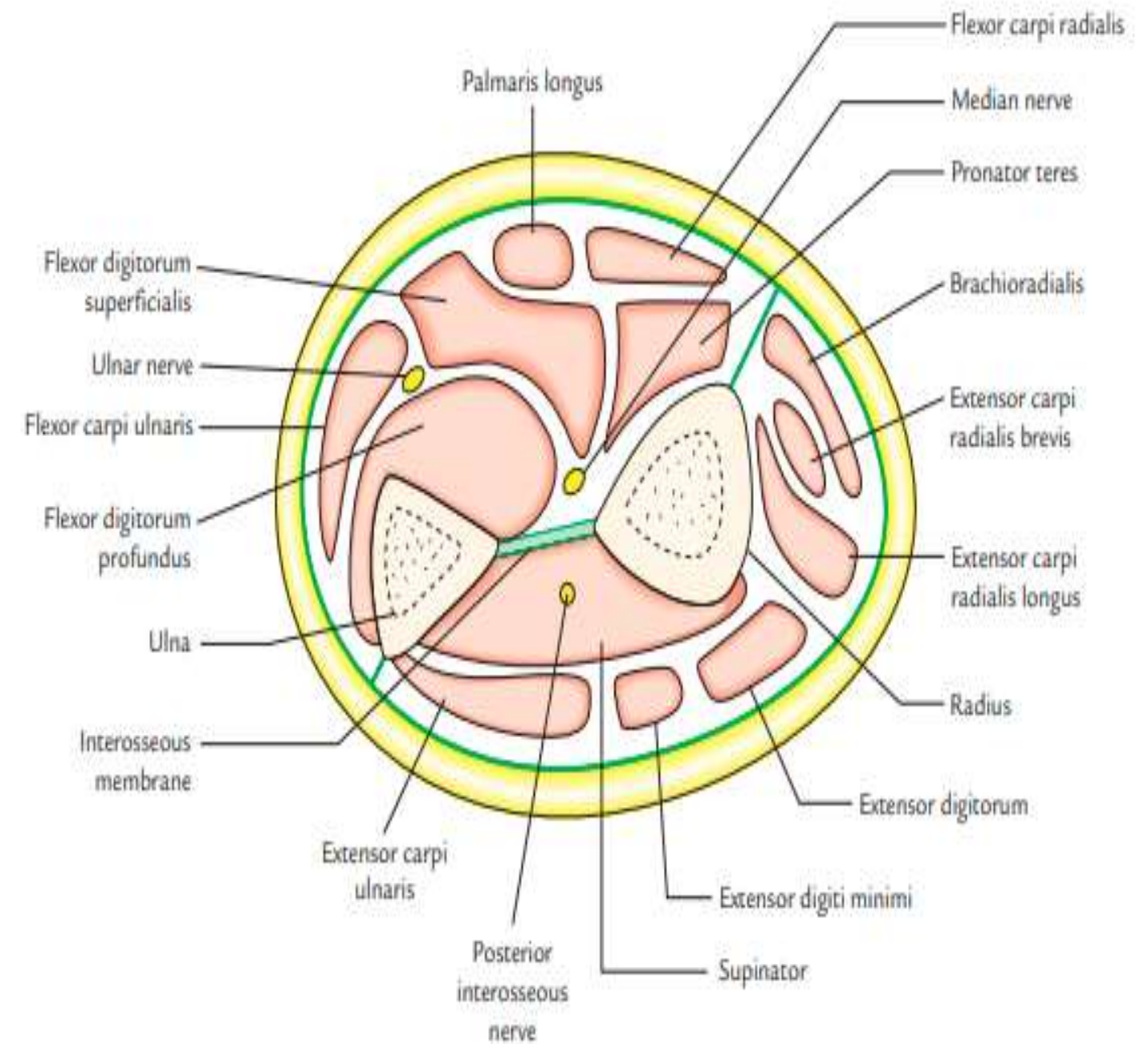
Divided into the two compartments:

- (a) Anterior compartment - structures on the front of the forearm
- (b) Posterior compartment - the structure on the back of the forearm.

At wrist, the deep fascia presents two localized thickenings,

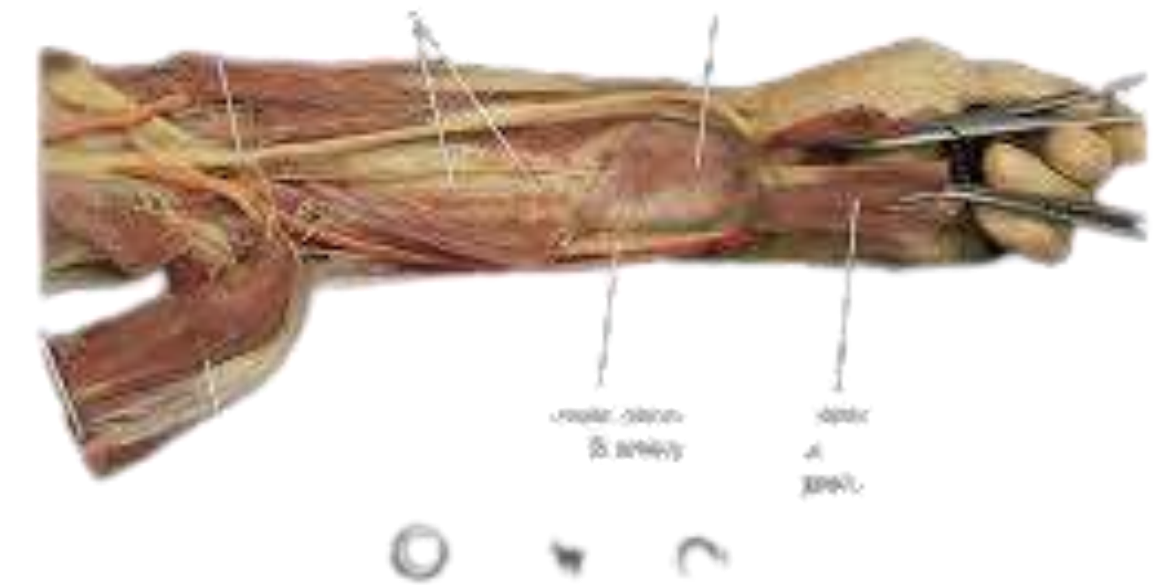
- the flexor retinacula
- extensor retinacula,

Purpose : Retains the digital tendons in position during hand movements.



Contents in front of forearm

- 1. Muscles:** Eight muscles arranged in two groups :
5 superficial muscles
3 deep muscles
- 2. Arteries:** Two arteries, radial and ulnar.
- 3. Nerves:** Three nerves, median, ulnar, and radial.





Muscles of Front of Forearm

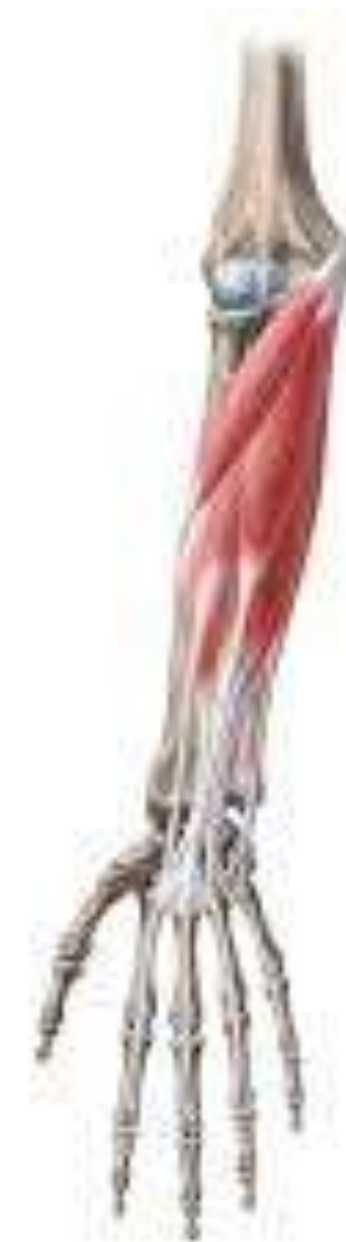

Superficial Muscles of Front of Forearm

Five muscles (lateral to medial side)

1. Pronator teres.
2. Flexor carpi radialis.
3. Palmaris longus.
4. Flexor digitorum superficialis.
5. Flexor carpi ulnaris

All are flexor of the forearm and having common origin—from the front of the medial epicondyle of the humerus called **common flexor origin**





Pronator Teres



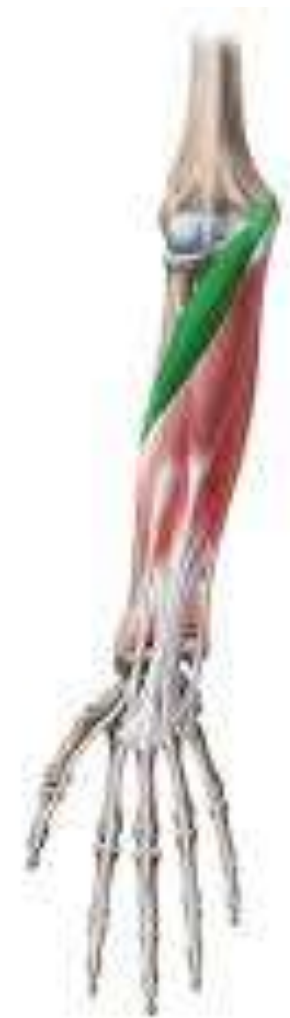- ✓ Smallest and most lateral of the superficial muscles
- ✓ Flexors of the forearm.
- ✓ Forms the medial boundary of the cubital fossa.

Origin :

Two heads

- superficial (humeral) head from the medial epicondyle of the humerus
- deep (ulnar) head from the medial margin of the coronoid process of the ulna.

Note : Median nerve passes between the two heads of pronator teres.

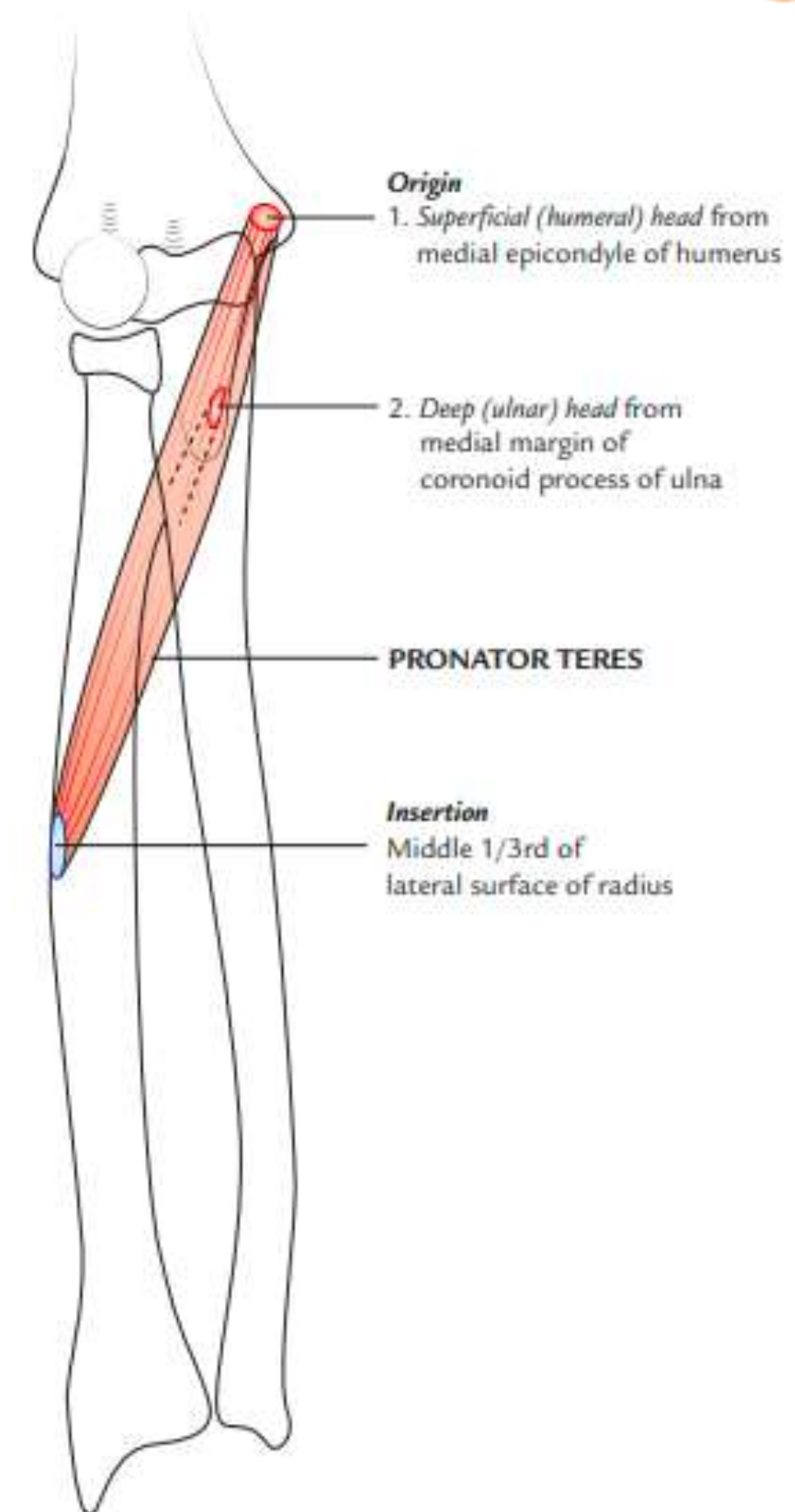


Muscles of Front of Forearm

Insertion :

Radius → Rough impression on the middle one-third of the lateral surface

Nerve supply : Median nerve



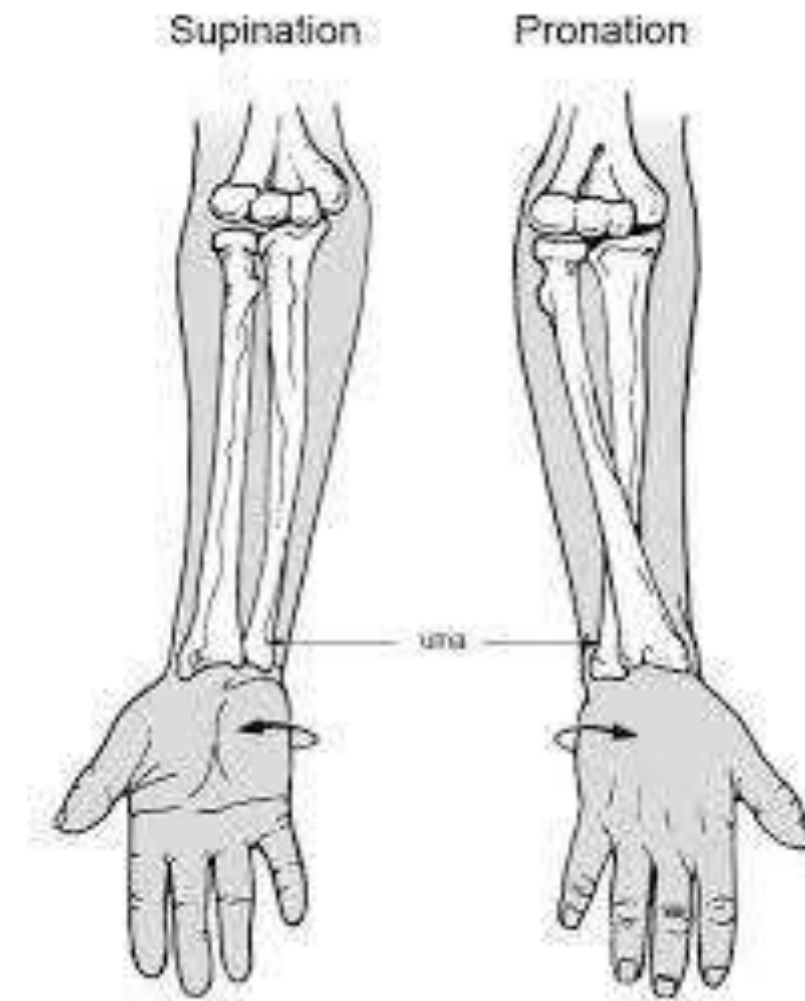
Pronator Teres

Actions :

- Primary pronator of the forearm.
- Helps in the flexion of elbow.

Clinical testing

Ask the patient to pronate the forearm from supine position against resistance with elbow flexed



Flexor Carpi Radialis

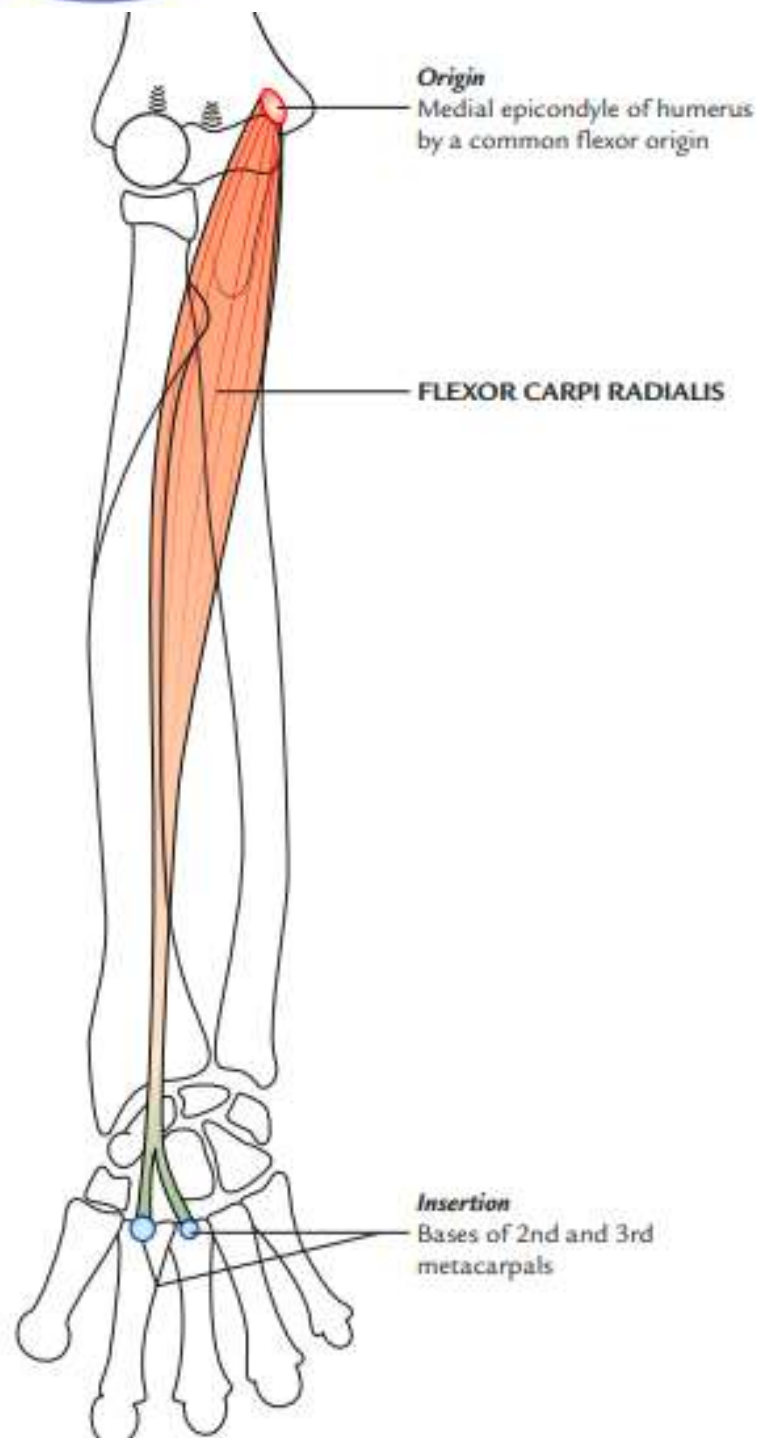
Origin :

Medial epicondyle of humerus by a common flexor origin.

Insertion :

Anterior aspects of the bases of 2nd and 3rd metacarpals.

Nerve supply Median nerve.





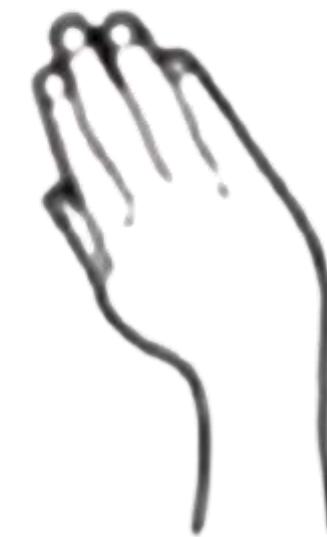Flexor Carpi Radialis



Actions

1. Along with flexor carpi ulnaris, for **flexing the wrist**
2. Along with brachioradialis, **abducts the wrist (Radial deviation)**

Note : The tendon of this muscle is a good guide to the radial artery, which lies just lateral to it at the wrist





Palmaris Longus



Origin :

Medial epicondyle of humerus by a common flexor origin.

Insertion : Flexor retinaculum and palmar aponeurosis.

Its long cord-like tendon crosses superficial to the flexor retinaculum.

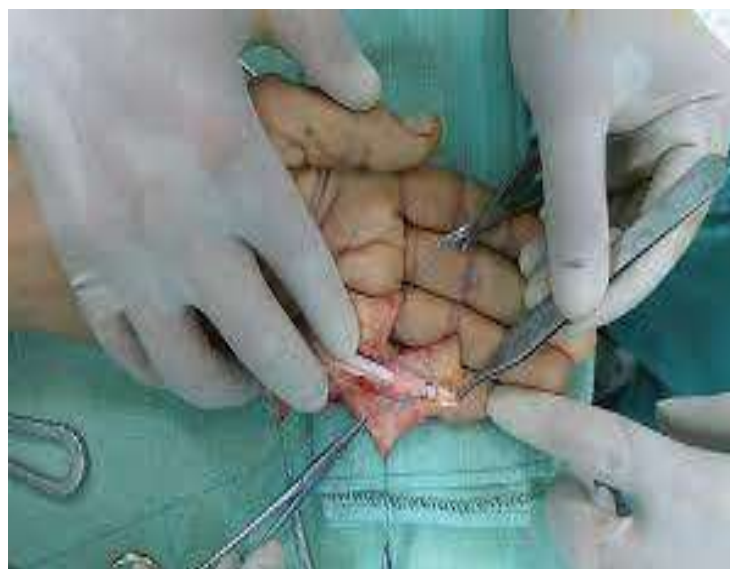

Palmaris Longus

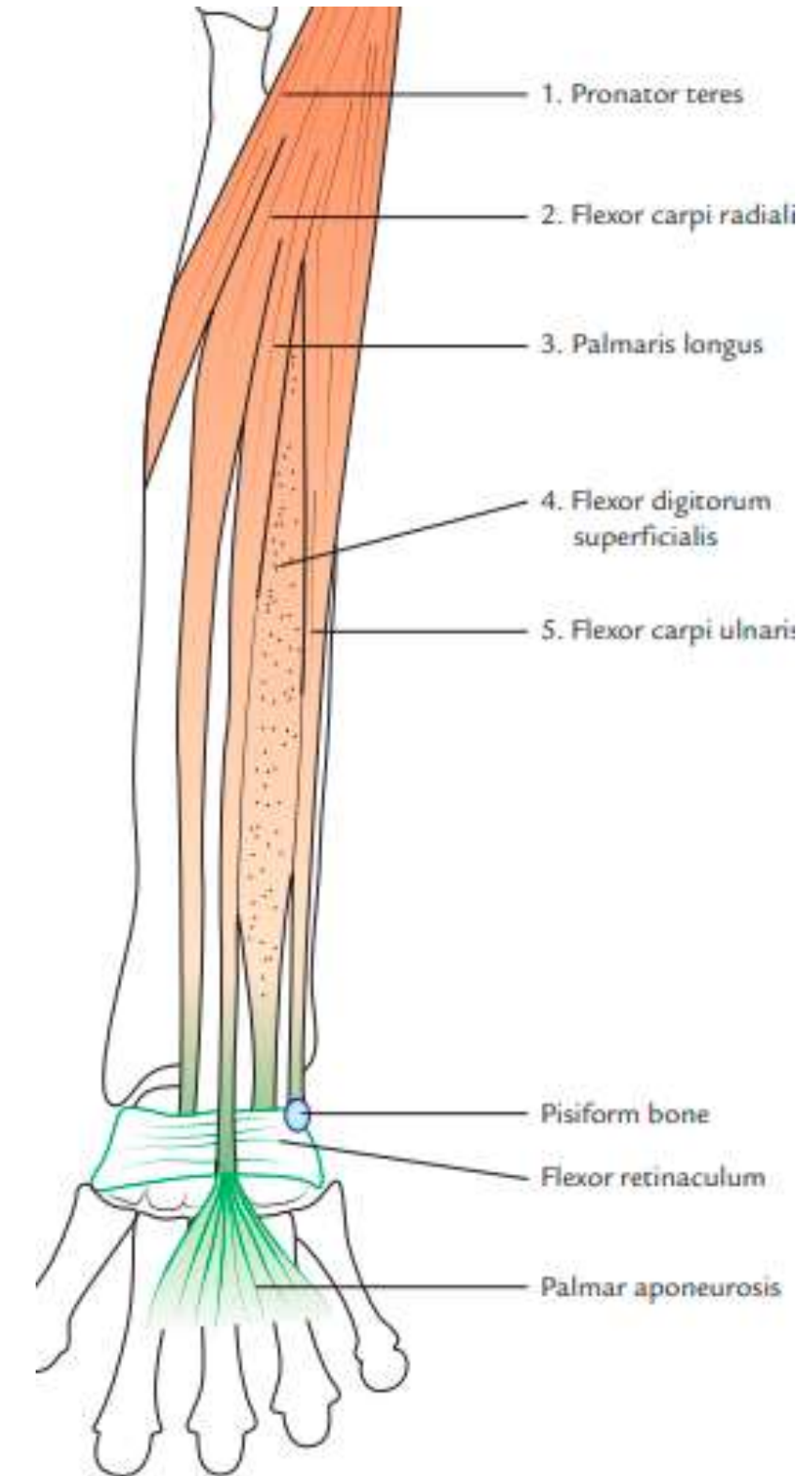
Nerve supply : Median nerve.

Actions :

It **flexes** the wrist and makes the palmar aponeuroses tense.



Clinical note : this tendon is often used by the surgeons for tendon grafting.



Flexor Carpi Ulnaris

Most medial of the superficial flexors of the forearm

Origin

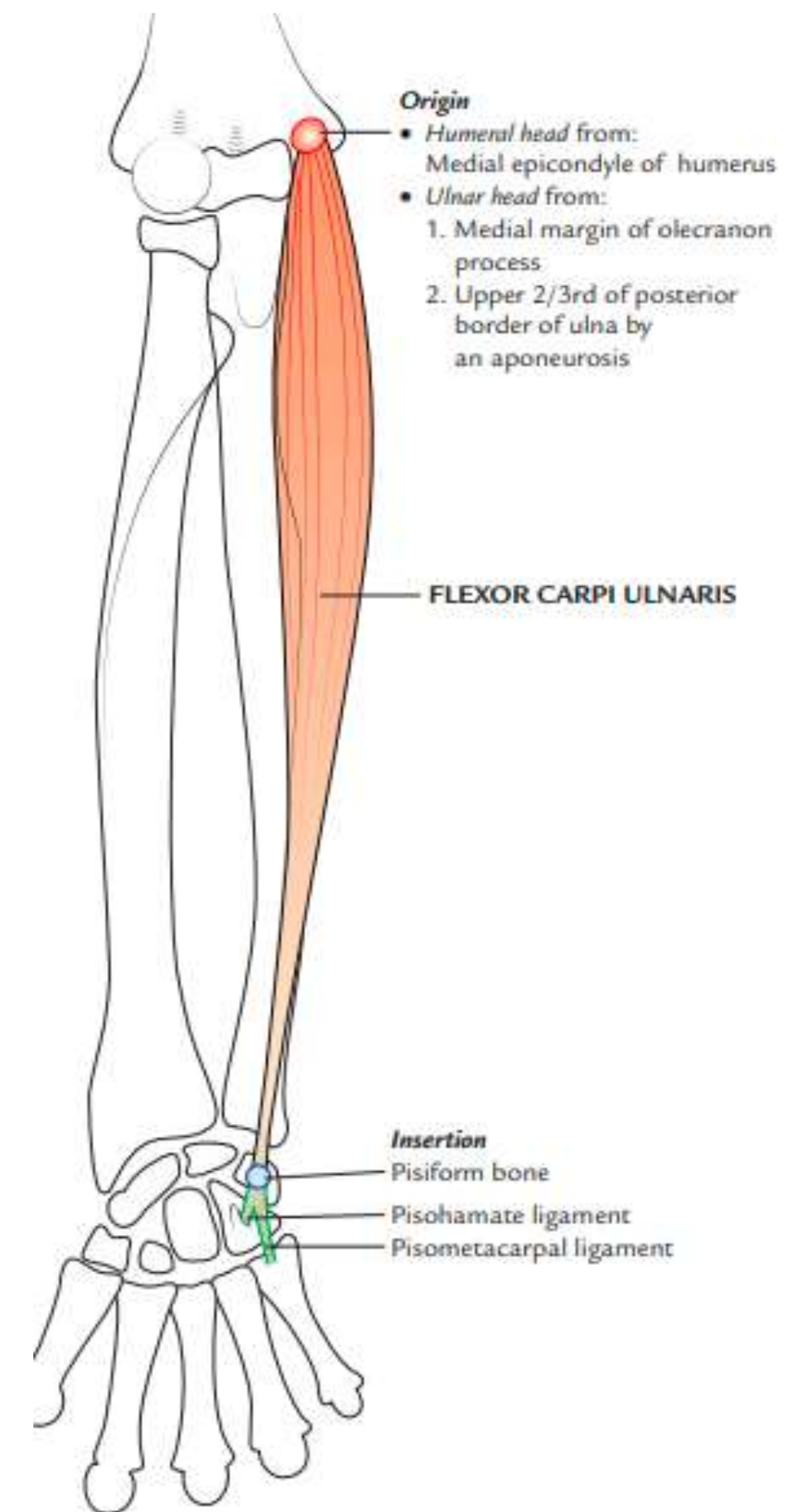
Arises by two heads:

(a) Humeral head → **medial epicondyle of the humerus (small head)**

- (b) Ulnar head →
- Medial margin of the olecranon process
 - An aponeurosis from the upper two-third of the posterior border of the ulna (**long head**)



© www.kenhub.com
KEN HUB

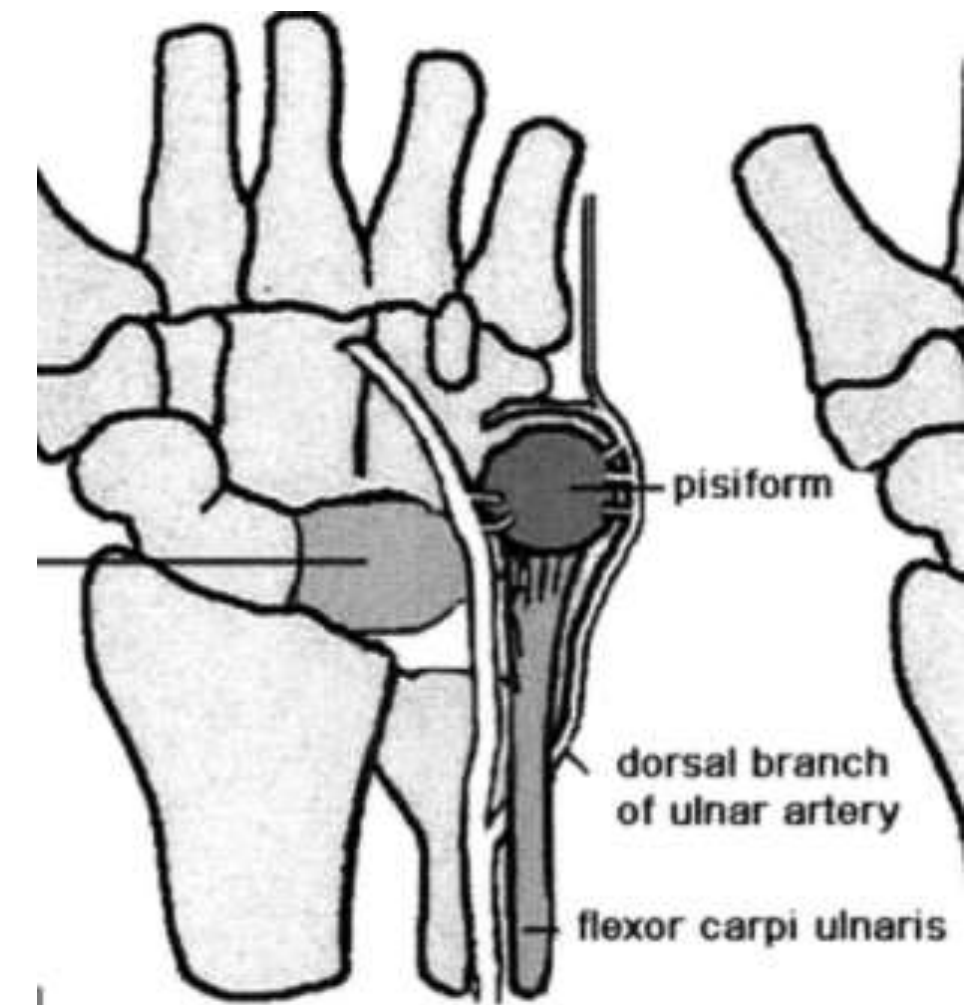


Flexor Carpi Ulnaris

Insertion :

- (a) pisiform bone
- (b) hook of hamate
- (c) base of fifth metacarpal bone → through pisohamate and pisometacarpal ligaments, respectively

Last is the true insertion because a sesamoid bone (pisiform) develops in its tendon.





Flexor Carpi Ulnaris



Nerve supply: Ulnar nerve.

Actions

1. Along with the extensor carpi ulnaris → adducts the wrist joint (Ulnar deviation)
2. Along with the flexor carpi radialis, it flexes the wrist joint

Note: The ulnar nerve enters the forearm by passing between the two heads of flexor carpi ulnaris.



Flexor Digitorum Superficialis

Largest muscle of the superficial group

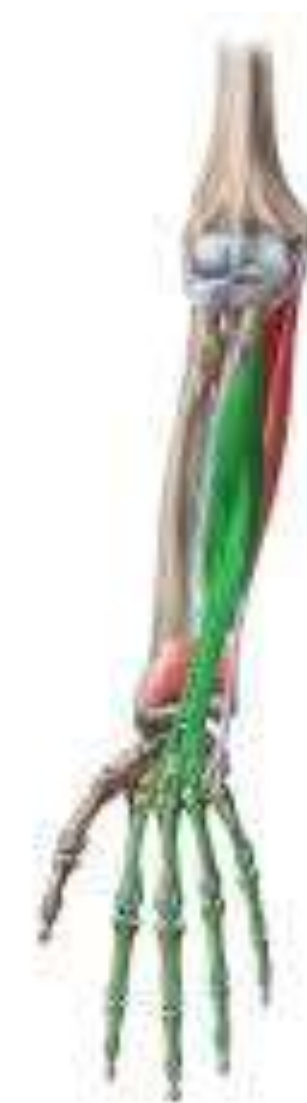Origin :

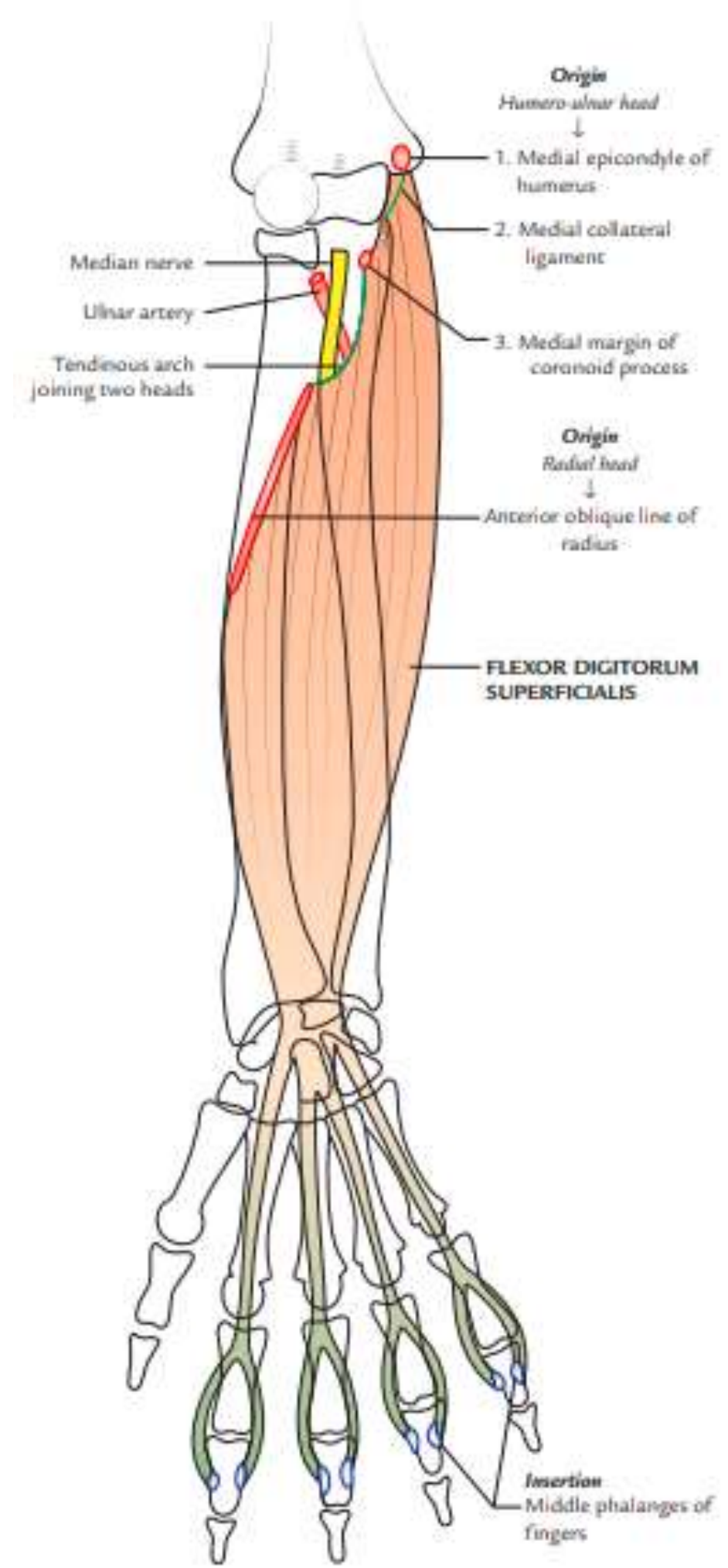
(a) humero-ulnar head

- medial epicondyle of humerus
- sublime tubercle on the medial margin
- coronoid process of ulna and medial (ulnar) collateral ligament

(b) radial head

- anterior oblique line of the radius
- radial tuberosity





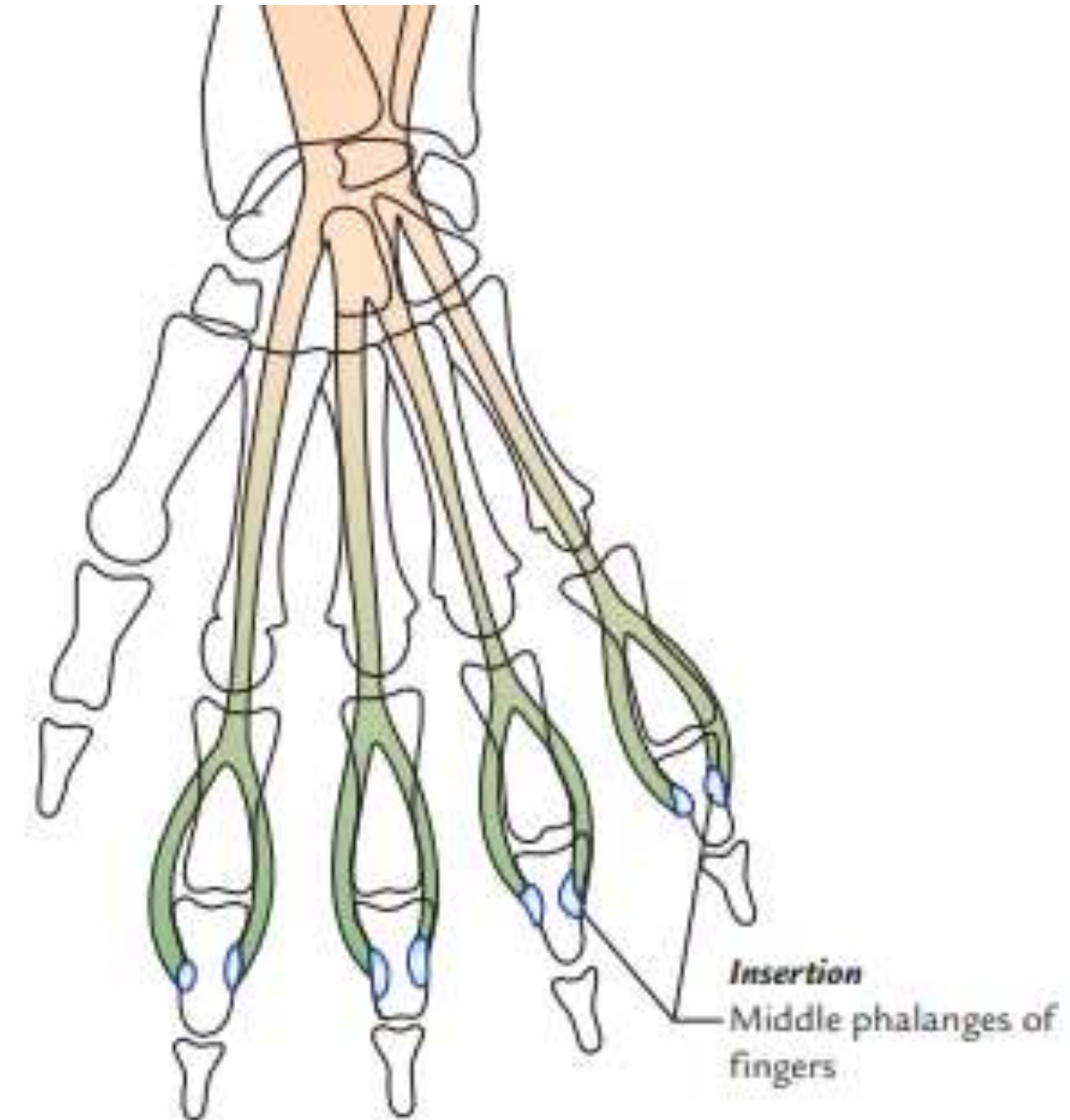
Flexor Digitorum Superficialis

Insertion :

Middle phalanges

The muscles splits into two layers:

- The superficial layer forms two tendons, → middle phalanges of middle and ring fingers.
- The deep layer also forms two tendons → middle phalanges index and little fingers of medial four fingers





Flexor Digitorum Superficialis

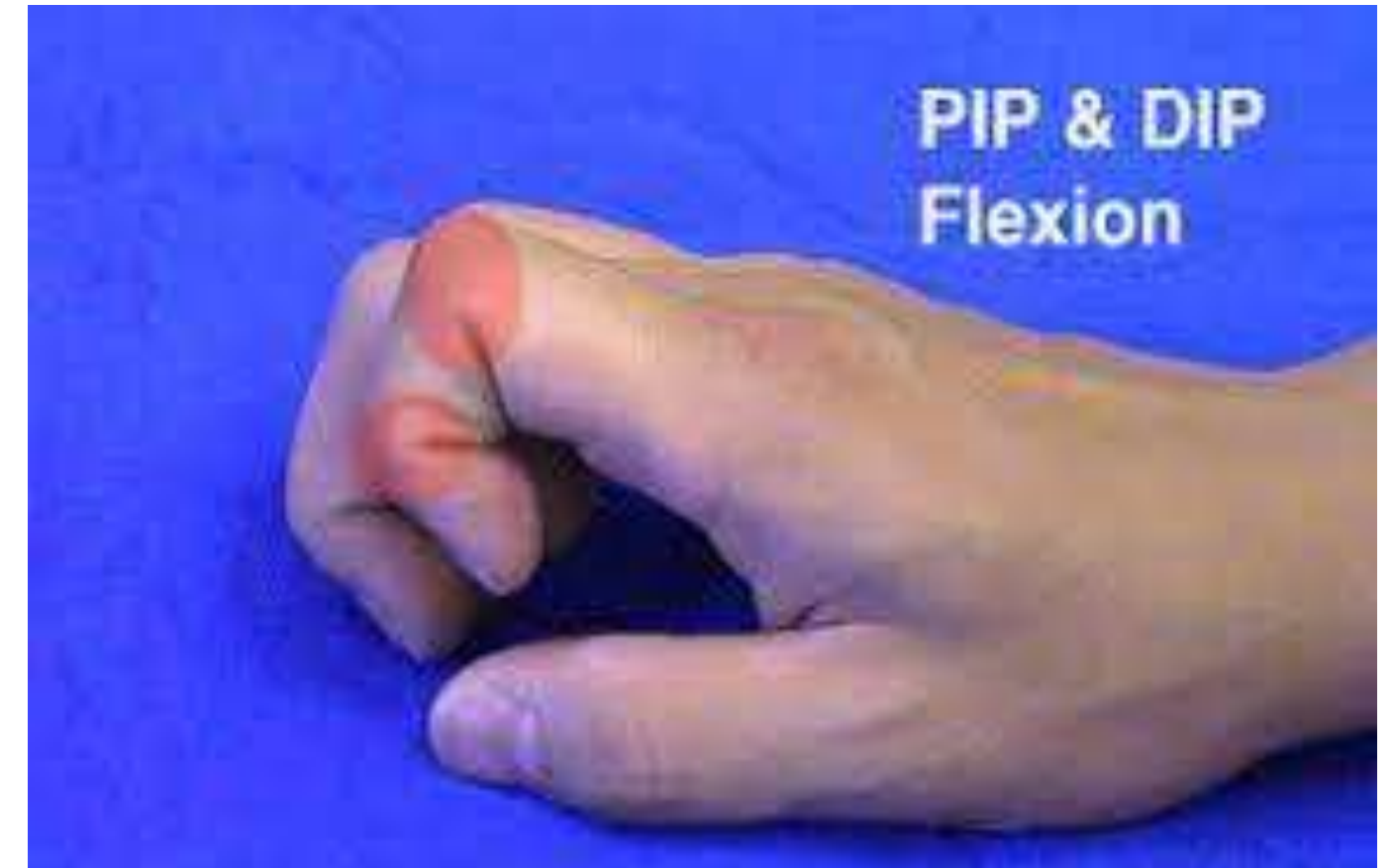

Nerve supply → median nerve.

Actions

Flexes the proximal interphalangeal (PIP) joints of the medial four digits.

Acting more strongly, it also helps in flexion of the proximal phalanges and wrist joint

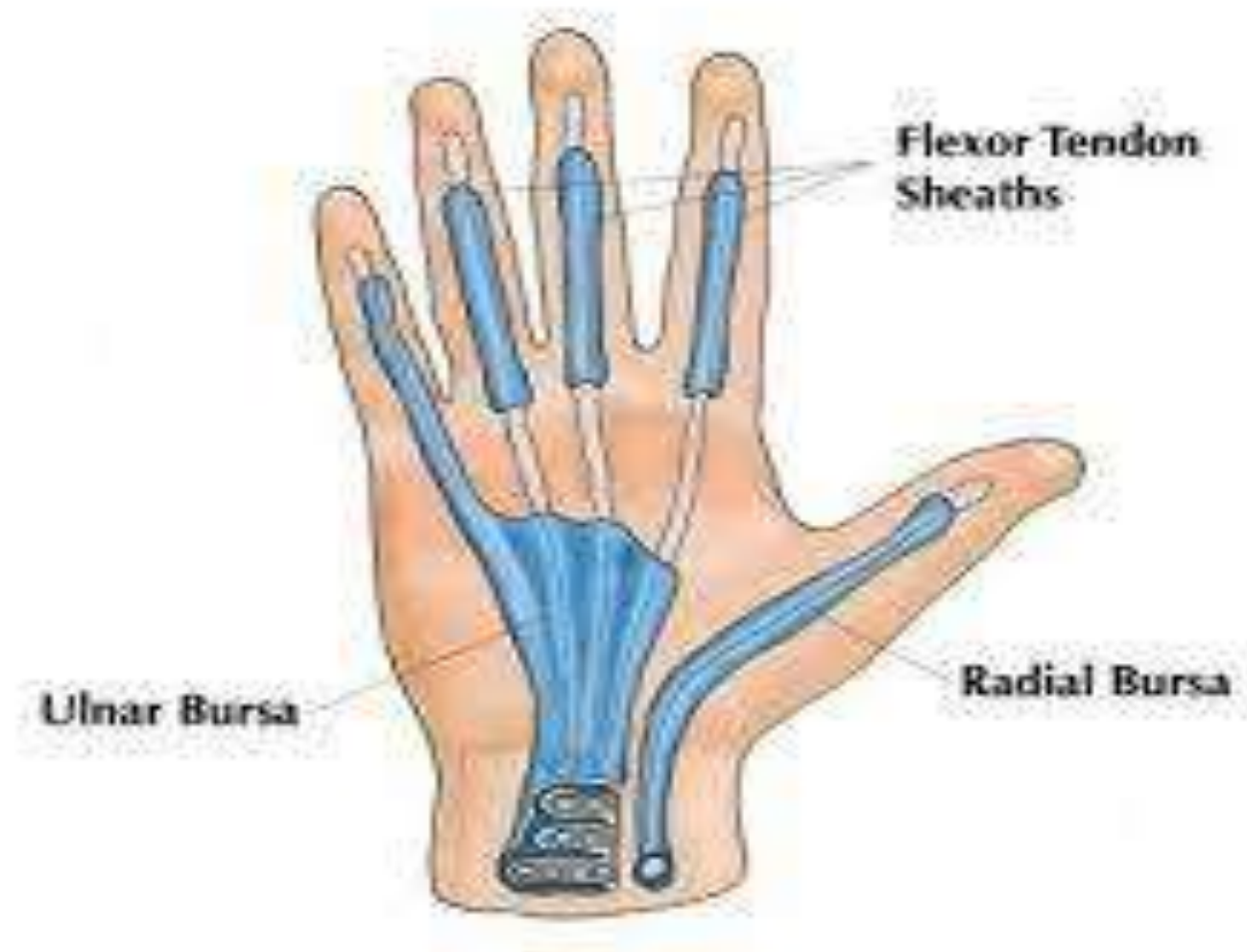



Flexor Digitorum Superficialis



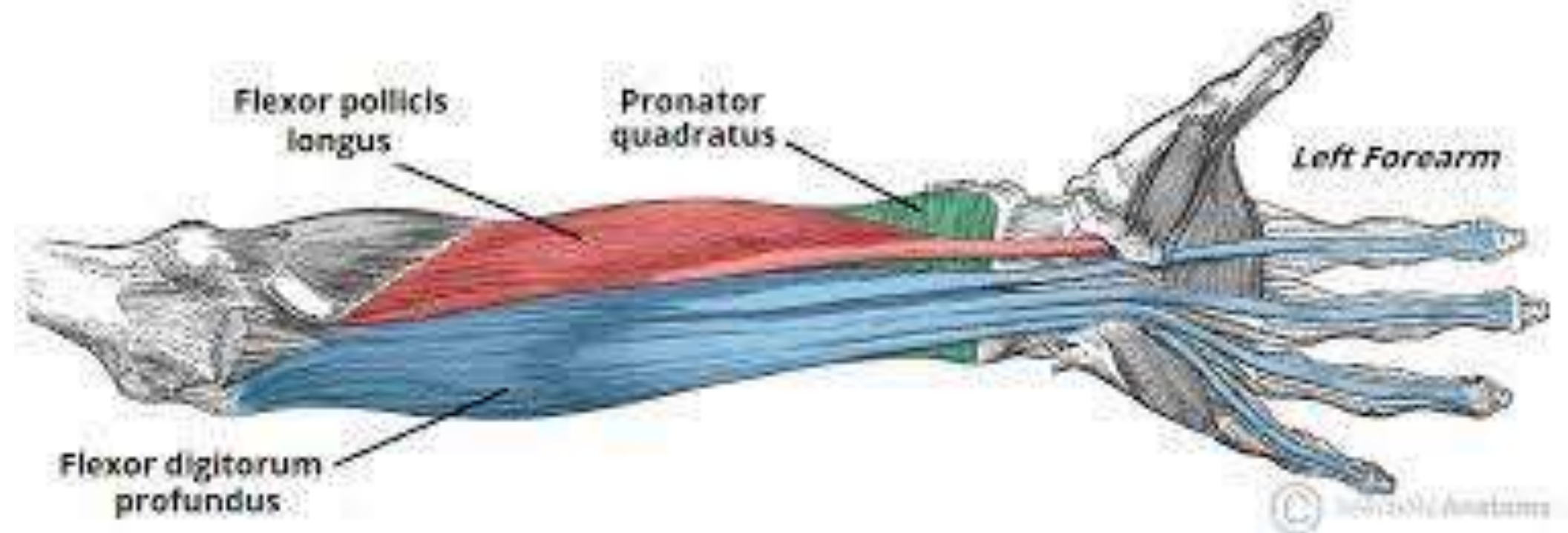
The four tendons of FDS pass deep to flexor retinaculum enclosed within a common synovial sheath, the ulnar bursa



Deep muscles of Forearm

Three deep muscles

1. Flexor pollicis longus (placed laterally).
2. Flexor digitorum profundus (placed medially).
3. Pronator quadratus (placed distally)





Flexor pollicis longus



Covers the anterior aspect of the radius distal to the attachment of supinator muscle.

Origin

- Upper two-third of the anterior surface of the radius
(below the anterior oblique line)
- Adjoining part of the interosseous membrane.



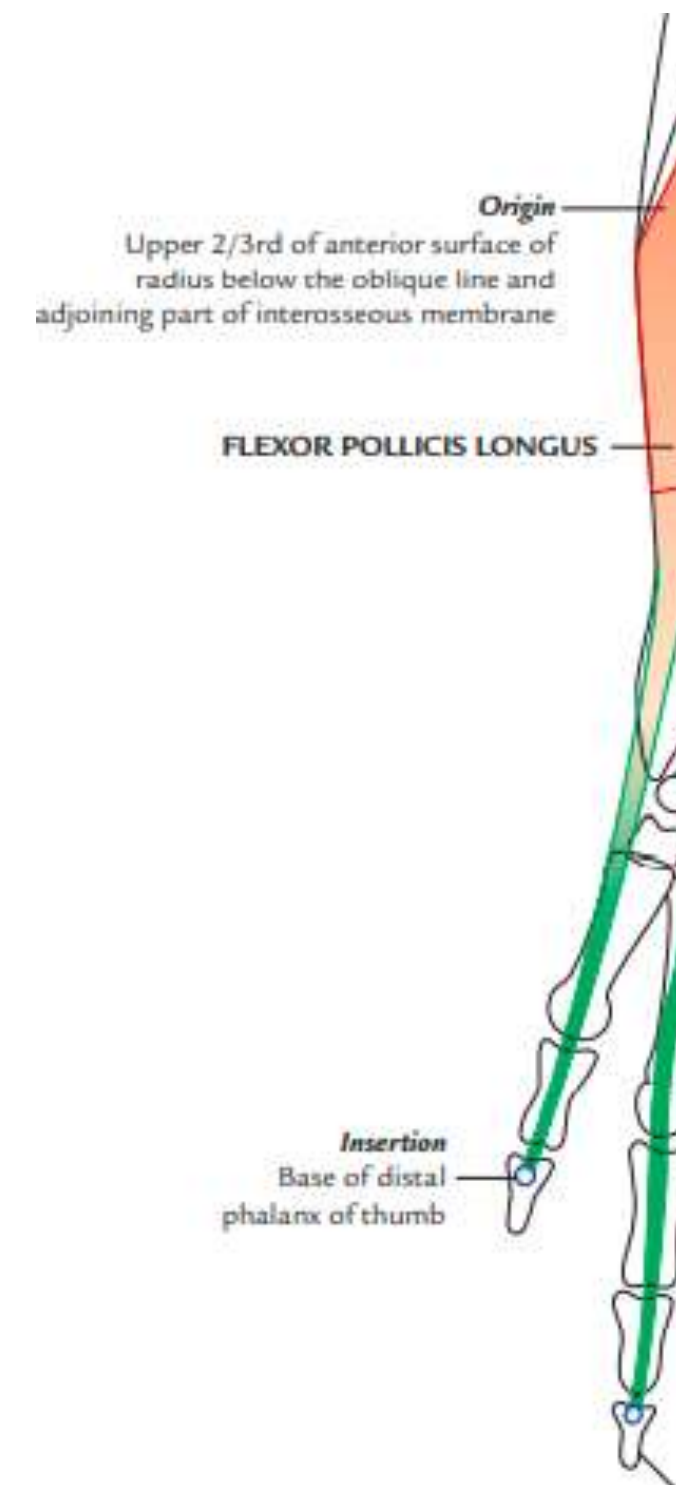
Flexor pollicis longus

Insertion

Anterior surface of the base of distal phalanx of the thumb.

Nerve supply:

Median nerve (anterior interosseous branch)



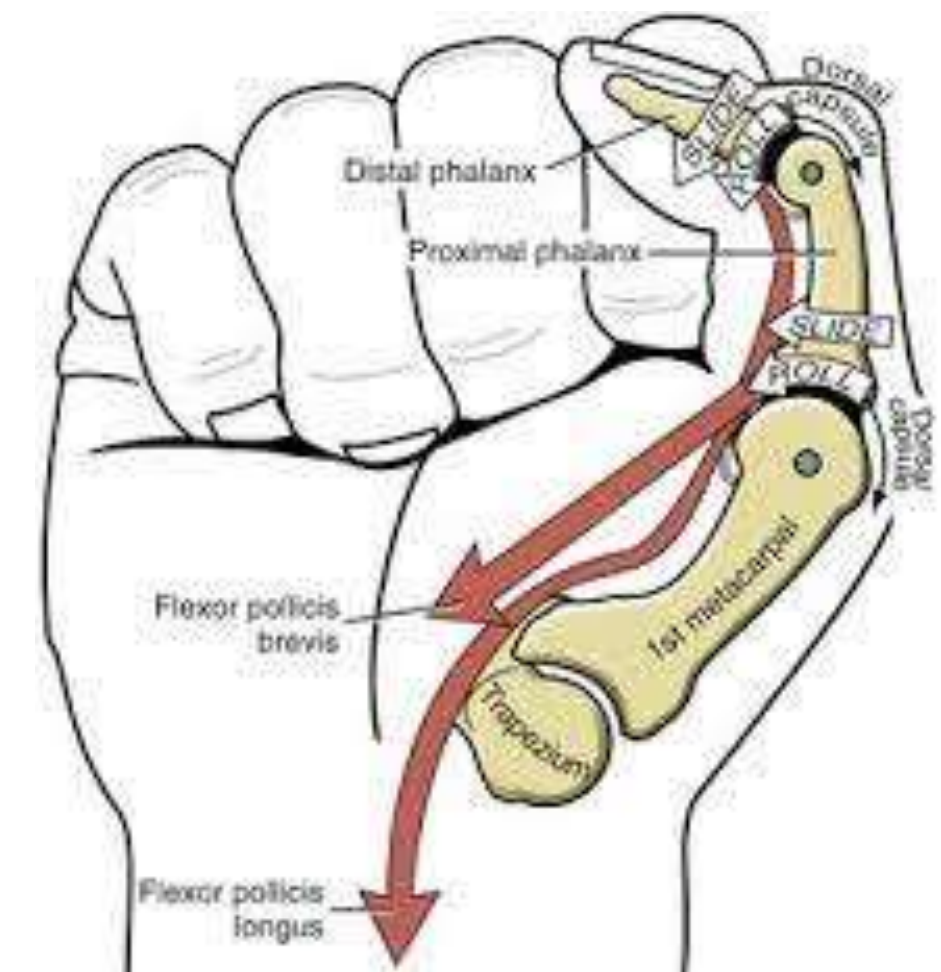
Flexor pollicis longus

Actions

Primarily flexes the distal phalanx of the thumb

Secondarily flexes →

- proximal phalanx
- first metacarpal at the metacarpophalangeal (MP)
- carpometacarpal (CM) joints



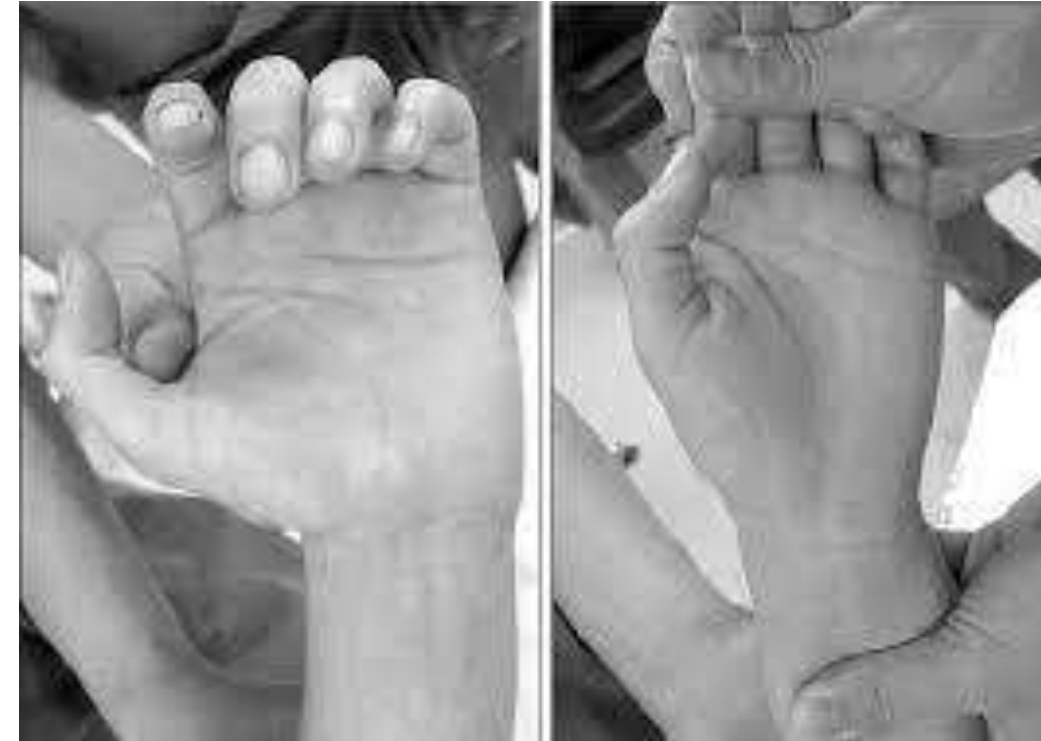

Flexor pollicis longus – Clinical testing



Asking the patient to flex the

- Interphalangeal joint of the thumb,
- While proximal phalanx of the thumb is held in extension





Flexor Digitorum Profundus



Most bulky and powerful muscle
Provides main gripping power to the hand.

Origin

1. Upper three-fourth of the anterior and medial surfaces of the shaft of ulna
2. From the medial side of olecranon and coronoid process of ulna.





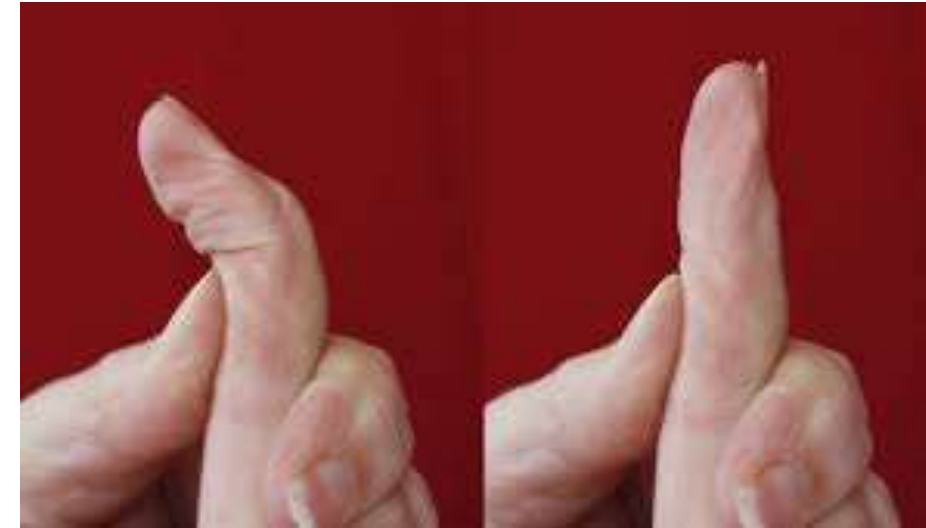
Flexor Digitorum Profundus



Insertion

the palmar aspect -bases of **distal phalanges** -
medial four digits.

Opposite the proximal phalanx → the tendon perforates the tendon of flexor digitorum superficialis and passes forward to be **inserted in palmar surface of the distal phalanx.**





Flexor Digitorum Profundus



Nerve supply

Medial half → ulnar nerve.

Lateral half → anterior interosseous nerve
(branch of the median nerve)

Actions

- Flexion → Medial four digits distal interphalangeal (DIP) joints of.
- Helps to flex the wrist joint.



Clinical testing



Ask the patient to flex the DIP joint, while holding the PIP joint in extension.

Intactness:

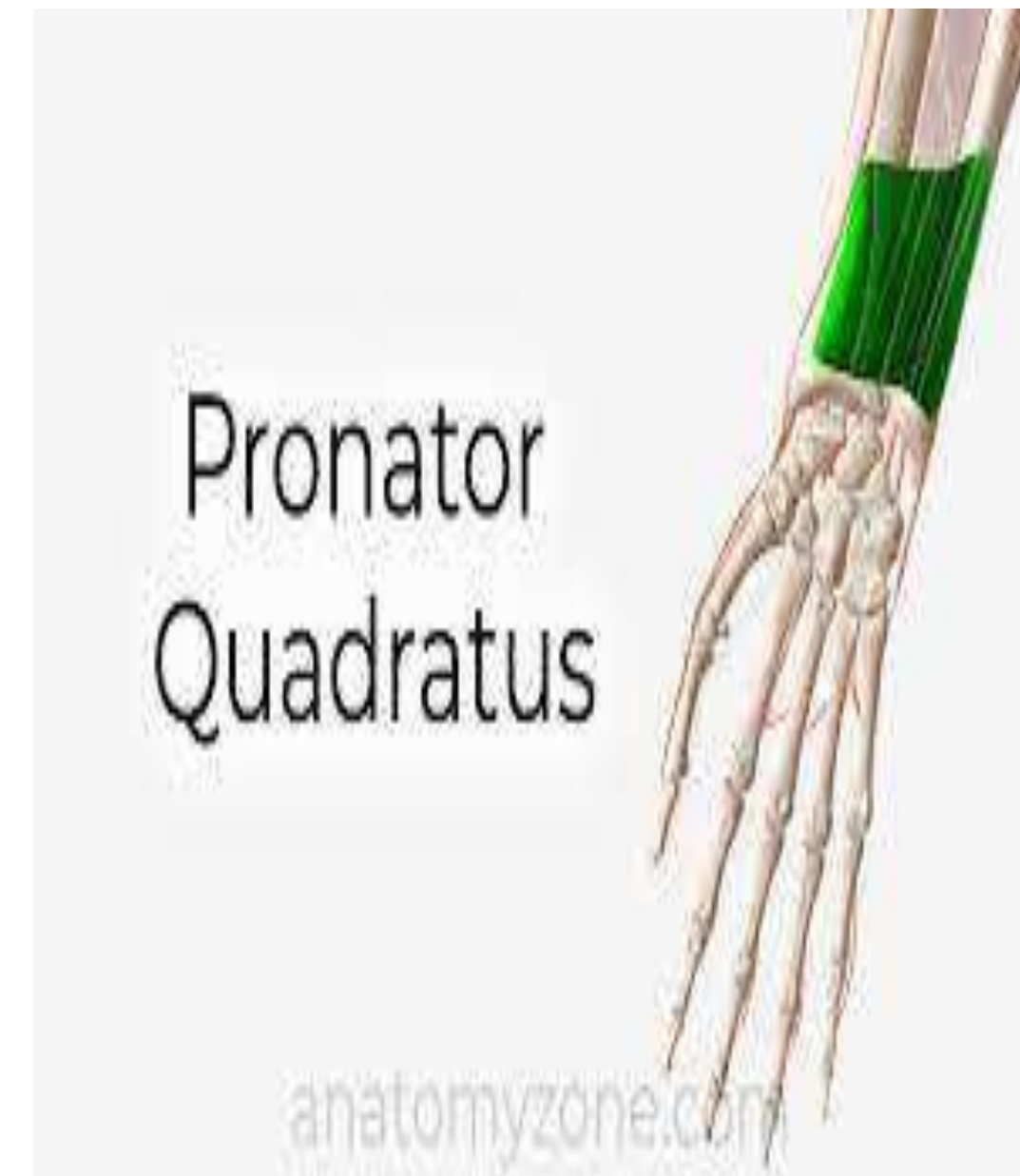- Median nerve in forearm is tested in this way by using index finger
- Ulnar nerve by using little finger



Pronator Quadratus



- Flat quadrilateral muscle
- Extends across the front of the distal parts of the radius and ulna
- **Origin**
Oblique ridge → lower one-fourth of the anterior surface of the **shaft of ulna** (also medial part of this surface)





Insertion

Superficial fibres → distal one-fourth of the anterior border & anterior surface of the shaft of radius.

Deeper fibres → triangular area above the ulnar notch of the radius.

Nerve supply : Anterior interosseous nerve.
(median nerve)



Pronator Quadratus



Actions

- Chief pronator of the forearm
- Assisted by pronator teres (rapid and forceful pronation)

Arteries of front of arm

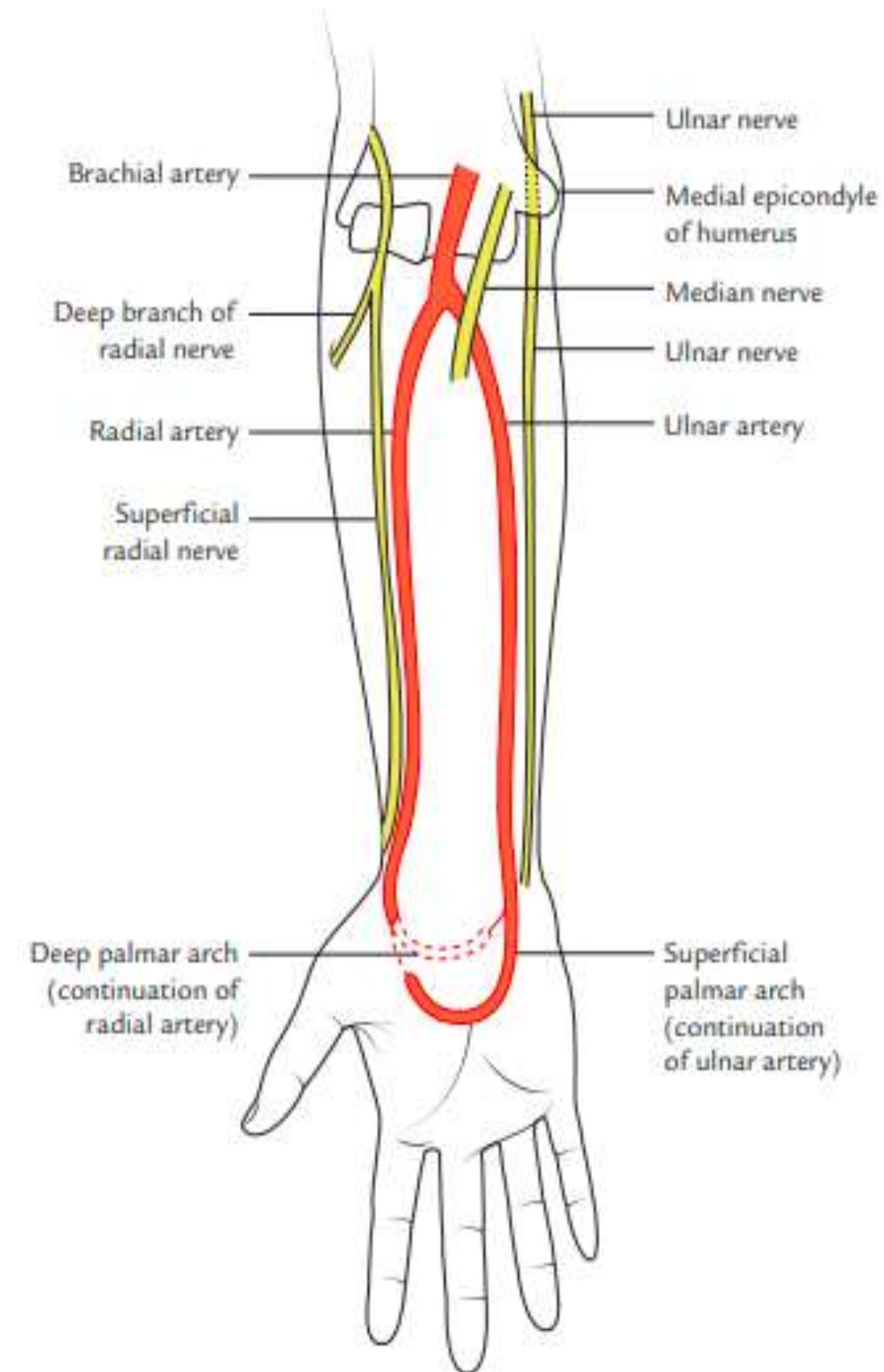
Ulnar and Radial arteries.

Supply blood to the hand :-

- superficial palmar arterial arches.
- deep palmar arterial arches.

Supply to the forearm :-

- Anterior interosseous arteries
- Posterior interosseous arteries

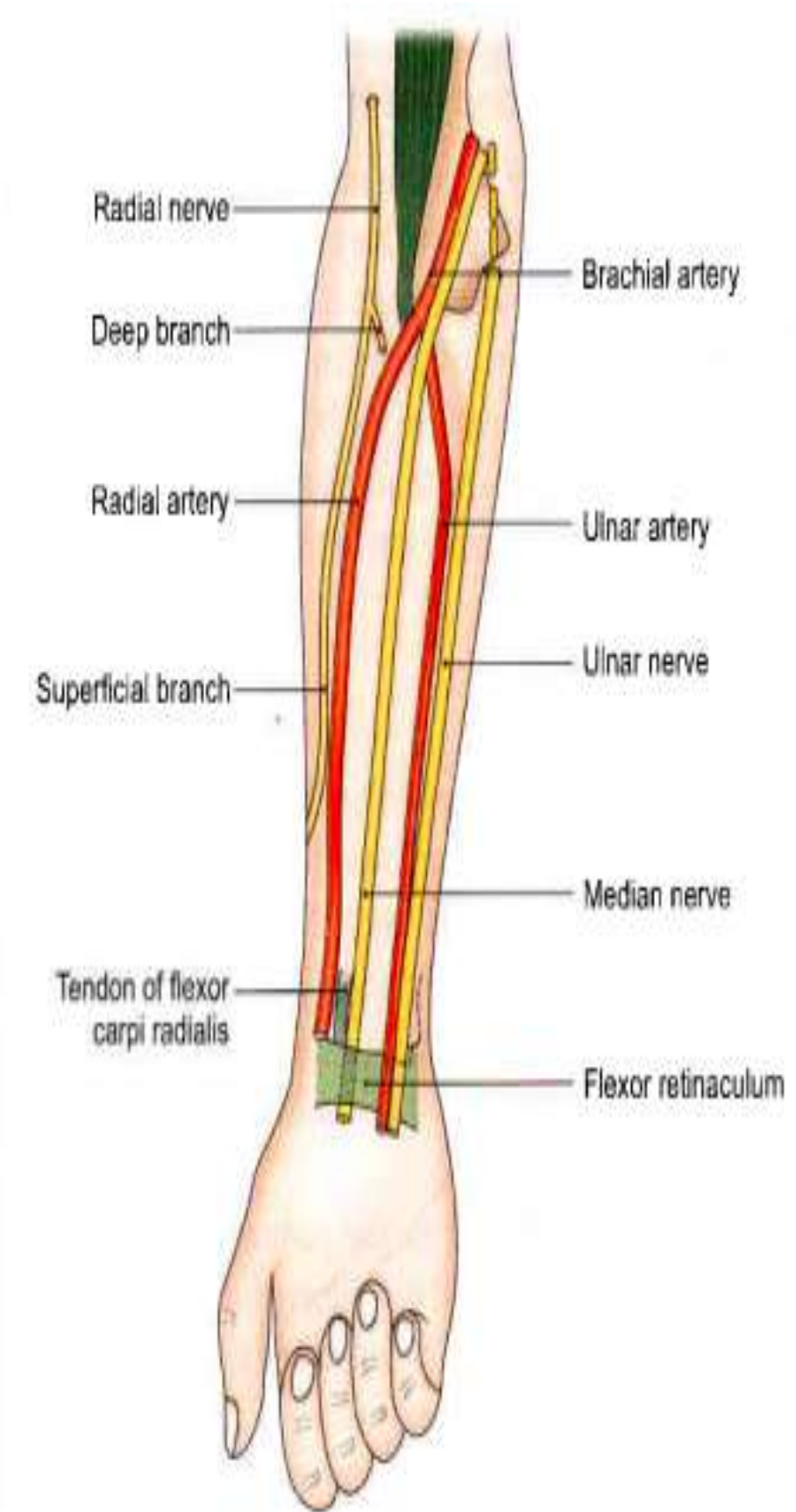




Ulnar Artery

Course

- Begins in the cubital fossa at the level of the neck of the radius
- Artery runs obliquely downwards and medially → upper one-third of the forearm
- Lower two thirds of the forearm its course is vertical.
- Enters the palm by passing superficial to the flexor retinaculum.



Ulnar artery - Relations

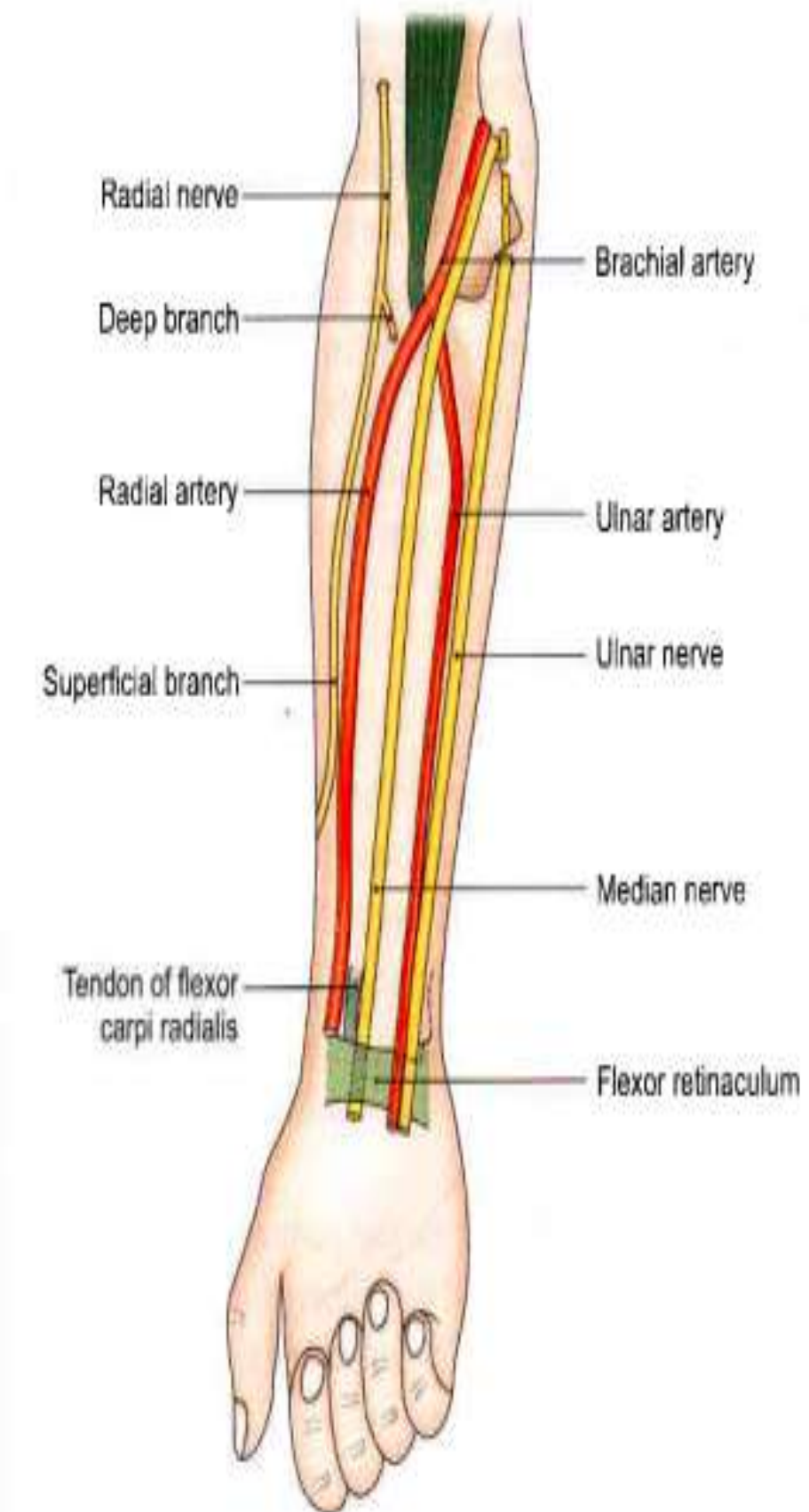
1. Anteriorly –

- In upper half the -covered by muscles (common flexor origin) and median nerve.
- In lower half of the artery - skin and fascia

2. Posteriorly - brachialis and on the flexor digitorum profundus.

3. Medially - ulnar nerve & flexor carpi ulnaris

4. Laterally - flexor digitorum superficialis





Ulnar Artery - Branches



1. **Muscular branches** to neighboring muscles.

2. **Anterior and posterior ulnar collateral (recurrent) arteries** (arterial anastomosis around the elbow joint)

3. **Common interosseous artery**,
 anterior and posterior interosseous arteries. 4.

- Anterior and posterior ulnar carpal branches,
formation of anterior and posterior carpal
arches.

5. Terminal branches
 - larger superficial branch -superficial palmar arch
 - smaller deep branch joins the deep palmar arch.

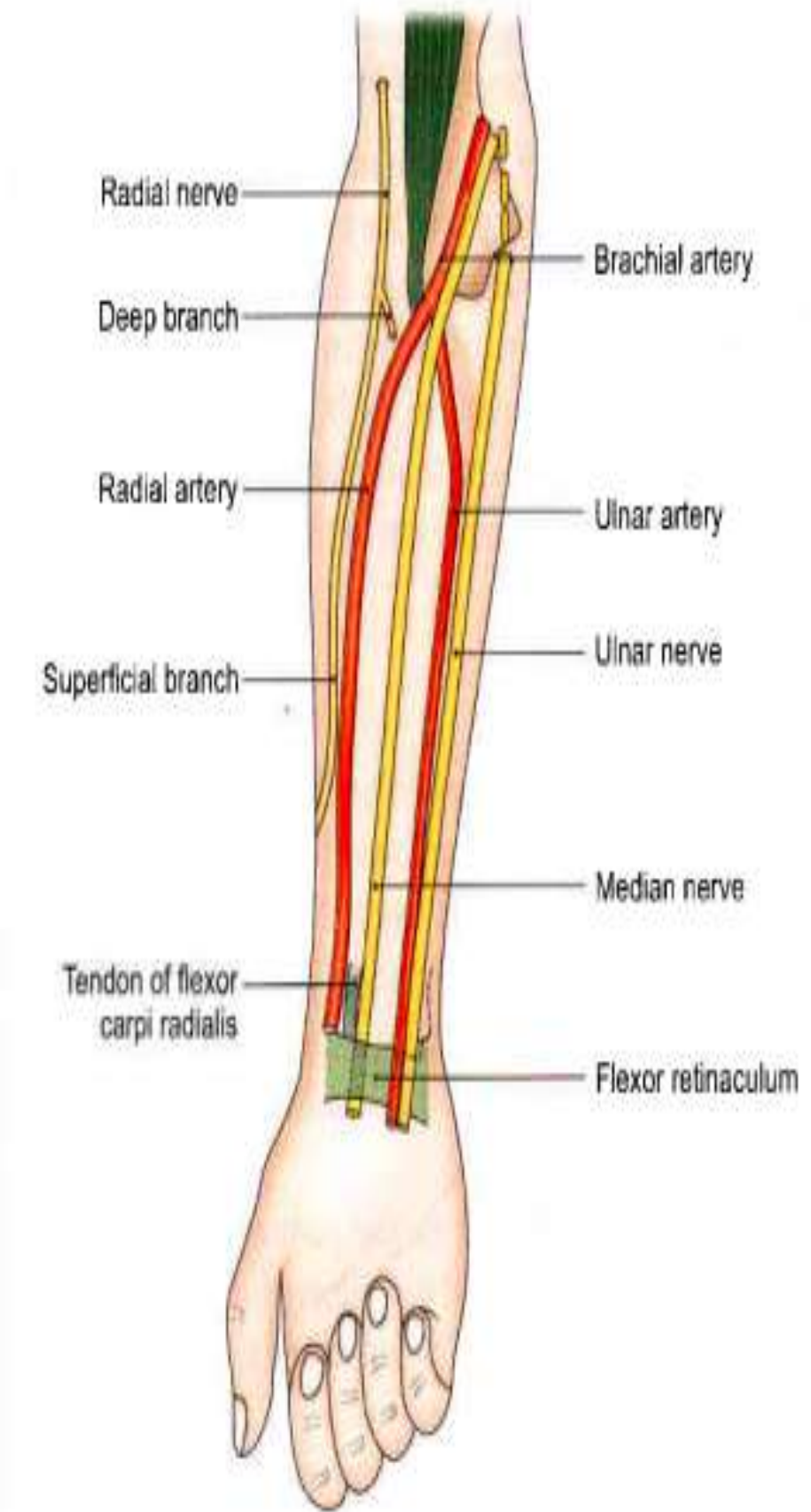
Radial artery

Smaller terminal branch of the brachial artery.

Begins in cubital fossa at the level of the neck of radius.

Course:

- Passes downwards to the wrist with lateral convexity.
- Upper part - beneath the brachioradialis
- Distal part of the forearm, lies on anterior surface of the radius and covered only by the skin and fascia.
- Leaves the forearm - winding around the lateral wrist reaching the anatomical snuff-box





Radial Artery - Relations



1. Anteriorly:

- upper part - Brachioradialis,
- lower - skin, superficial and deep fasciae.

2. Posteriorly:

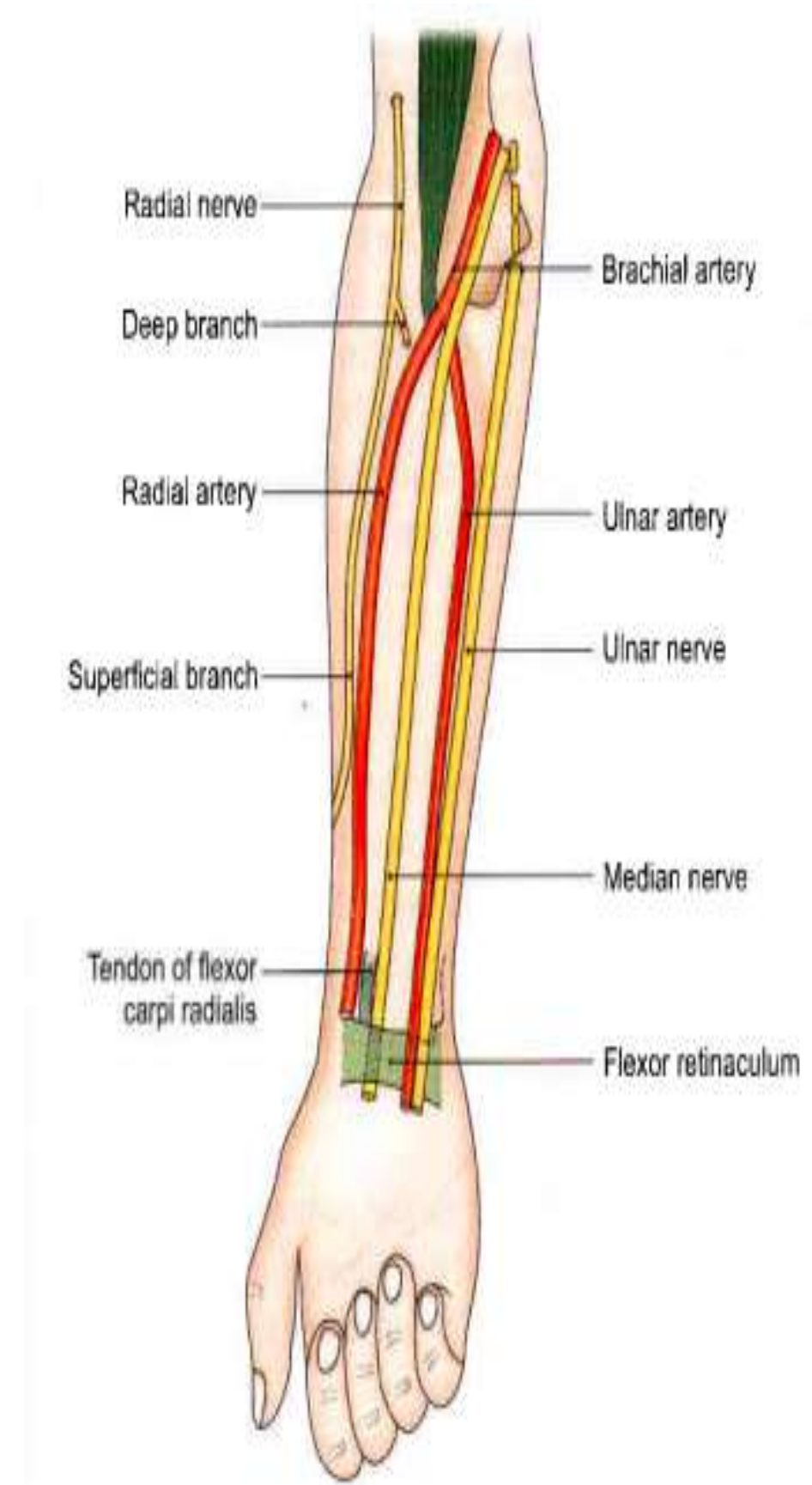
Biceps brachii, flexor pollicis longus, flexor digitorum superficialis and pronator quadratus.

3. Medially:

- Pronator teres -upper one-third
- Tendon of the flexor carpi radialis - lower two-thirds
- **Laterally:** Brachioradialis in the whole extent and the radial nerve in the middle one-third

Radial artery

1. **Muscular branches** -lateral muscles of the forearm.
2. **Radial recurrent artery**
Arterial anastomose around the elbow joint
3. **Palmar carpal branch,**
Anastomosis with the palmar carpal branch of the ulnar artery.
4. **Superficial palmar branch**
 - Enters the palm of the hand by passing in front of the flexor retinaculum.
 - Joins the terminal part of the ulnar artery to complete the superficial palmar arch





Muscles of back of forearm



Contents

Muscles

Posterior interosseous nerve

Anterior and posterior interosseous arteries



Muscles of forearm



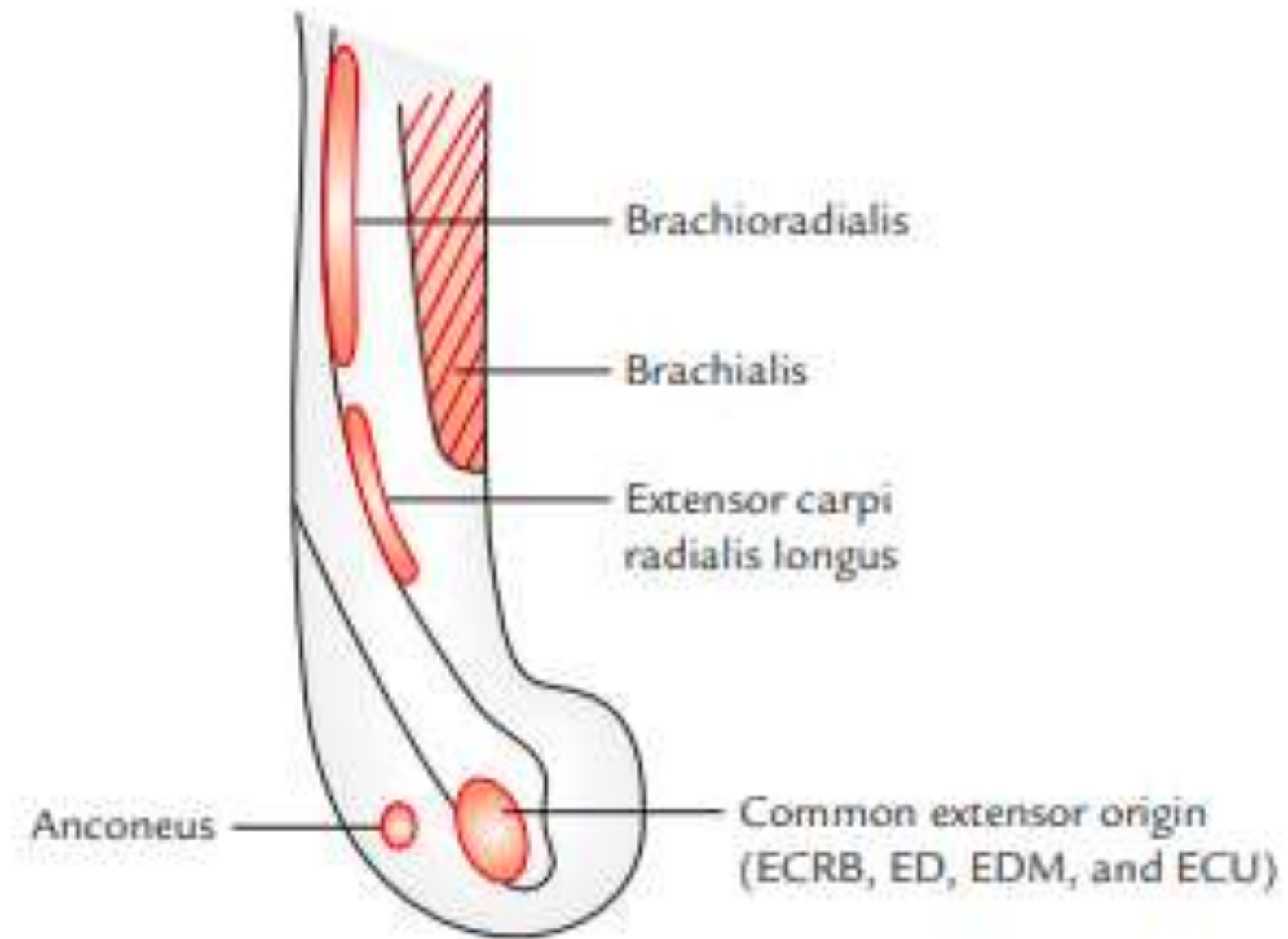
SUPERFICIAL MUSCLES:

- Brachioradialis
- Extensor Carpi radialis longus
- Extensor carpi radialis brevis
- Extensor digitorum
- Extensor digiti minimi
- Extensor carpi ulnaris
- Anconeus

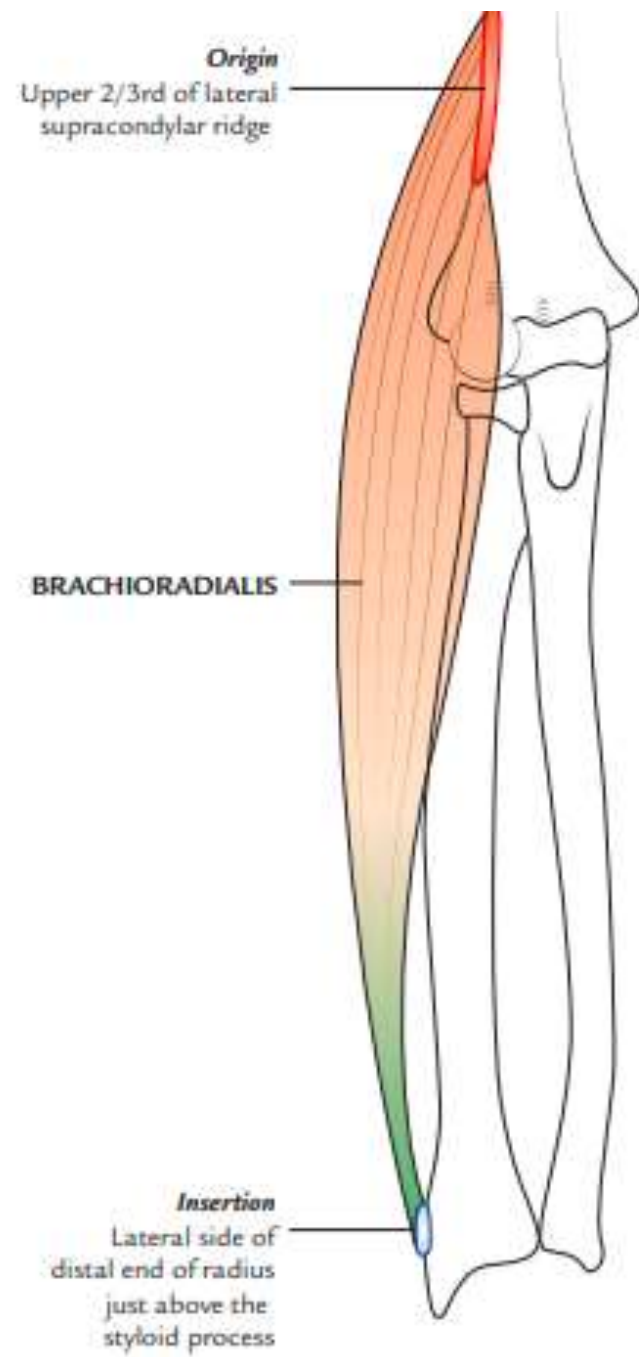
DEEP MUSCLES:

- **Supinator**
- Abductor pollicis longus (APL).
- Extensor pollicis brevis (EPB)
- Extensor pollicis longus (EPL)
- Extensor indicis

Common extensor origin



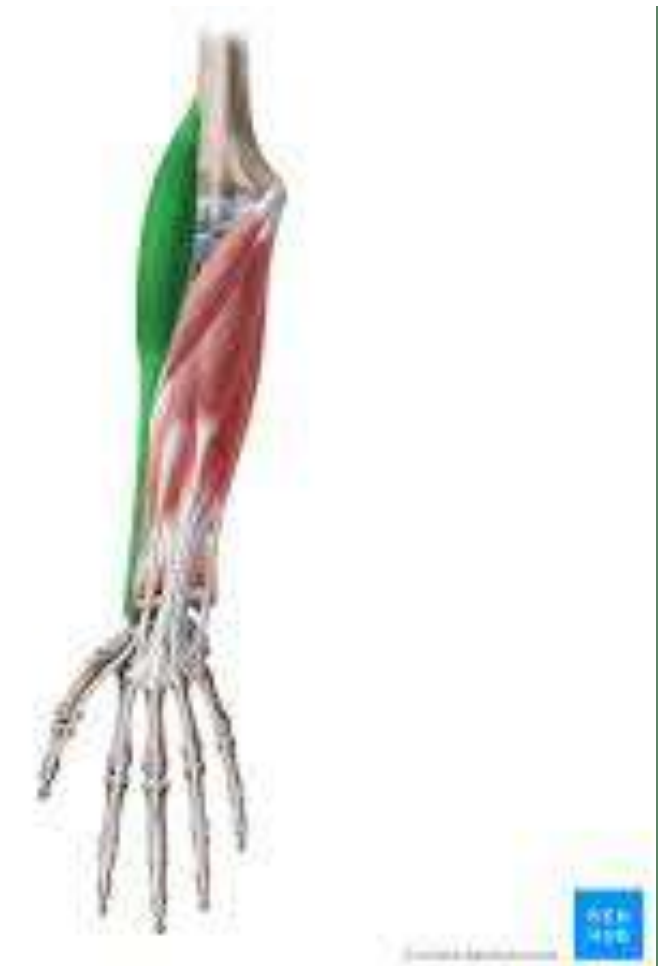Brachioradialis



Origin: Upper two-third of the lateral supracondylar ridge of the humerus

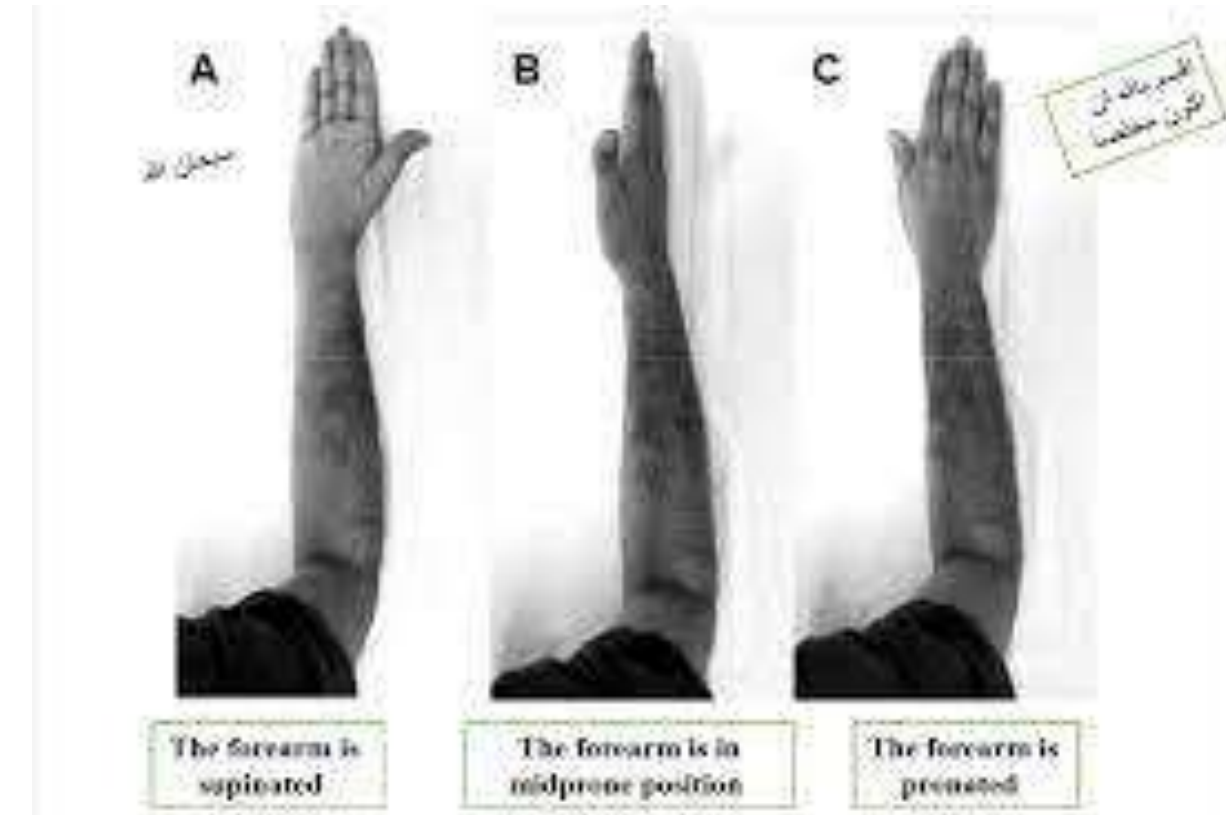
Insertion : Lateral surface of the distal end of radius just above the styloid process

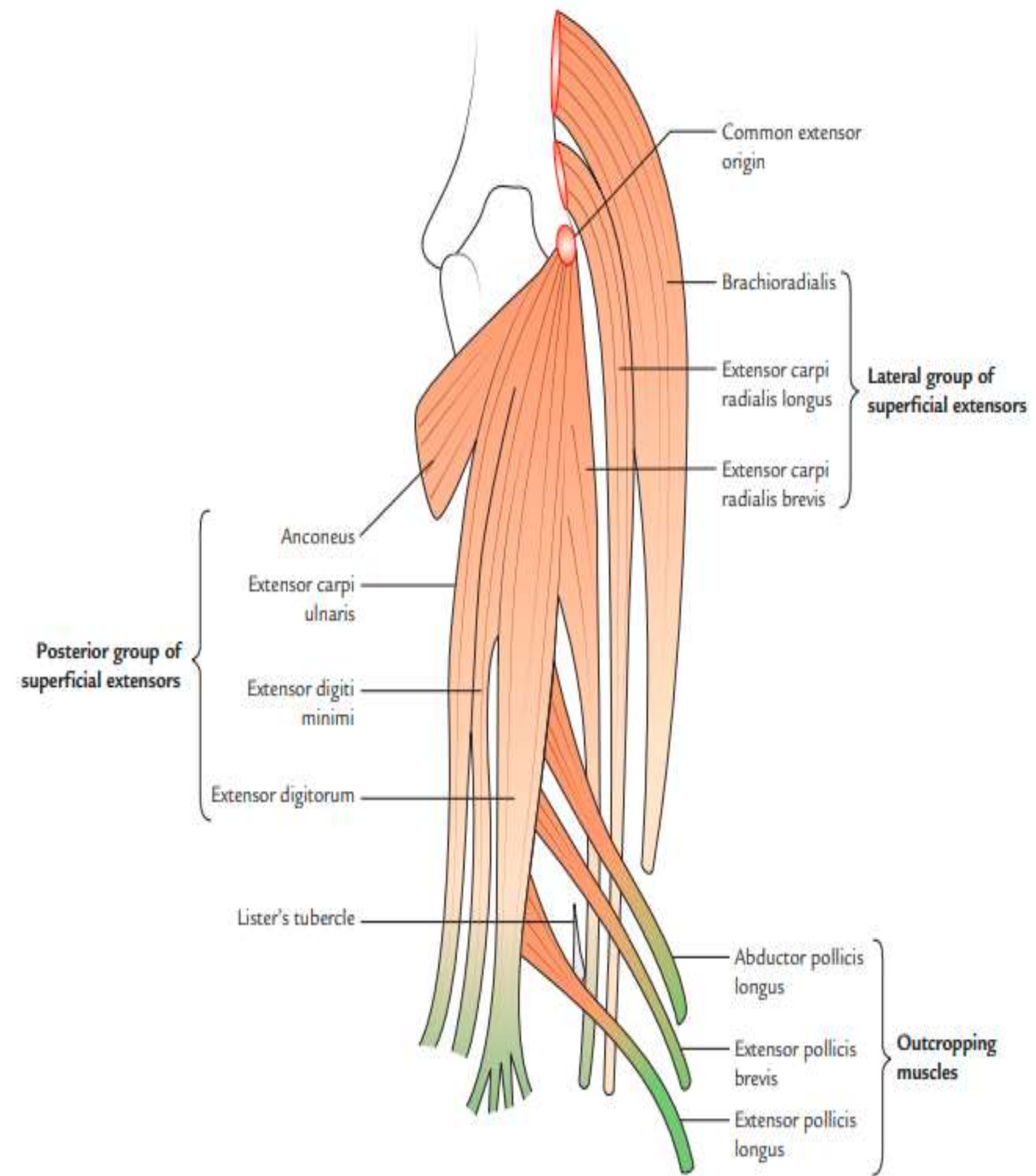
Nerve: Radial nerve



Actions

- Flexes the elbow joint.
- Pronates the supinated forearm to **midprone position**
- Supinates the pronated forearm to **midprone position**







Extensor carpi radialis longus (ECRL)



Origin :

Lower one-third of the lateral supracondylar ridge of the humerus

Insertion :

Lateral side of the dorsal surface of the base of second metacarpal bone

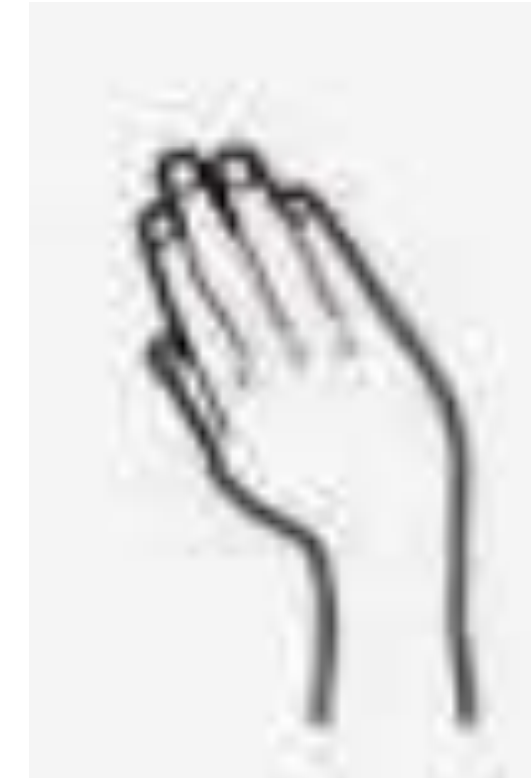



Nerve supply :Radial nerve

Actions :

- Acting with extensor carpi ulnaris extends the wrist
- Acting with flexor carpi radialis abducts the wrist





Extensor digitorum



Origin :

By a common tendon from the lateral epicondyle

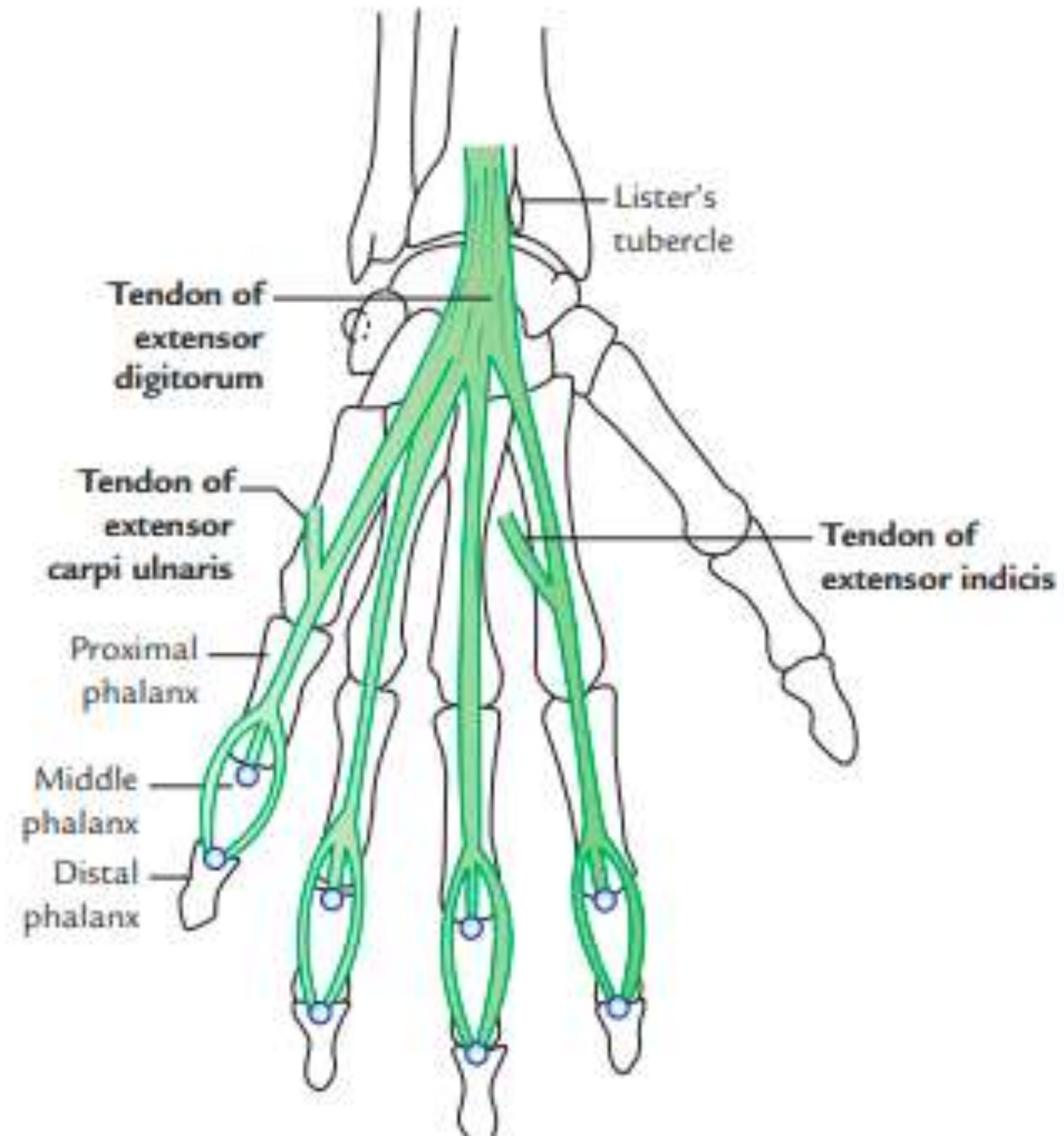
Insertion :

- Gives rise to four tendons for medial four digits.
- By the extensor expansion it is inserted into the **dorsum of middle and terminal phalanges**

Nerve supply :Posterior interosseous nerve

Action : Extends the medial four digits.
Can also extend the wrist







Extensor digiti minimi



Origin :

By the common tendon from the lateral epicondyle

Insertion:

- Lies medial to the extensor digitorum tendon for the little finger.
- Through the extensor expansion, it is inserted into the dorsum of middle and terminal phalanges of little finger

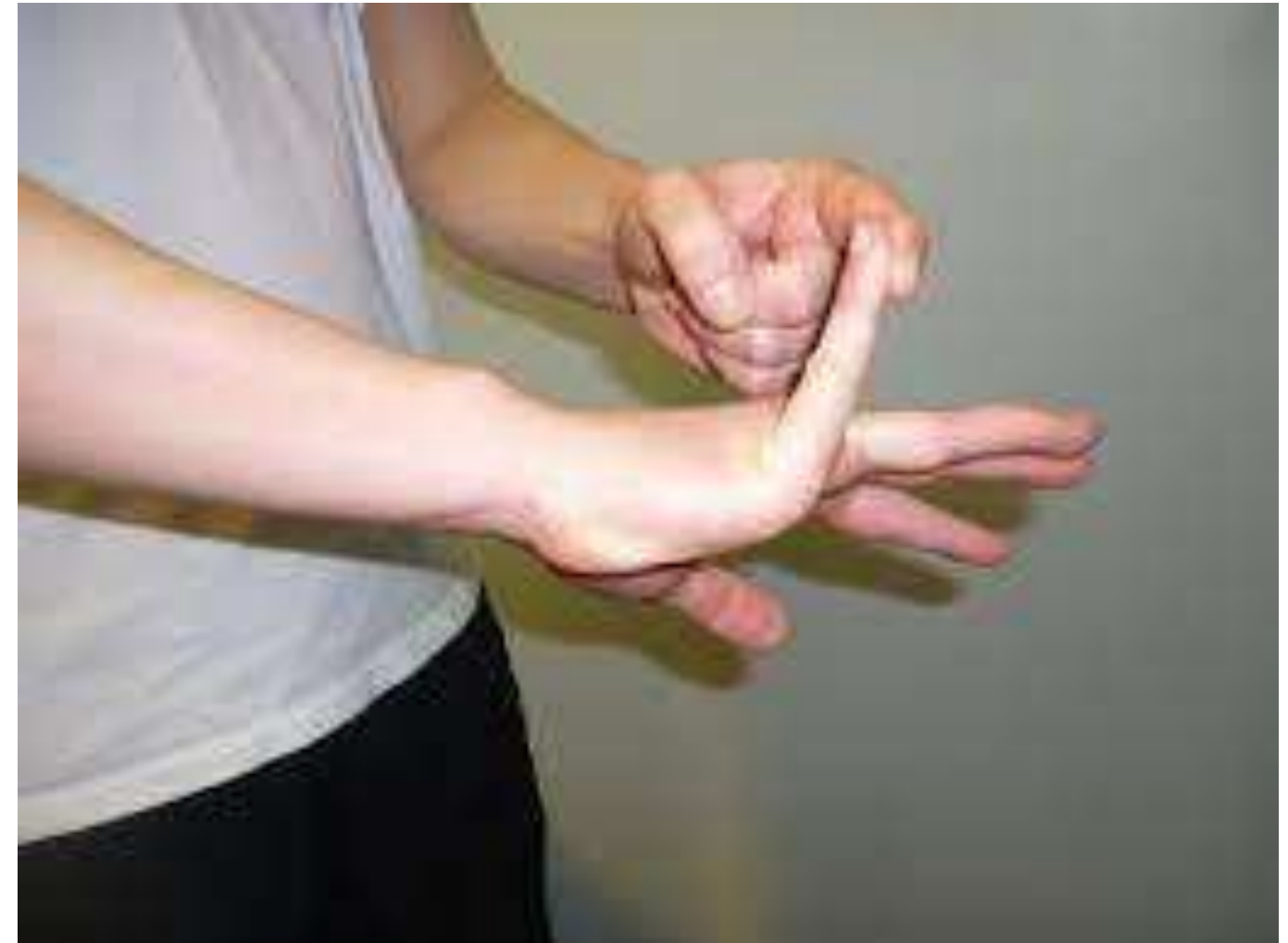

NERVE SUPPLY

Posterior interosseous nerve

ACTIONS

- Extends the little finger
- Helps in the extension of the wrist





Extensor carpi ulnaris (ECU)



Origin :

By the common tendon from the lateral epicondyle and by an aponeurosis from the upper two-third of the posterior border of ulna

Insertion :

Into a tubercle on the medial side of the dorsal surface of the base of the fifth metacarpal



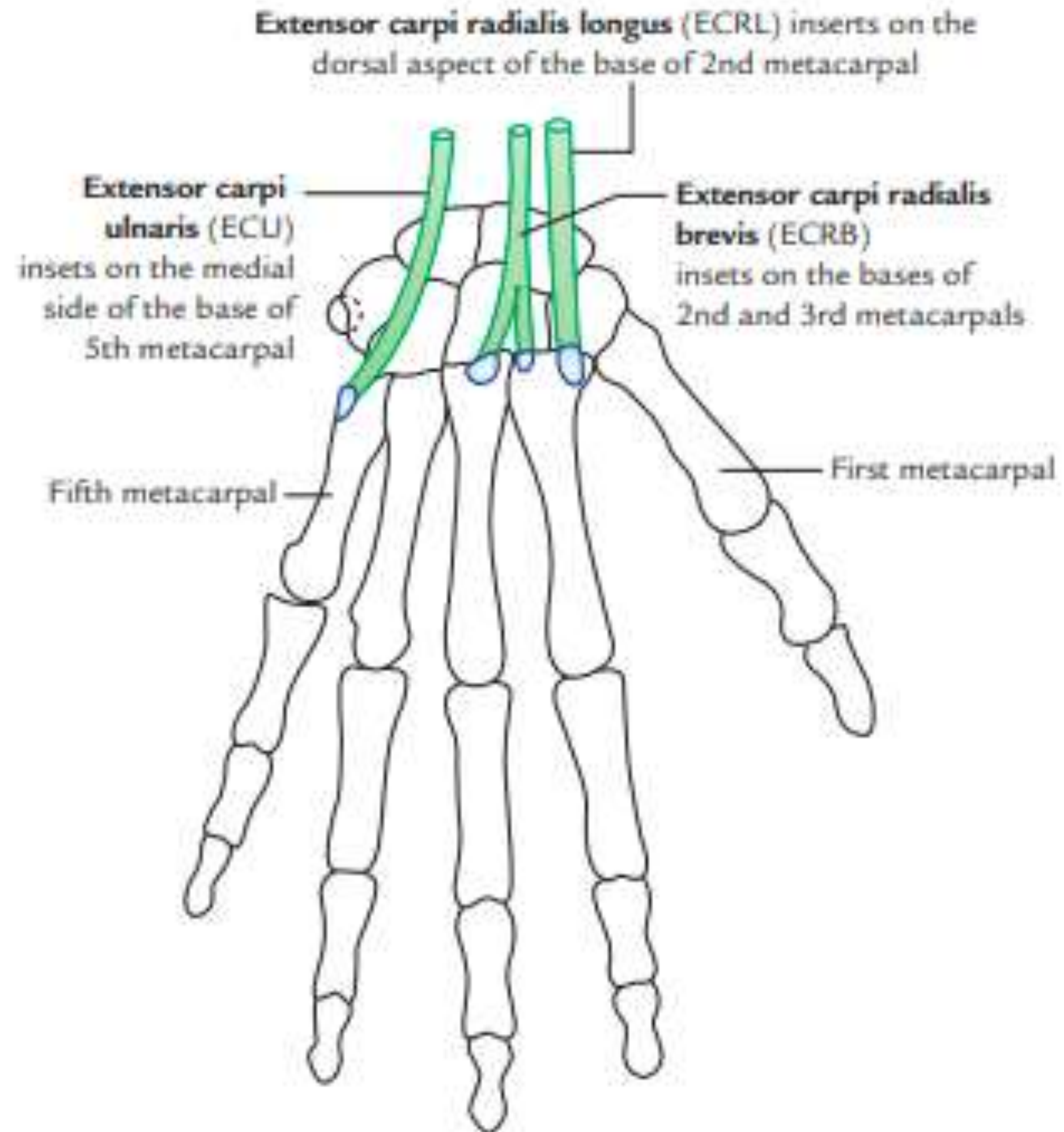
NERVE SUPPLY

Posterior interosseous nerve

ACTIONS

- Acting with extensor carpi radialis it extends the wrist
- Acting with flexor carpi ulnaris it adducts the wrist







Extensor carpi radialis brevis

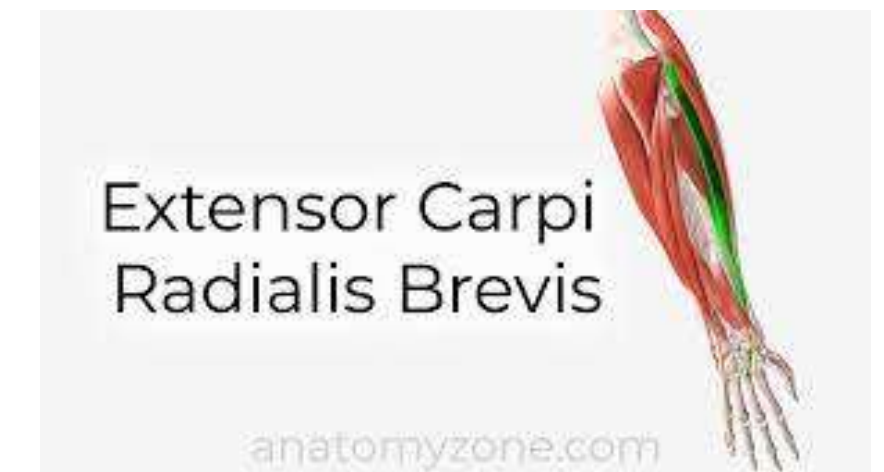

Origin :

By a common tendon from the lateral epicondyle of the humerus and lateral ligament of the elbow joint

Insertion

Lateral side of the dorsal surface of the base of third metacarpal bone





- **Nerve supply :**

Posterior interosseous nerve before piercing the supinator

- **Actions :**

Extension of wrist

Abduction of wrist / Radial deviation

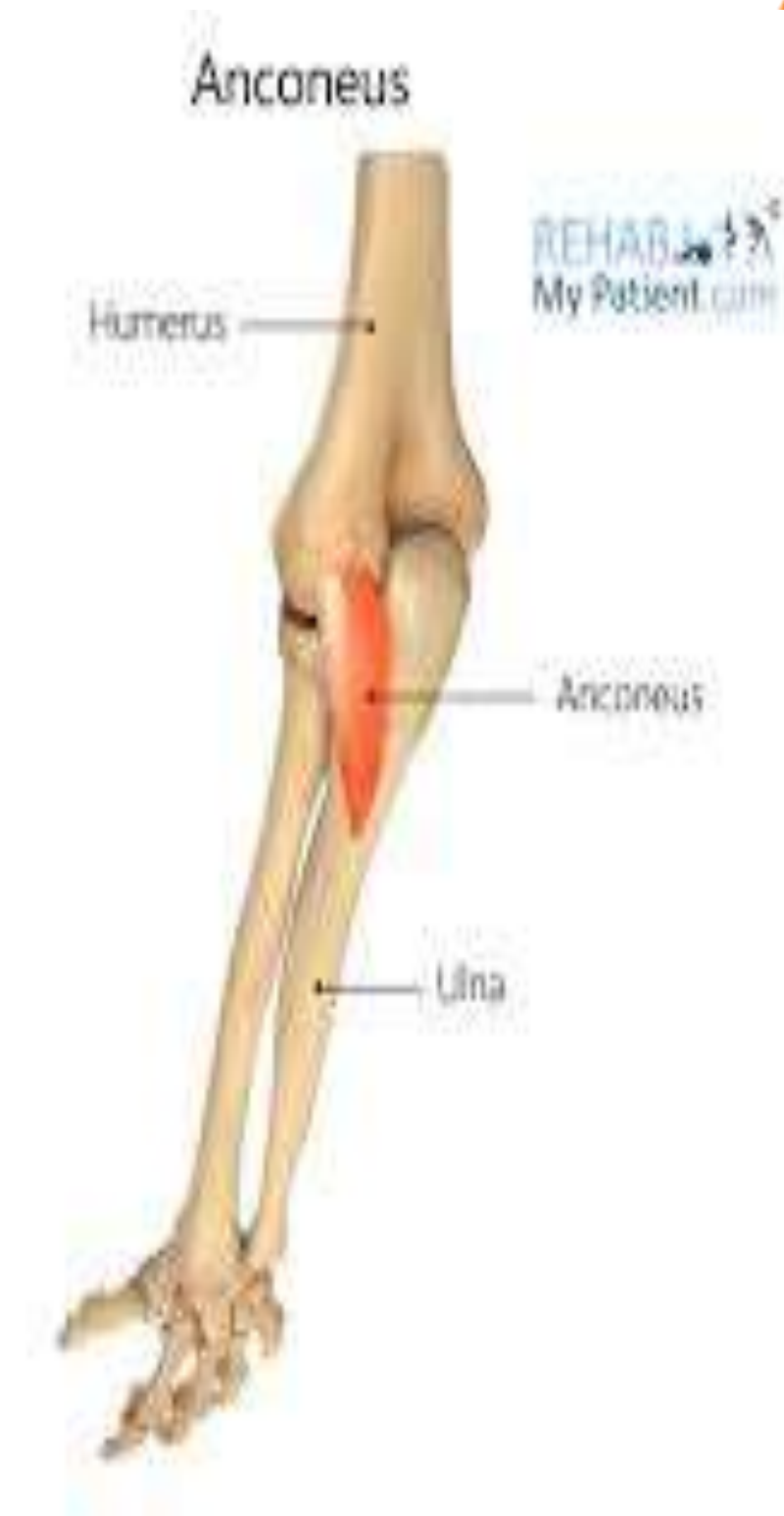Anconeus

Origin :

From the back of the lateral epicondyle

Insertion :

Lateral side of the olecranon process and upper one-fourth of the posterior surface of the ulna

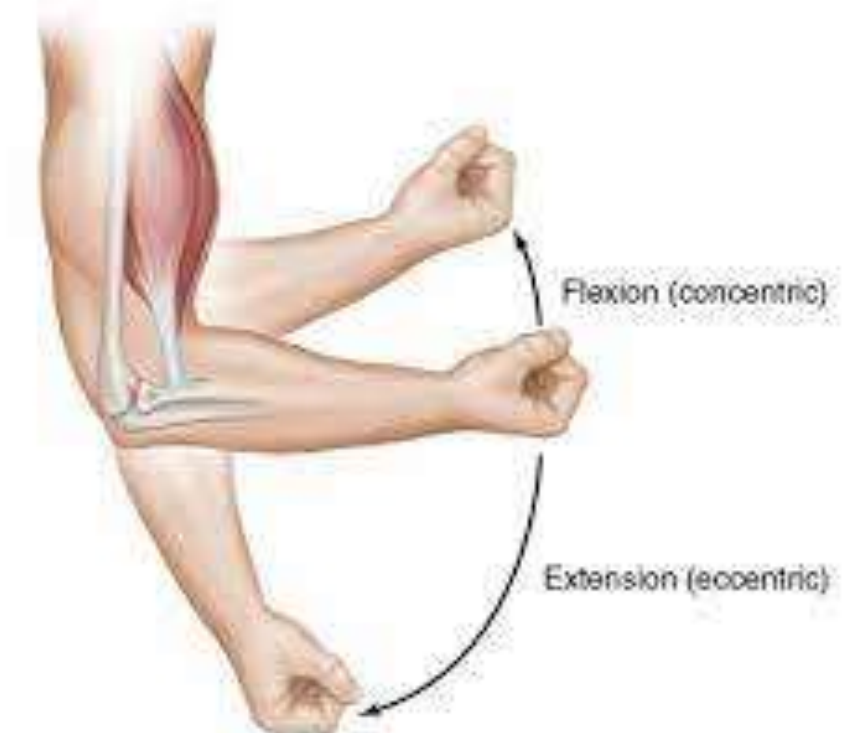

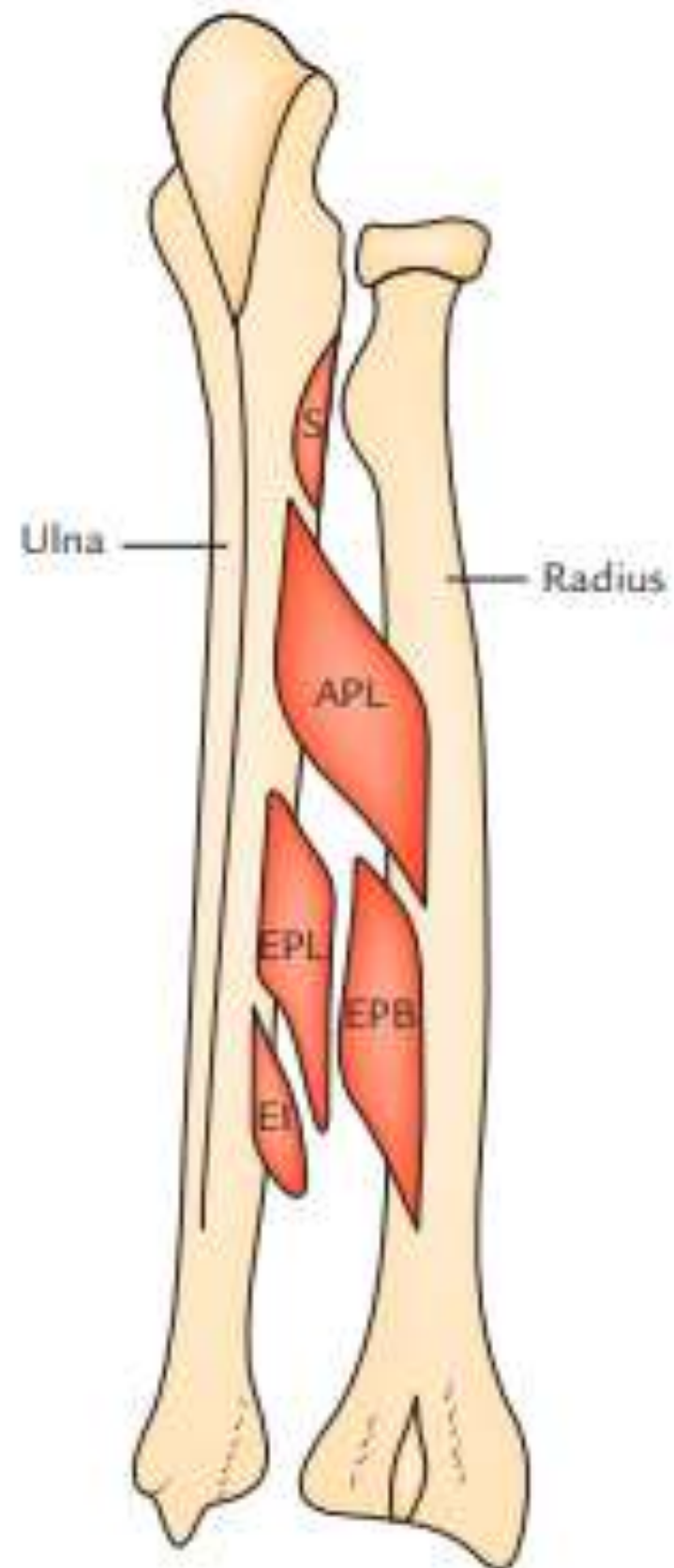
NERVE SUPPLY :

Nerve to anconeus, which arises from radial nerve in spiral groove

ACTIONS :

Weak extensor of the elbow joint





Deep muscles of back of forearm

Supinator

Origin

- Lateral epicondyle
- Lateral ligament of the elbow joint
- Annular ligament
- Supinator crest of ulna and from the triangular area in front of it

Insertion :

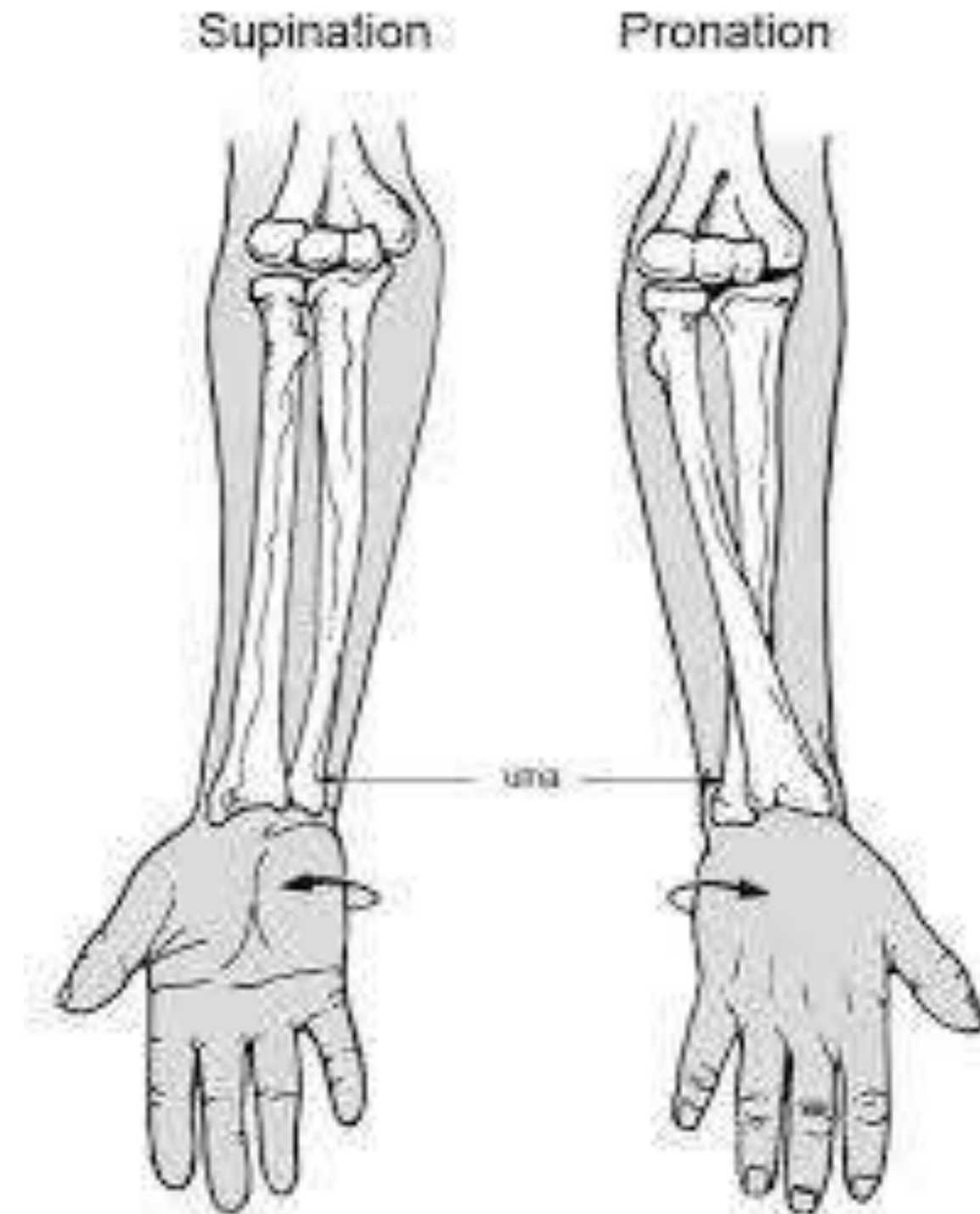
Upper one-third of the posterior, lateral, and anterior surfaces of the radius



Nerve supply: Posterior interosseous nerve before piercing the supinator

Actions:

Supination of the forearm in extended forearm



Abductor pollicis longus (APL)

Origin :

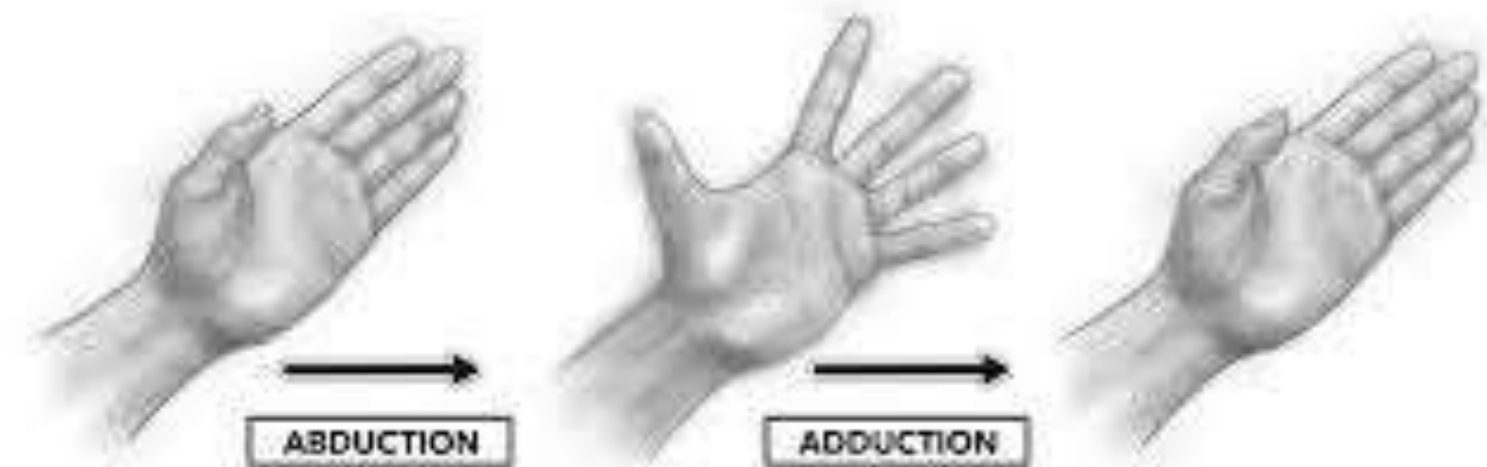- Lateral part of the posterior surface of ulna
- Middle one-third of the posterior surface of radius

Insertion : Lateral side of the base of first metacarpal



Nerve supply : Posterior interosseous nerve

Actions : Abducts the thumb





Extensor pollicis brevis (EPB)



Origin :

Small area on the posterior surface of radius

Insertion : Dorsal surface of the base of proximal phalanx of thumb

Nerve supply : Posterior interosseous nerve

Actions : Extends the thumb at metacarpophalangeal joint and extends the carpometacarpal joint



Extensor pollicis longus

Origin :

Lateral part of middle one-third of the posterior surface of ulna

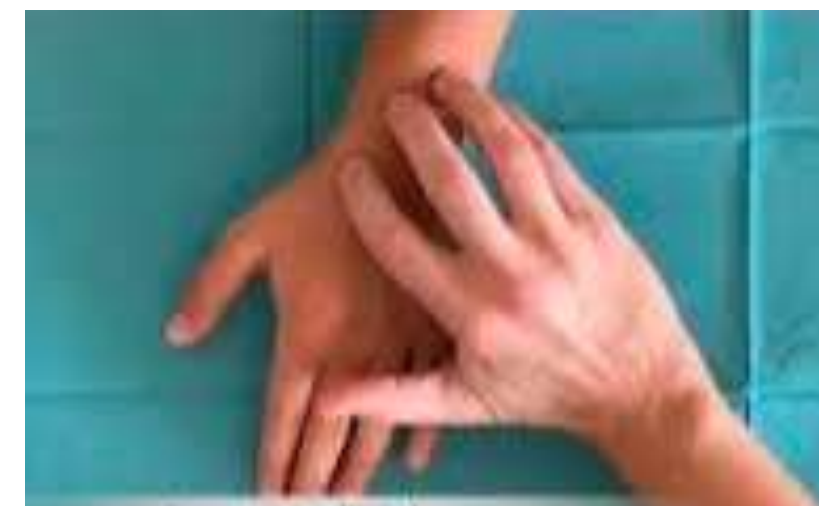Insertion :

Dorsal surface of the base of distal phalanx of thumb

Nerve supply : Posterior interosseous nerve

Actions :

- Extends the joints of thumb
- Helps in the extension of the wrist





Extensor indicis

Origin : Posterior surface of ulna below the origin of extensor pollicis longus

Insertion : Dorsum of middle and distal phalanges of the index finger



Nerve supply : Posterior interosseous nerve

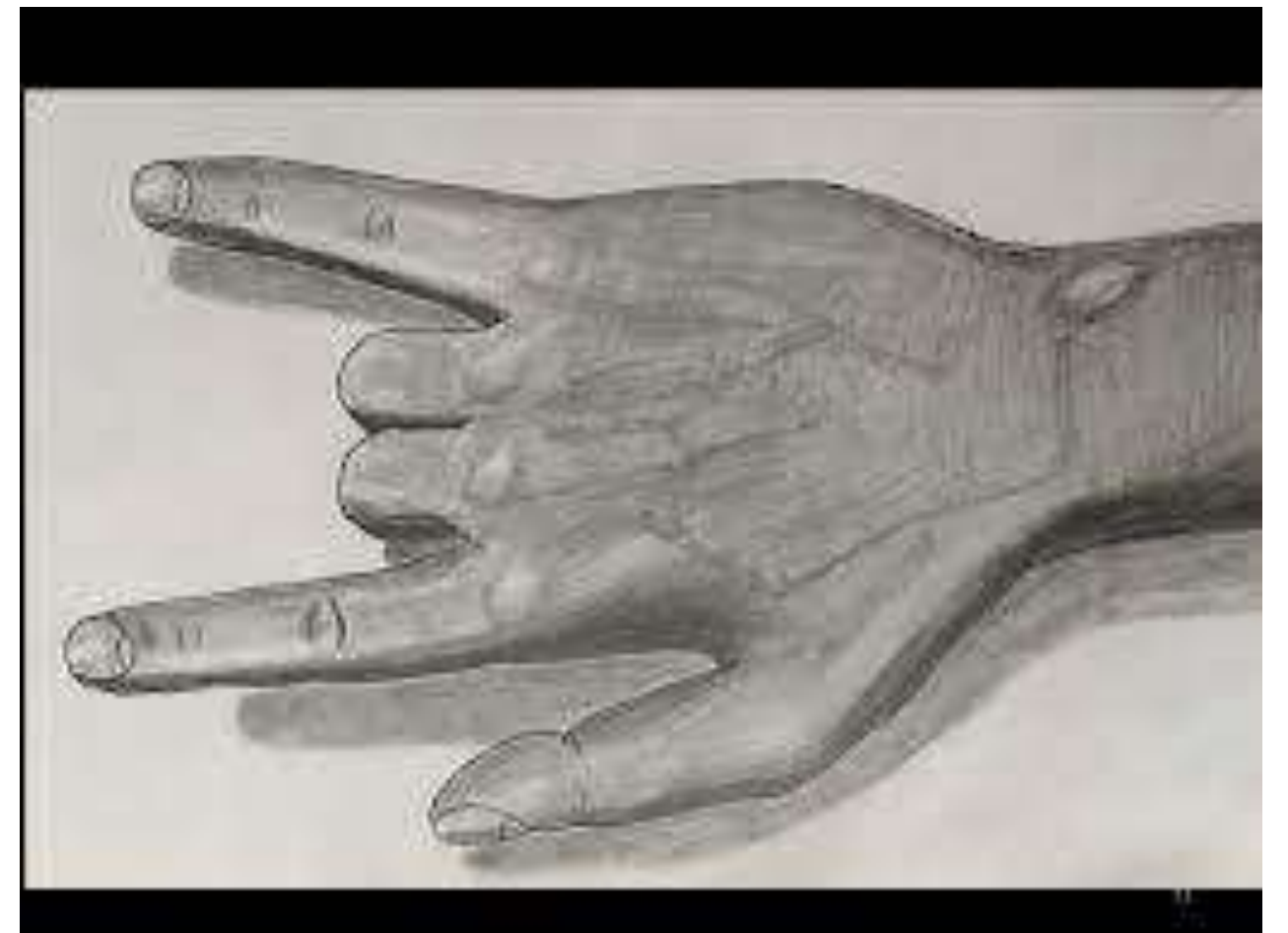

Actions :

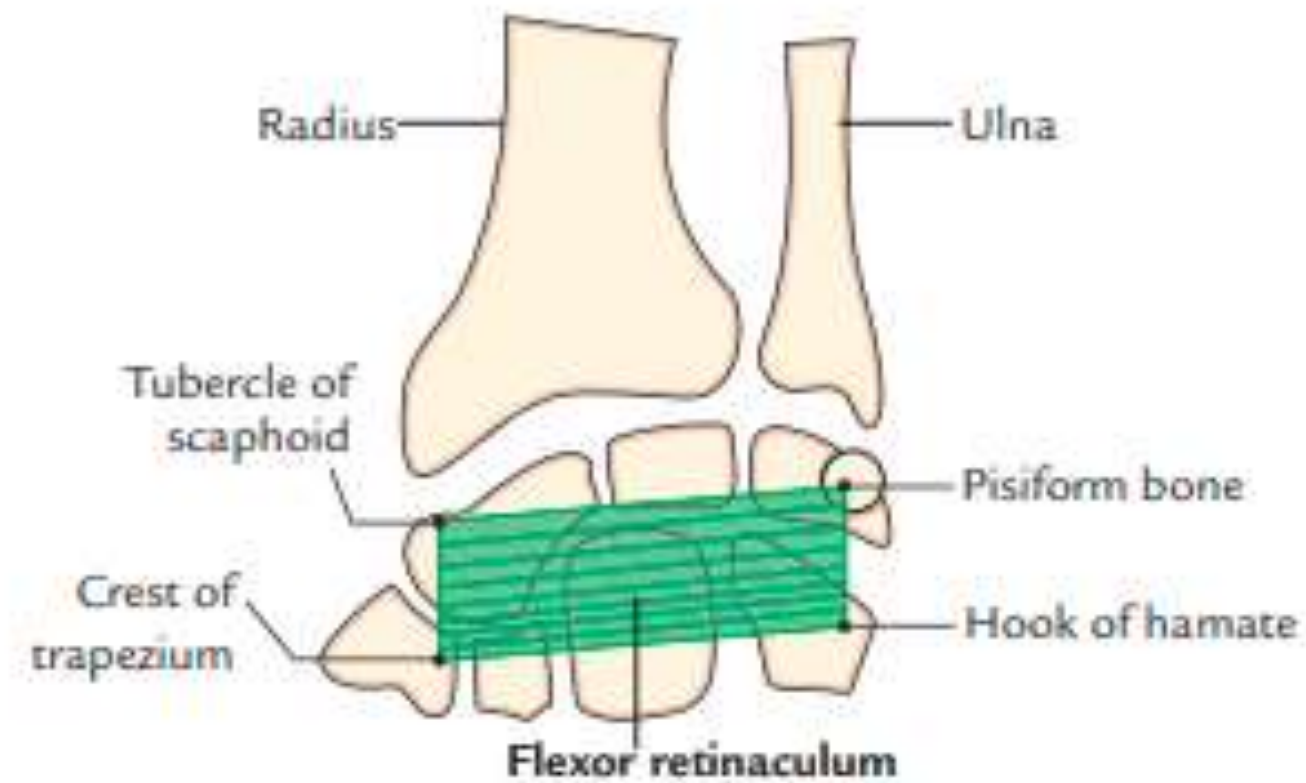
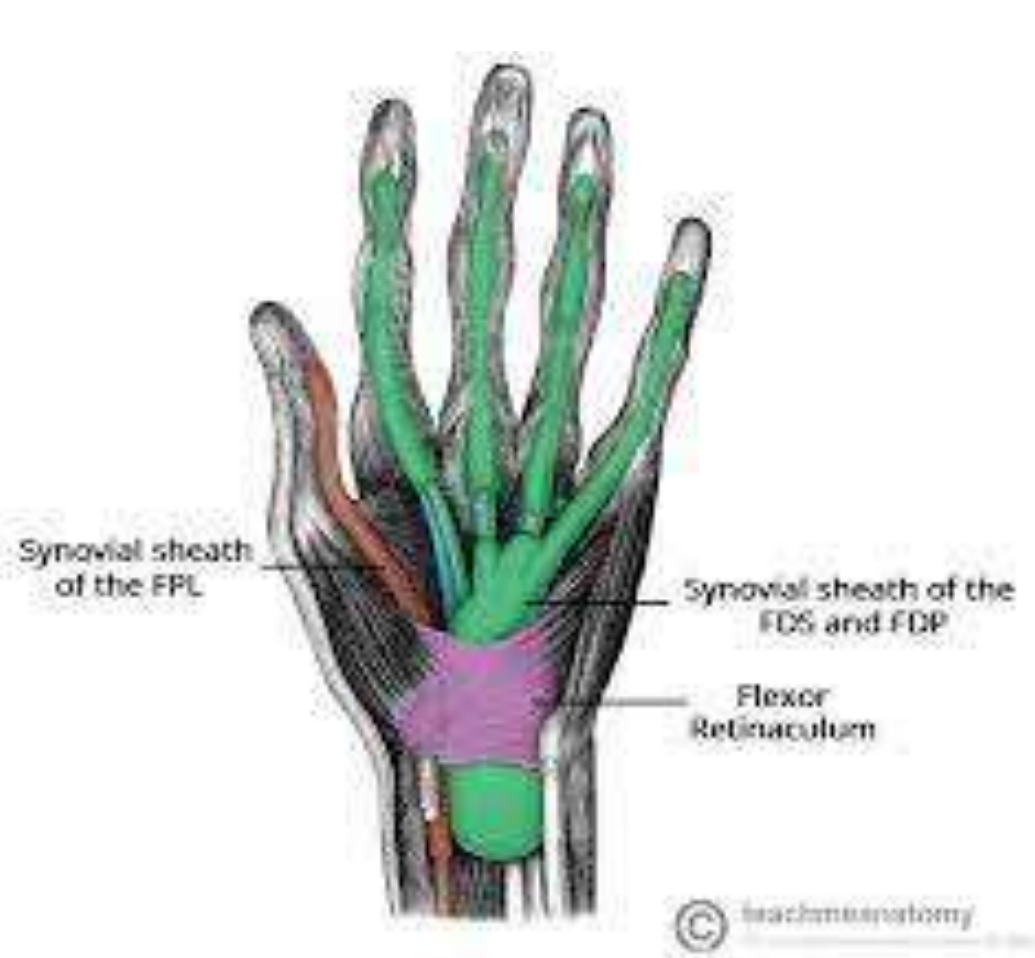- Extends the index finger
- Helps in the extension of the wrist

CLINICAL TESTING

**In that position, ask patient to
Extend index finger alone**



Flexor Retinaculum



A strong fibrous band formed by the thickening of deep fascia in front of the carpus

Rectangular in shape

Roughly the size and shape of a postage stamp

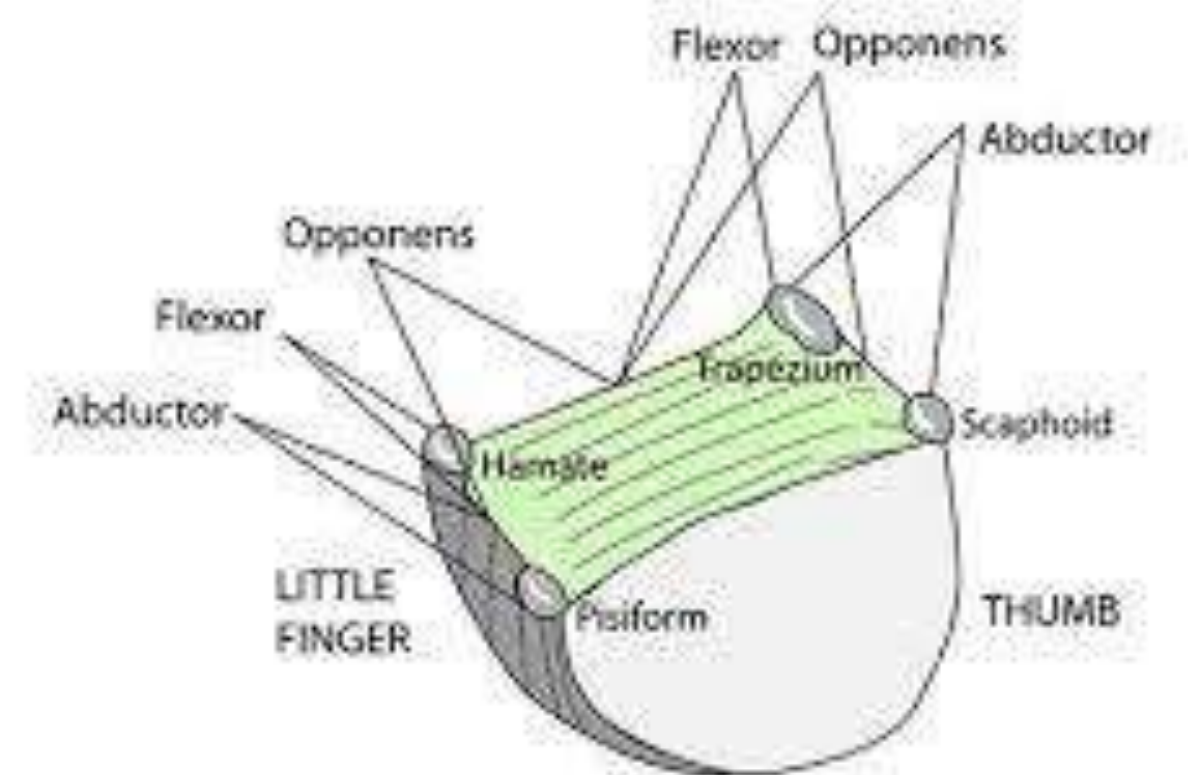
Attachment:

Medially → the pisiform and the hook of the hamate

laterally → the tubercle of scaphoid and crest of the trapezium.

forms an osseofibrous tunnel called carpal tunnel for the passage of flexor tendons of the digits.

MUSCLE ATTACHMENTS TO FLEXOR RETINACULUM





Flexor Retinaculum – on both sides



Lateral deep slip

Attachment : medial lip of the groove on the trapezium

(Note :This acts as tunnel for the tendon of the flexor carpi radialis)

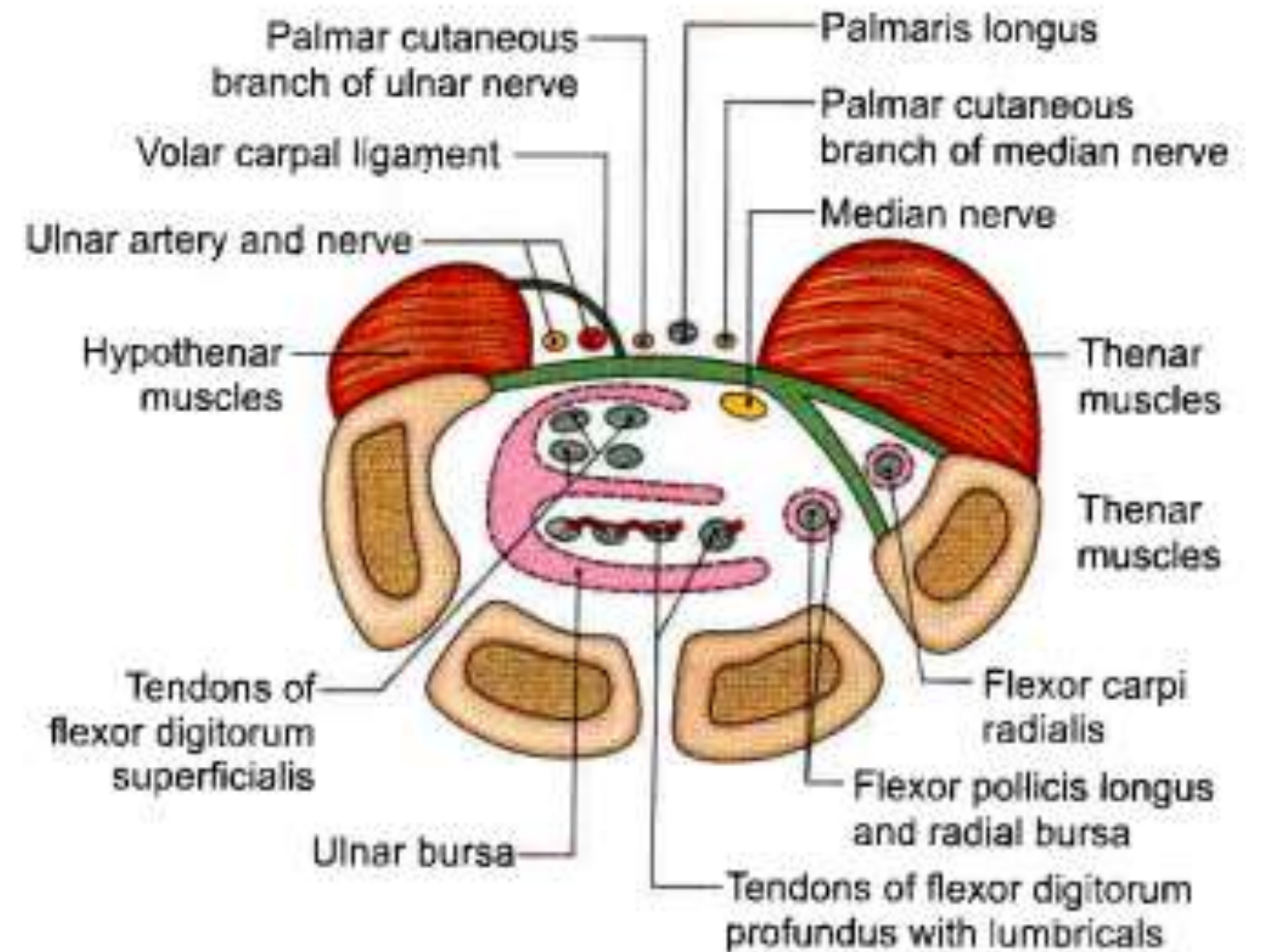
Medial superficial slip (volar carpal ligament)

Attachment : Pisiform bone.

Structures passing :Ulnar vessels and nerves

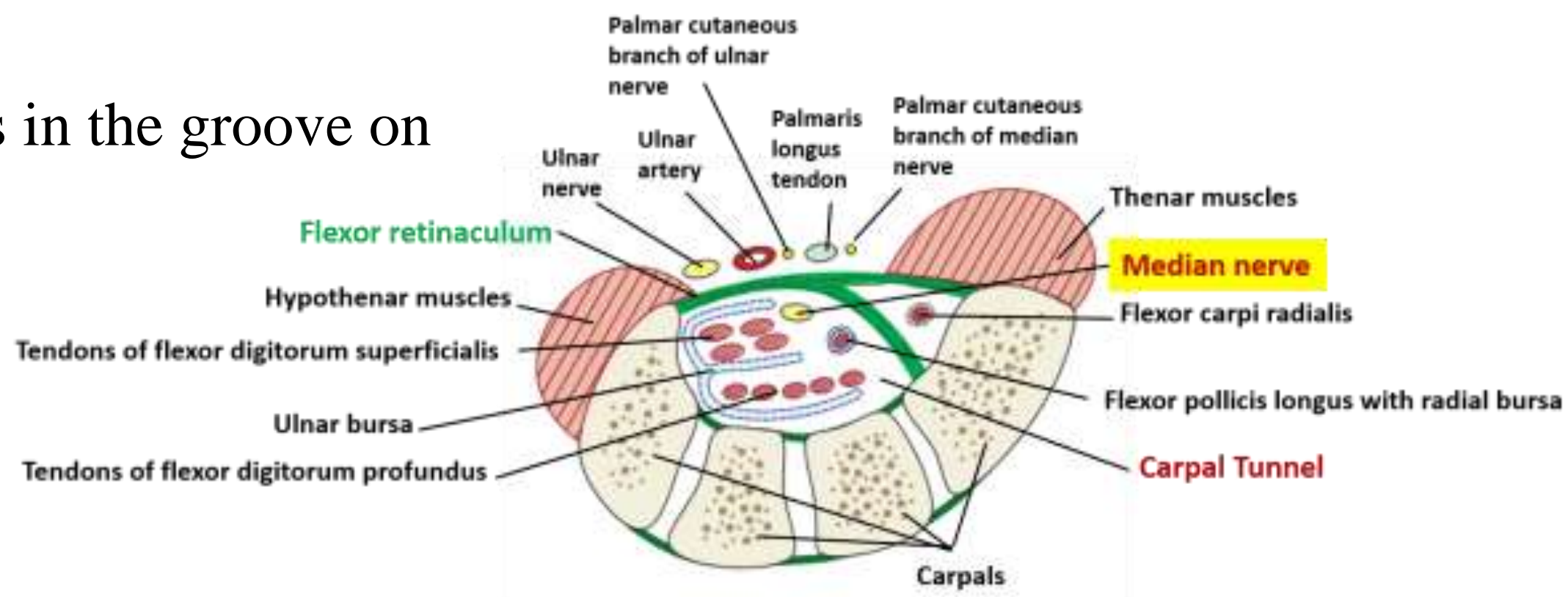
Structures passing superficial

- Palmar cutaneous branch of the median nerve
- Tendon of the palmaris longus
- Palmar cutaneous branch of the ulnar nerve
- Ulnar vessels
- Ulnar nerve.
- Thenar and hypothenar muscles arise from the retinaculum



Structures passing deep

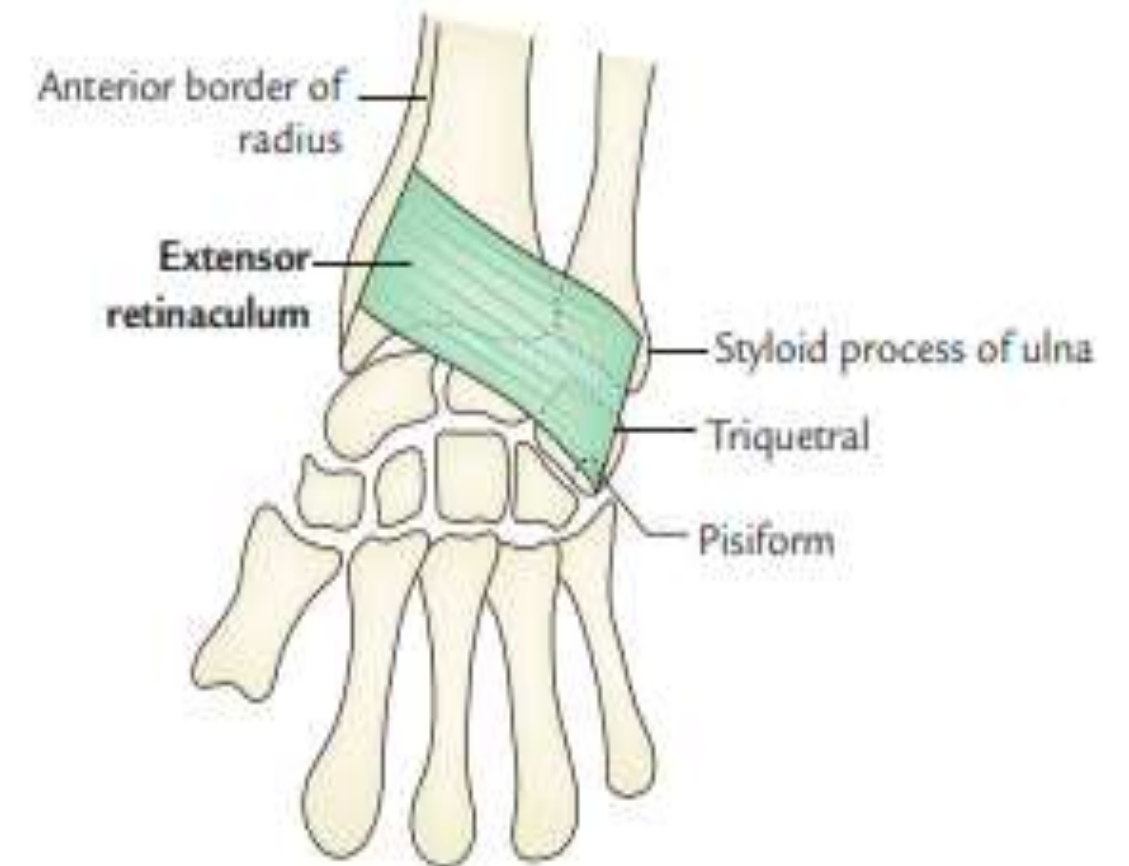
- ✓ Median nerve
- ✓ Flexor digitorum superficialis (4 tendons)
- ✓ Flexor digitorum profundus. The tendon of the flexor pollicis longus (4 tendons)
- ✓ Ulnar bursa
- ✓ Radial bursa
- ✓ Tendon of the flexor carpi radialis in the groove on the trapezium



Extensor Retinaculum

Deep fascia on the back of the wrist is thickened to form an oblique fibrous band called extensor retinaculum.

It is directed downwards and laterally, and about 2 cm broad vertically.



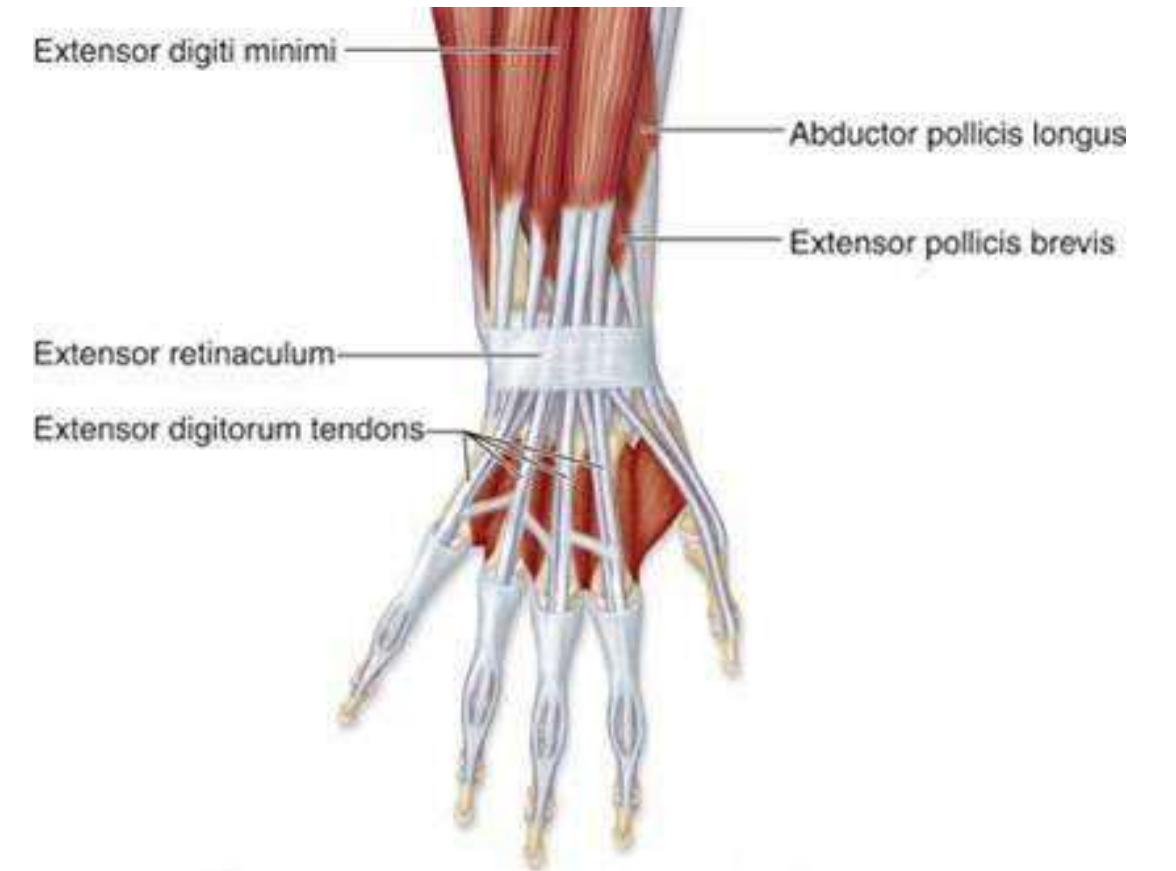


Attachments



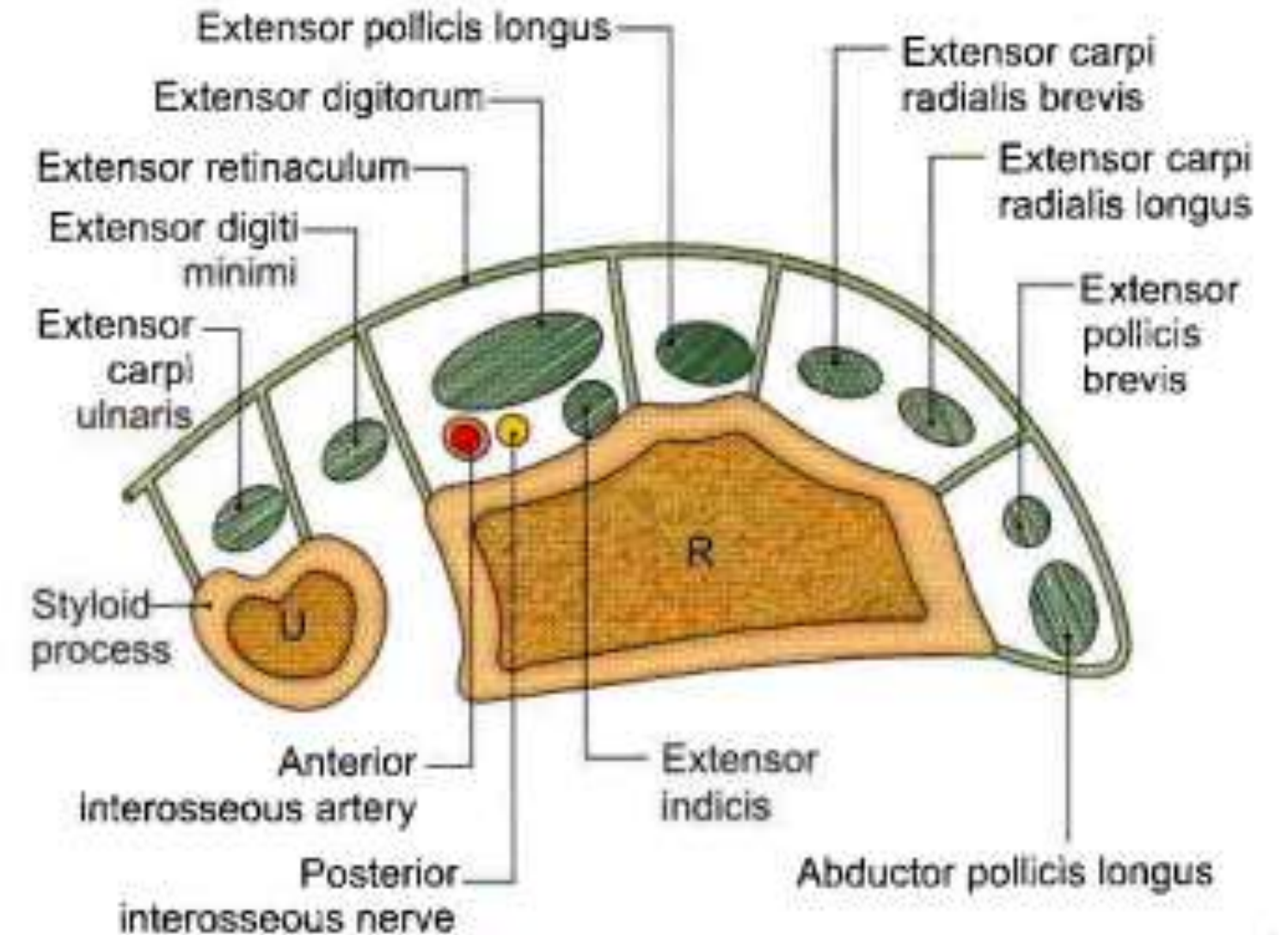
Medial end of extensor retinaculum → styloid process of ulna
triquetral
pisiform

Lateral end → Lower part of the anterior border of the radius.



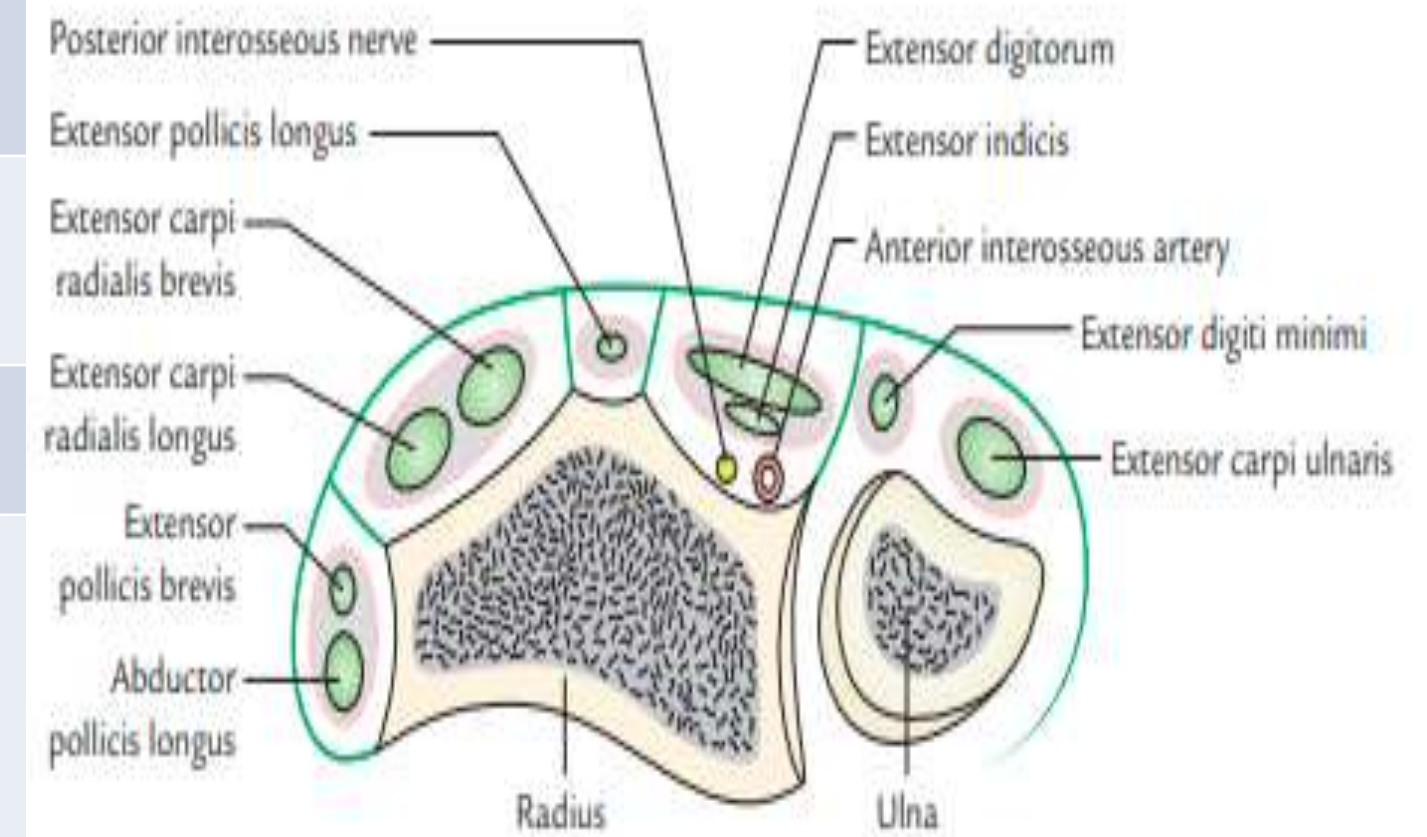
Compartments

- Six compartments
- By five septa extending from retinaculum to the dorsal aspects of the lower ends of radius and ulna.
- The compartments are numbered I to VI from lateral to medial side



Lateral to Medial

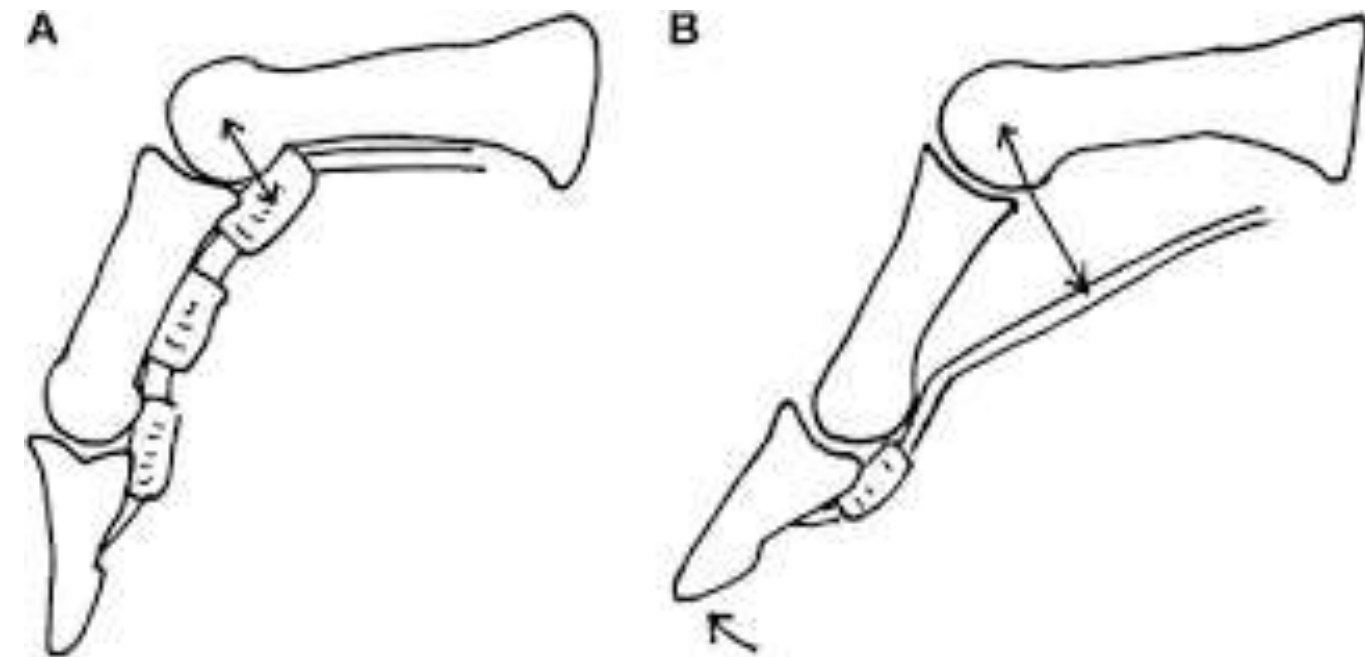
COMPARTMENTS	Structures passing through
1	<ul style="list-style-type: none"> • Abductor pollicis longus (APL) • Extensor pollicis brevis (APB)
2	<ul style="list-style-type: none"> • Extensor carpi radialis longus (ECRL) • Extensor carpi radialis brevis (ECRB)
3	Extensor pollicis longus (EPL)
4	<ul style="list-style-type: none"> • Extensor digitorum (ED) • Extensor indicis (EI) • Posterior interosseous nerve • Anterior interosseous artery
5	Extensor digiti minimi (EDM)
6	Extensor carpi ulnaris (EUC)



Function of Extensor Retinaculum

- Holds the extensor tendon in place on the back of wrist
- Prevents their bowstrings when the hand is extended at the wrist joint.

Note : Prevents the bowstringing of tendon





Nerves – Median nerve



❖ Muscular branches

Pronator teres, Flexor carpi radialis (FCR), Palmaris longus & Flexor digitorum superficialis (FDS)

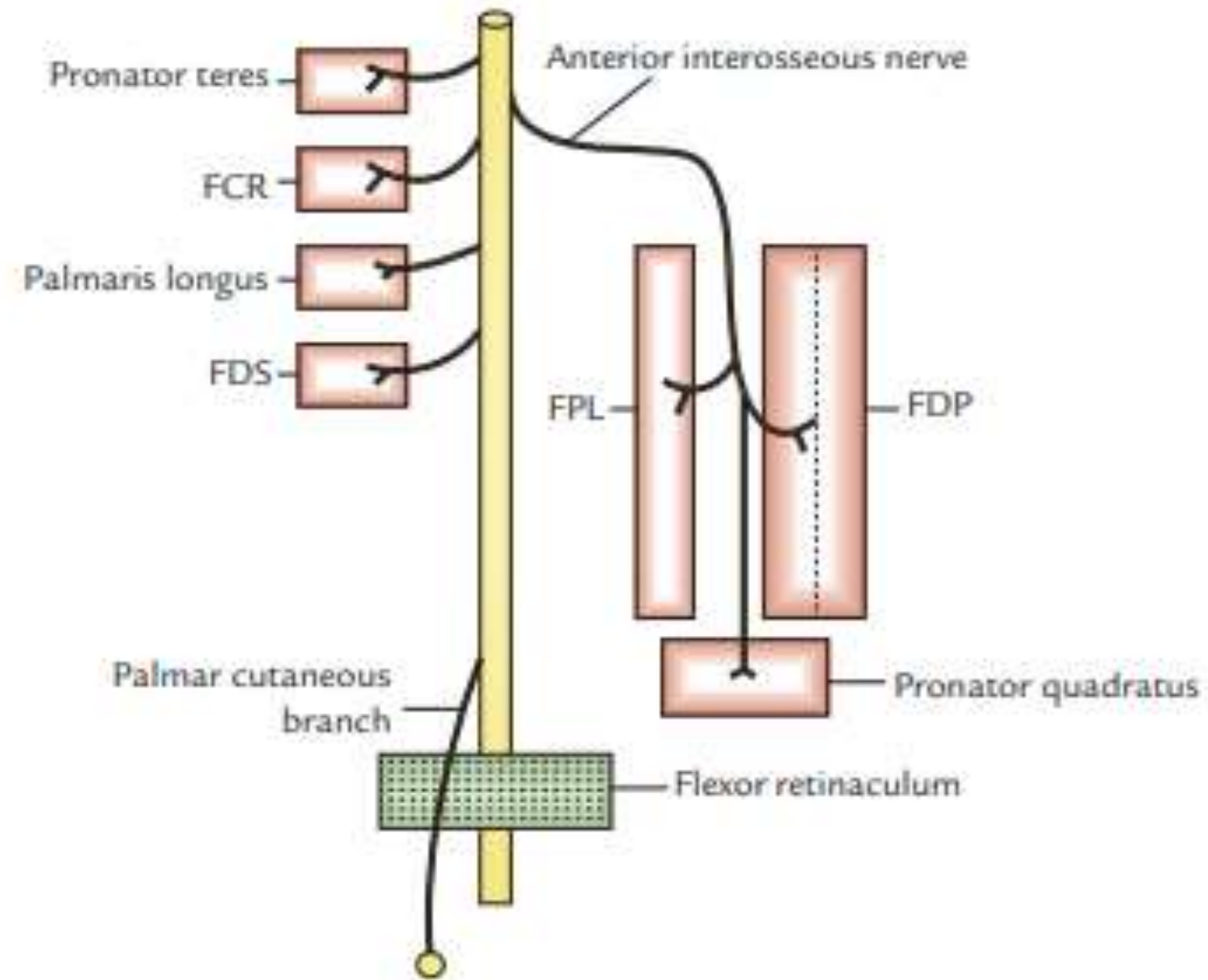
❖ Articular branches

- Elbow
- **Proximal** radioulnar joint

❖ Anterior interosseous branch :

Flexor pollicis longus, **lateral half** of the Flexor digitorum profundus, and Pronator quadratus.

❖ Palmar cutaneous branch : skin over thenar eminence and central part of the palm



Ulnar nerve

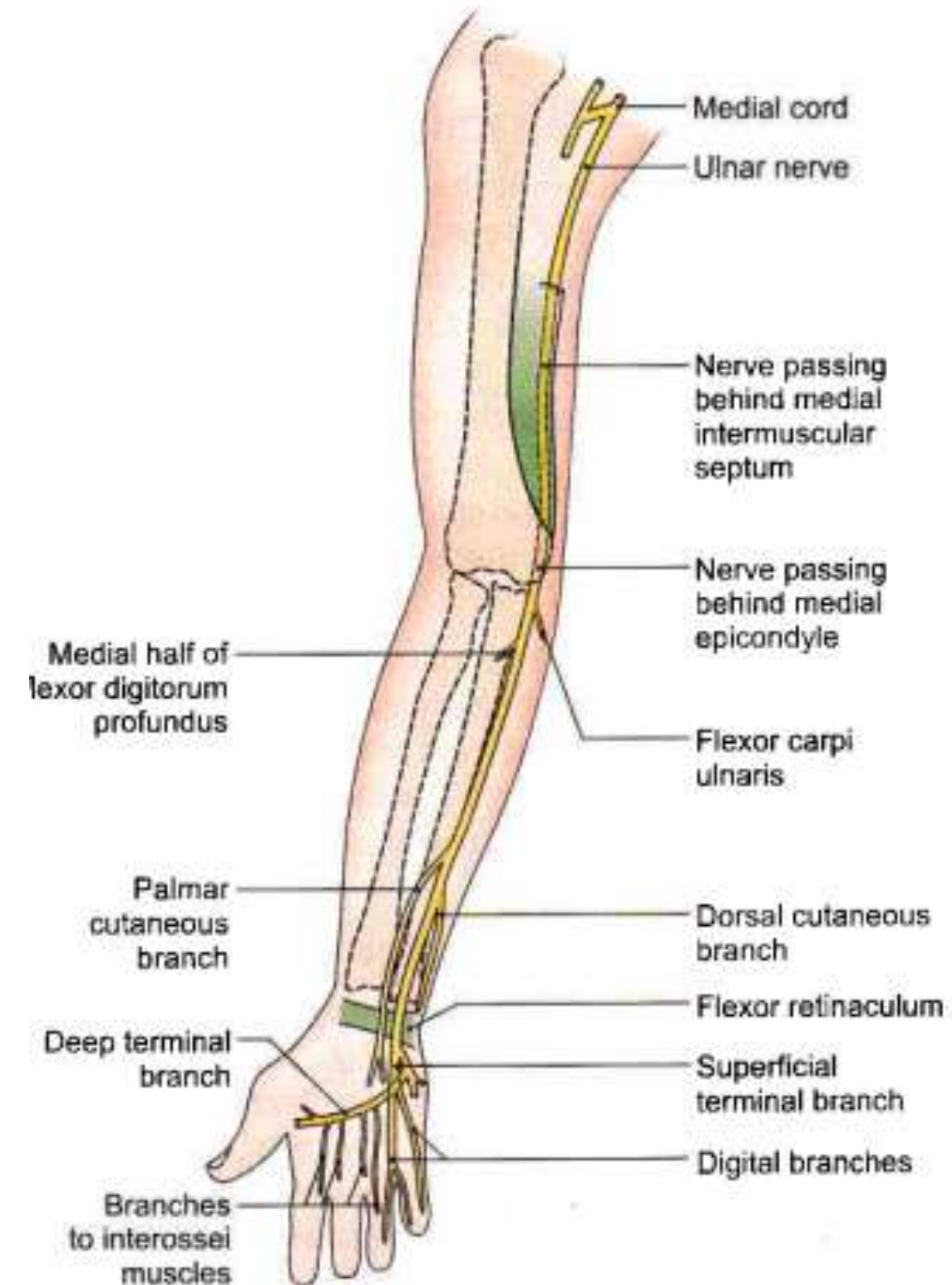
1. Muscular branches

- Flexor carpi ulnaris
- Medial half of the FDP.

2. Articular branch - Elbow joint.

3. Palmar cutaneous branch - the skin over the hypothenar eminence.

4. Dorsal cutaneous branch - reach the dorsum of the hand



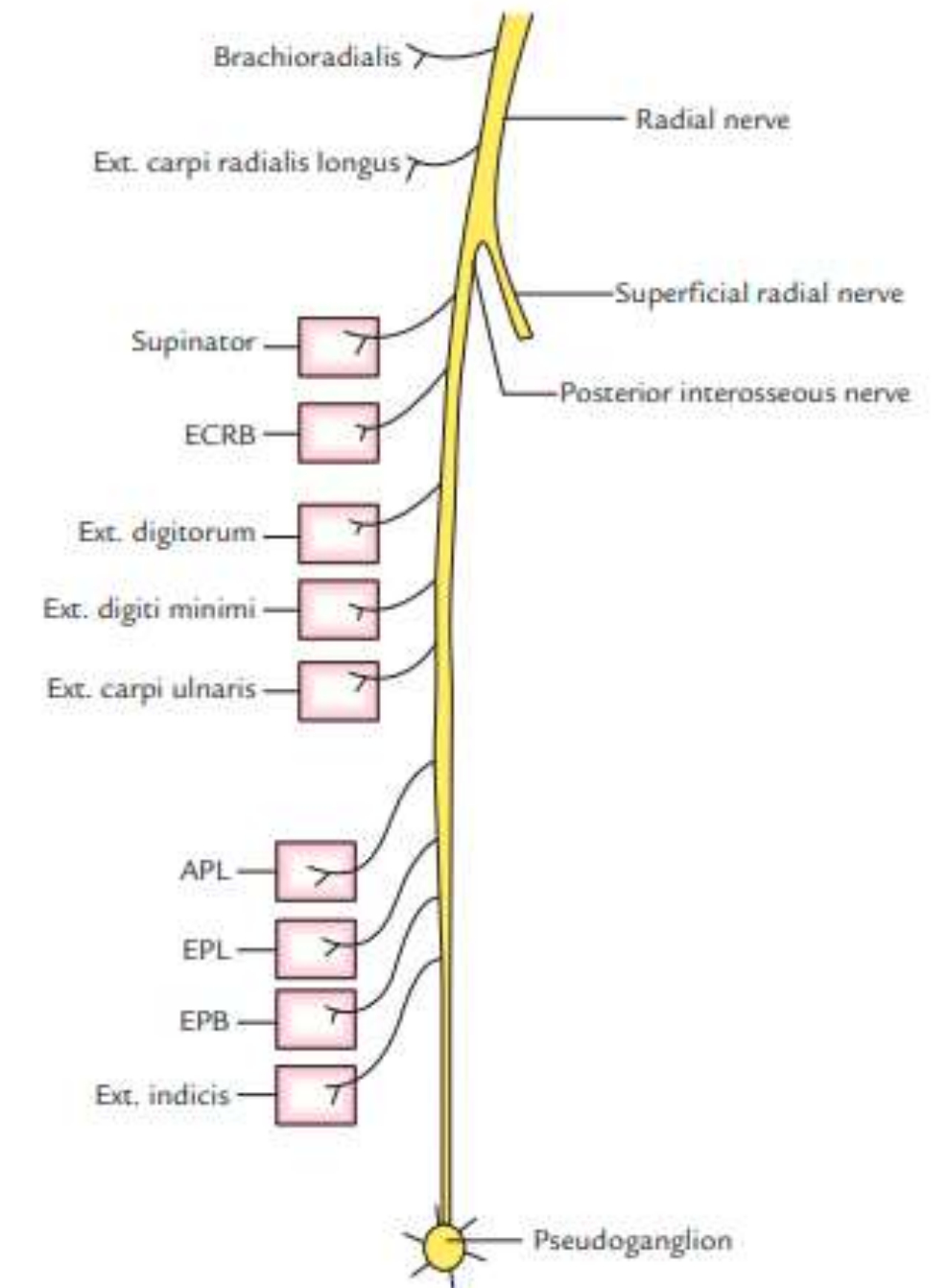
Radial nerve

Branches :

1. The deep terminal branch (posterior interosseous).
2. The superficial terminal branch (the main continuation of the nerve)

Supply

- Deep terminal branch : Muscles of back of forearm
- The super terminal branch is purely cutaneous and is distributed to the lateral half of the dorsum of the hand, and to the proximal parts of the dorsal surfaces of the thumb, the index finger, and lateral half of the middle finger





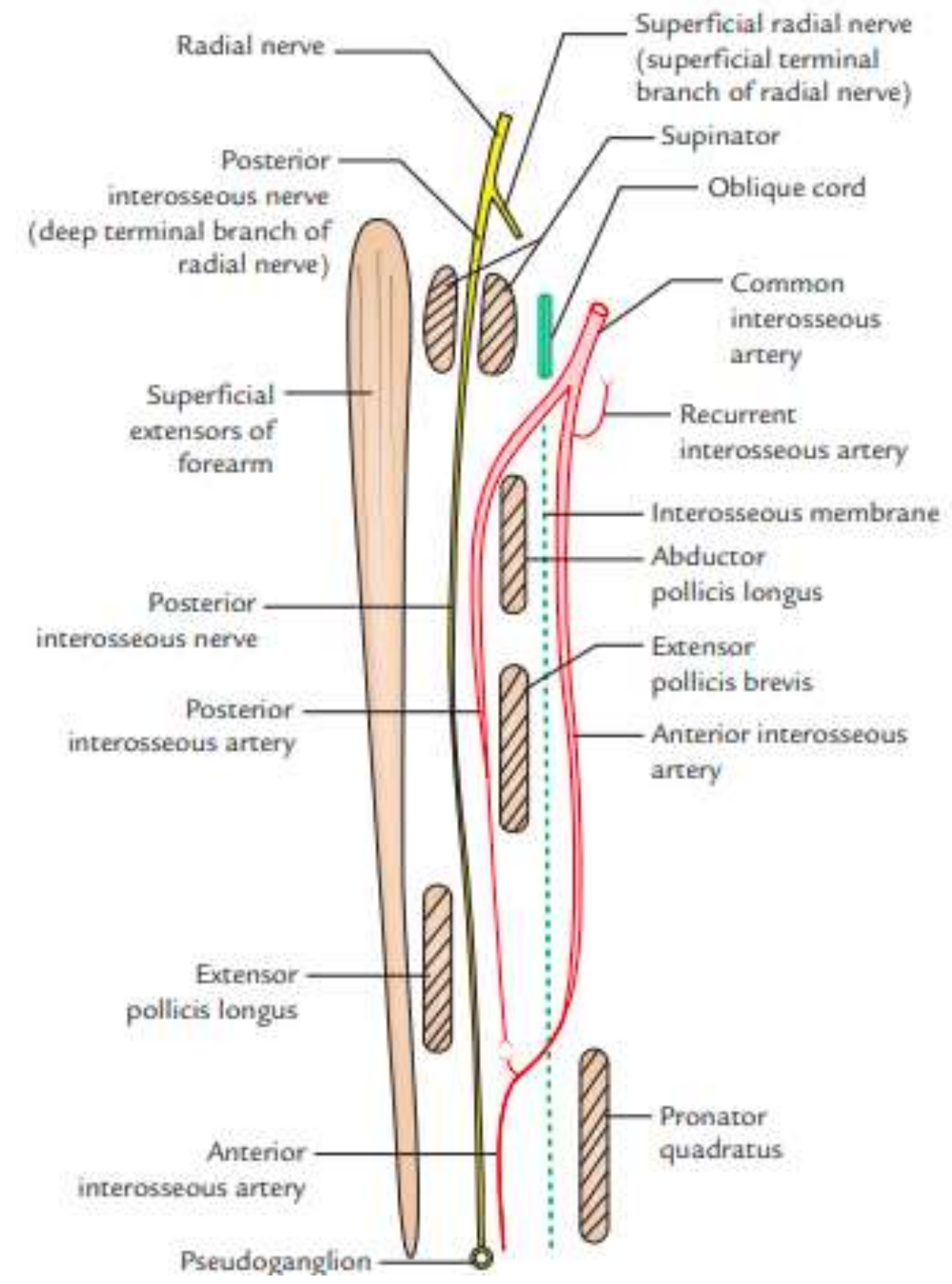
POSTERIOR INTEROSSEOUS ARTERY



Smaller terminal branch of the common interosseous artery from ulnar artery.

Course:

- Begins in the cubital fossa.
- In forearm accompany the posterior interosseous nerve.
- In the lower part of the forearm, it becomes markedly reduced and ends by anastomosing with the anterior interosseous artery.





REFERENCES & THANKING SLIDE