



SNS COLLEGE OF NURSING
Saravanampatti (po), coimbatore



DEPARTMENT OF NURSING
OCCIPITO POSTERIOR POSITION



MALPOSITION

“ Malposition refers to any position of the vertex other than the flexed occipito-anterior one.”

OCCIPITO POSTERIOR POSITION

“In a vertex presentation where the occiput is placed *posteriorly* over the *sacroiliac joint, sacrum* called occipito-posterior position.”



- Occiput placed over:- Right sacroiliac joint called **RIGHT OCCIPITO POSTERIOR**
- Occiput placed over:- Left sacroiliac joint called **LEFT OCCIPITO POSTERIOR**
- Traditionally called 3rd and 4th position of the vertex.

- **Occiput placed over:- sacrum called
DIRECT OCCIPITO POSTERIOR**
- **All the three positions are **Primary**
(before the onset of labour) or
Secondary (developing after labour
starts)**



- In majority of cases (90 %), **ANTERIOR ROTATION** of occiput occurs and follows the course like that of an occipito anterior position and it is favorable position
- But as the posterior position occasionally gives rise to dytokia, it is described along with malpositions

INCIDENCE

- At **onset** of labour:- About **10 %**
- Expected to be **more** during **late pregnancy** and less during **late second stage** of labour
- **Right occipito posterior** is **5 times more** common than the **left occipito posterior**

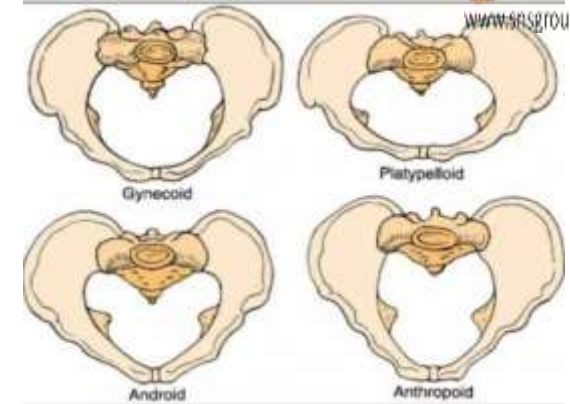


CAUSES

- ☐ **Shape of the pelvic inlet**
- ☐ **Fetal factors**
- ☐ **Uterine factor**

☐ Shape of the pelvic inlet

- **More than 50 % cases are associated with the ANTHROPOID OR ANDROID PELVIC**
- **The wide occiput can comfortably be placed in the wider posterior segment of the pelvis**

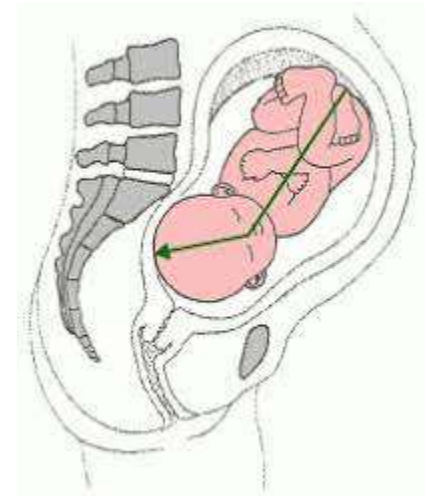


FETAL FACTORS

- **Marked deflexion of the fetal head**
- **Causes of deflexion:-**
 1. **High pelvic inclination (degree of slopping)**
 2. **Anterior attachment of placenta**
 3. **Primary bradycephaly**

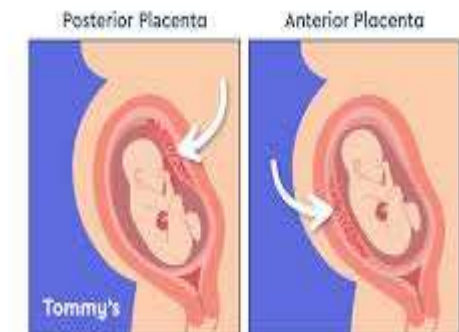- **High pelvic inclination**

- Inclination of brim is high and the upper sacrum is relatively vertical and convex
- Occiput will be placed to posterior surface



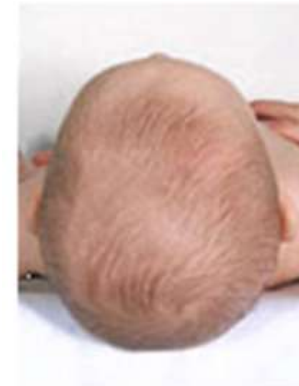- **Anterior attachment of placenta**

- **Well flexed attitude but convexity of maternal and fetal spine is opposite, which leads to deflexion of fetal head and thus the occiput with occupy the posterior part**

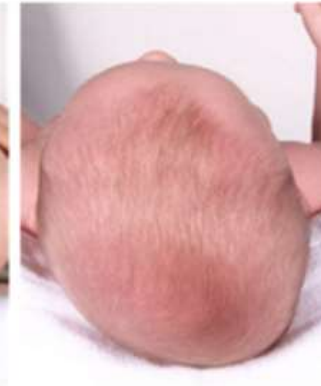

- **Primary bradycephaly (flattened area at back of the skull)**

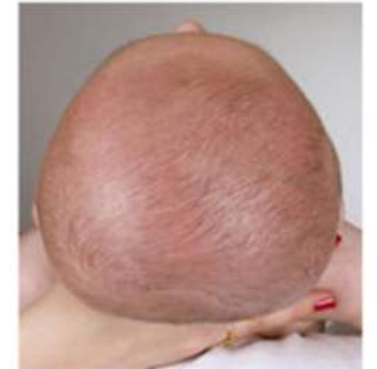– **Diminishes the effective movement of flexion**



Normal



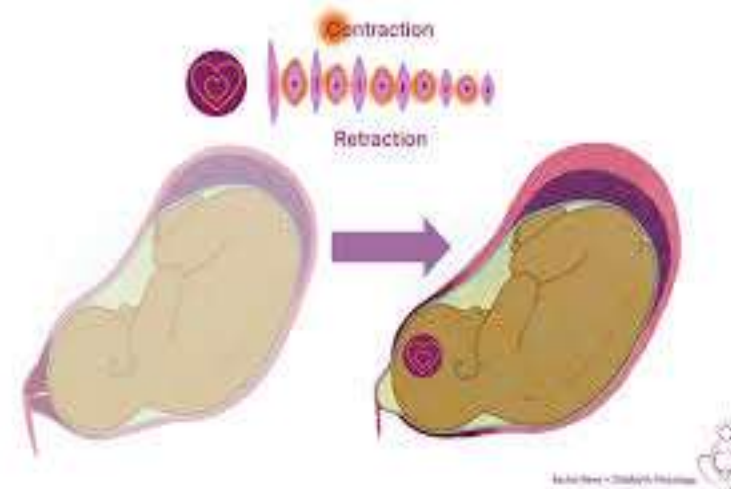
Plagiocephaly



Brachycephaly

❑ Uterine factor

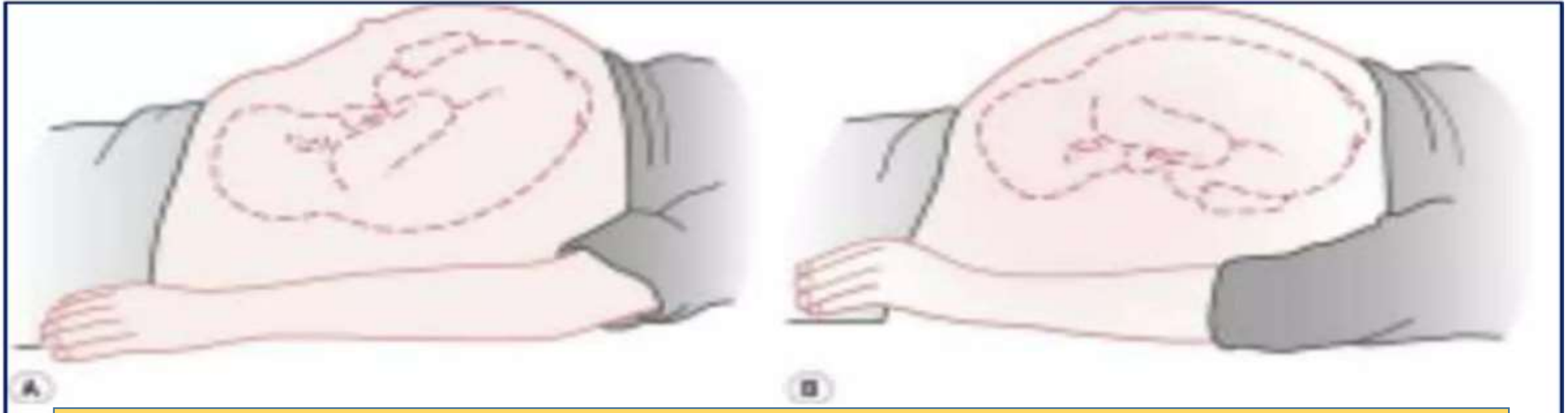
- **Abnormal uterine contraction which may be cause or effect, lead to persistent deflexion and occipito posterior position**



DIAGNOSIS

□ ABDOMINAL EXAMINATION

- **On inspection abdomen looks flat below the level of umbelicus**





UMBILICAL GRIP

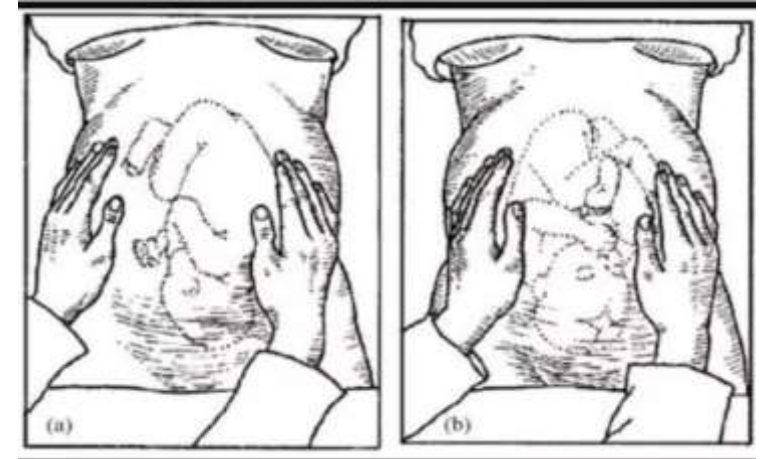
- **Fetal limbs are more easily palpable near the midline on either side**
- **The fetal back is felt far away from the midline on the flank and often difficult to outline clearly.**
- **The anterior shoulder lies far away from the midline**

☐ PELVIC GRIP

- Head is not engaged
- Sinciput not felt as in well flexed occipito posterior

☐ AUSCULTATION

- Intensity of fetal heart sound felt on the flank and often difficult to locate



❑ **VAGINAL EXAMINATION**

- **Elongated bag of membranes which is likely to rupture during examination**
- **Sagital suture occupies any oblique diameters of the pelvis**
- **Posterior fontanelle felt near the sacroiliac joint**
- **Anterior fontanelle felt more easily because of deflexion of the head, lower than posterior fontanelle**

CONCLUSION

- MAL POSITION
- OCCIPITO POSTERIOR POSITION
- INCIDENCE
- CAUSES
- DIAGNOSTIC EVALUATION

References

1. Fraser DM, Cooper MA, Myles Textbook for Midwives. 15th edition. Philadelphia:Churchill livingstone elsevier;2009
2. Dutta DC. Textbook of obstetrics. 6th edition. Calcutta:New central book agency;2004
3. Pillitteri A. Maternal and child health nursing. Care of the childbearing and childrearing family. Sixth edition. Philadelphia; Lippincott Williams & Wilkins: 2010.
4. Cunningham, Leveno, Bloom. William's obstetrics. 23rd edition. United states of America; Mcgraw Hill companies: 2010.

