



**SNS COLLEGE OF ALLIED HEALTH SCIENCES**  
SNS Kalvi Nagar, Coimbatore - 35  
Affiliated to Dr MGR Medical University, Chennai



**DEPARTMENT : PHYSICIAN ASSISTANT**

**COURSE NAME: ANATOMY**

**UNIT : SKELETON SYSTEM**

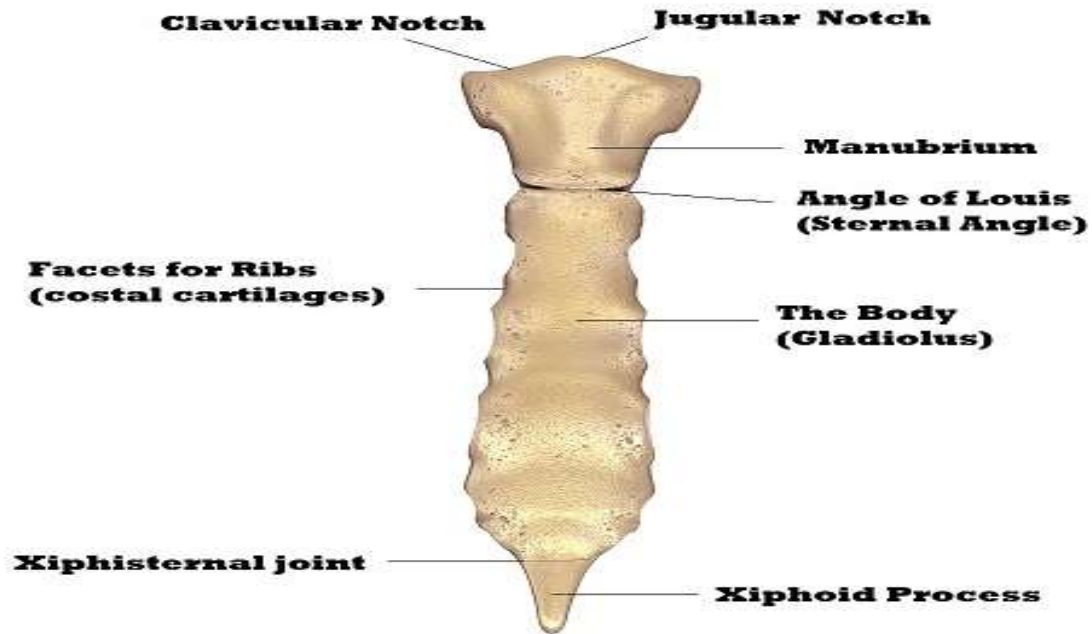
**TOPIC : OTHER BONES**



## STERNUM



- The sternum is the bone that lies in the anterior midline of our thorax. It forms part of the rib cage and the anterior-most part of the thorax.
- It is also the center around which the superior 10 ribs directly or indirectly attached.



**Sternum: Anterior view**



- The sternum (or breastbone) is a flat bone located at the anterior aspect of the thorax. It lies in the midline of the chest and has a ‘T’ shape.
- As part of the bony thoracic wall, the sternum helps protect the internal thoracic viscera – such as the heart, lungs and oesophagus.



## ARTICULATIONS



- Superiorly the manubrium attaches to the neck where the two deep layers of cervical investing fascia insert
- The manubrium: articulates with the first rib (primary cartilaginous), clavicle (atypical synovial), and body of the sternum (secondary or primary cartilaginous joint).
- The body: articulates with the second rib at the sternomanubrial angle and the 3rd to 7th rib and costal cartilages
- Inferiorly articulates with xiphisternal joint, a secondary cartilaginous joint (symphysis)
- Muscle attachments



## MUSCULOTENDINOUS ATTACHMENTS



- Muscle attachments: sternocleidomastoid, intercostal, pectoralis major, sternohyoid, and sternothyroid muscles
- Transversus thoracis muscle arises from the posterior surface of the body
- The xiphisternum attaches to linea alba



## PARTS OF THE STERNUM



The sternum can be divided into three parts

### **Manubrium**

- The manubrium is the most superior portion of the sternum. It is trapezoid in shape.
- The superior aspect of the manubrium is concave, producing a depression known as the jugular notch – this is visible underneath the skin. Either side of the jugular notch, there is a large fossa lined with cartilage. These fossae articulate with the medial ends of the clavicles, forming the sternoclavicular joints.



- On the lateral edges of the manubrium, there is a facet (cartilage lined depression in the bone), for articulation with the costal cartilage of the 1st rib, and a demifacet (half-facet) for articulation with part of the costal cartilage of the 2nd rib.
- Inferiorly, the manubrium articulates with the body of the sternum, forming the sternal angle. This can be felt as a transverse ridge of bone on the anterior aspect of the sternum. The sternal angle is commonly used as an aid to count ribs, as it marks the level of the 2nd costal cartilage.





## Body

- The body is flat and elongated – the largest part of the sternum. It articulates with the manubrium superiorly (manubriosternal joint) and the xiphoid process inferiorly (xiphisternal joint).
- The lateral edges of the body are marked by numerous articular facets (cartilage lined depressions in the bone). These articular facets articulate with the costal cartilages of ribs 3-6. There are smaller facets for articulation with parts of the second and seventh ribs – known as demifacets.



## Xiphoid Process

- The xiphoid process is the most inferior and smallest part of the sternum. It is variable in shape and size, with its tip located at the level of the T10 vertebrae. The xiphoid process is largely cartilaginous in structure, and completely ossifies late in life – around the age of 40.
- In some individuals, the xiphoid process articulates with part of the costal cartilage of the seventh rib.



## BLOOD SUPPLY



- Arterial supply: nutrient branches from internal thoracic (mammary) artery; deep to the sternum is the internal thoracic artery laterally
- Venous drainage: tributaries of the internal thoracic veins, posterolateral to the sternum



# LYMPHATIC DRAINAGE



Chain of internal mammary lymph nodes



## NERVE SUPPLY



Nerve supply is via intercostal nerves which arise from the anterior rami of thoracic spinal nerves



# APPLIED ANATOMY



- Costochondritis
- Sternal fractures
- Sternal tumors
- Sternal infections
- Sternal abnormalities



## ASSESSMENT



- What all are the Parts of Sternum ?
- What all are the Applied aspects of Sternum ?