



SNS COLLEGE OF ALLIED HEALTH SCIENCES
SNS Kalvi Nagar, Coimbatore - 35
Affiliated to Dr MGR Medical University, Chennai



**DEPARTMENT : OPERATION THEATRE AND
ANAESTHESIA TECHNOLOGY**

COURSE NAME : ANATOMY

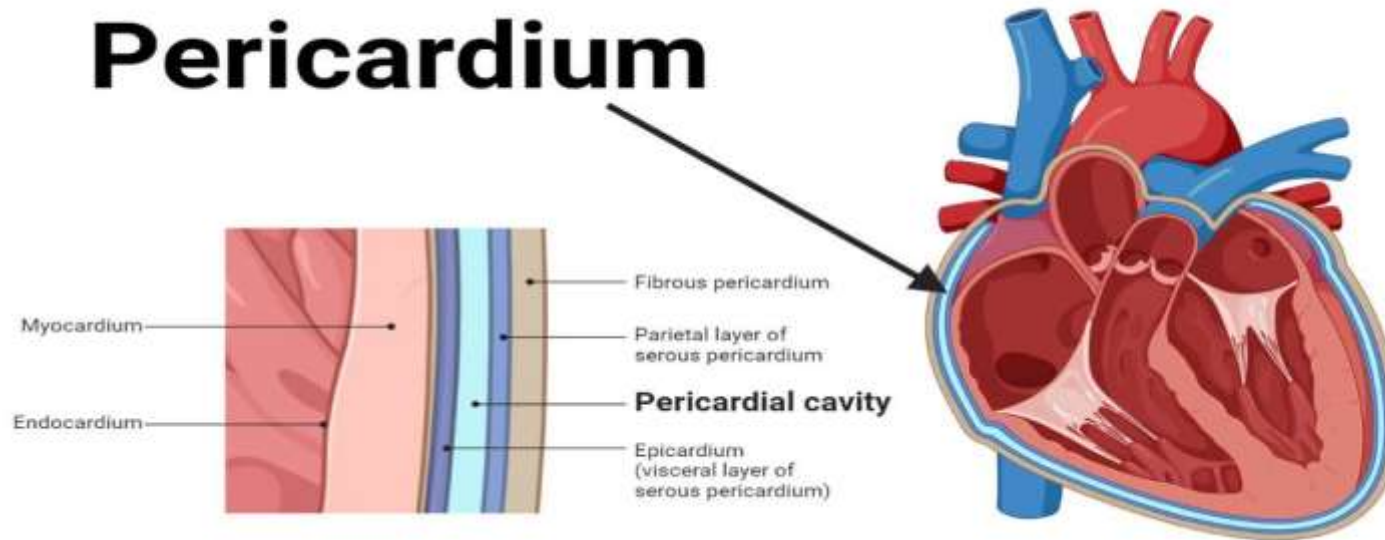
UNIT : HEART

TOPIC : PERICARDIUM



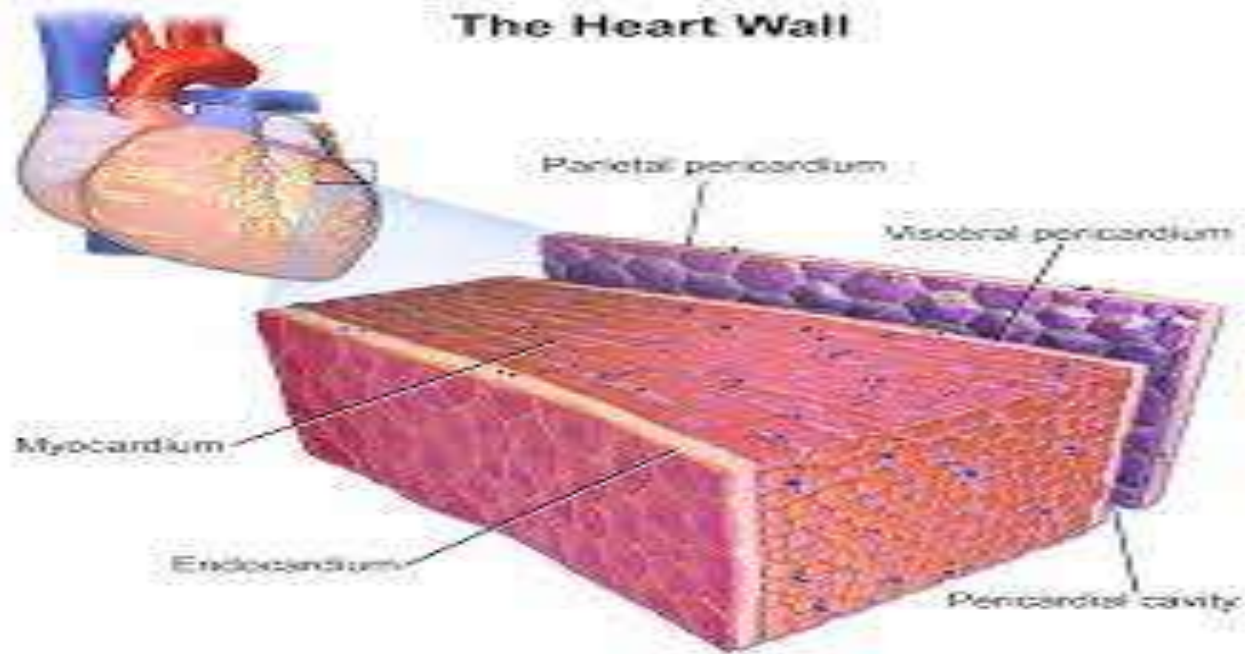
PERICARDIUM

Pericardium





The Heart Wall





- Heart is covered by a fibro-serous membrane called pericardium'. Pericardium consists of outer fibrous layer and inner serous layer. The pericardium keeps the heart in position and prevents its over-distention. The pericardium is having following parts.
- The inner serous pericardium is having an outer parietal layer, which is blended with fibrous pericardium. The visceral layer (epicardium) of the serous pericardium is closely applied to the heart.



- The space between the two layers of serous pericardium is called '**Pericardial cavity**', which contains thin layer of fluid, which allows the free movement of the heart within the fibrous pericardium.



PERICARDIAL SINUSES



These are parts of the pericardial cavity with special significance

Transverse sinus :

It is a transverse gap behind the pulmonary trunk and ascending aorta and in front of superior vena cava.

Oblique sinus :

It is a part of the pericardial cavity behind the left atrium.



Pericardial Cavity and Pericardial Fluid



- The space between the parietal and visceral layers of the serous pericardium forms the pericardial cavity.
- The pericardial cavity contains a small amount of lubricating fluid called pericardial fluid. This fluid reduces friction between the two layers of the serous pericardium as the heart beats and moves within the pericardial sac.



Attachments and Surrounding Structures



- The fibrous pericardium attaches to the diaphragm inferiorly and blends with the adventitia (outer connective tissue layer) of the great vessels entering and exiting the heart.
- The pericardium is suspended within the mediastinum and is attached to surrounding structures, helping to maintain the heart's position and stability within the chest cavity.



Blood and Nerve Supply



Arterial Supply

Fibrous and parietal layer are supplied by branches of internal thoracic artery and descending thoracic aorta. The visceral layer is supplied by coronary arteries.

Nerve Supply

The fibrous and parietal layers are supplied by phrenic and intercostal nerve. The visceral layer is supplied by vagus and sympathetic nerves.



APPLIED ANATOMY



- **Pericarditis:** Infection and inflammation of the pericardium or pericarditis, leads to a roughening of the serous lining of the pericardial cavity. The accumulation of the fluid in the pericardial cavity is called pericardial effusion.
- **Pericardial tamponade:** An accumulation of fluid in the pericardial cavity will compress the heart and decreases the heart rate. It causes chest pain
- **Pericardiocentesis:** In case of cardiac tamponade, it is necessary to drain excess fluid from the pericardial cavity. The procedure by which the excessive fluid of the pericardial cavity is removed is called pericardiocentesis



ASSESSMENT



- What all are the layers of Pericardium ?
- What is Pericardial sinus ?