



**SNS COLLEGE OF ALLIED HEALTH SCIENCES**  
SNS Kalvi Nagar, Coimbatore - 35  
Affiliated to Dr MGR Medical University, Chennai



**DEPARTMENT : CARDIAC TECHNOLOGY**

**COURSE NAME : ANATOMY**

**UNIT : EXCRETORY SYSTEM**

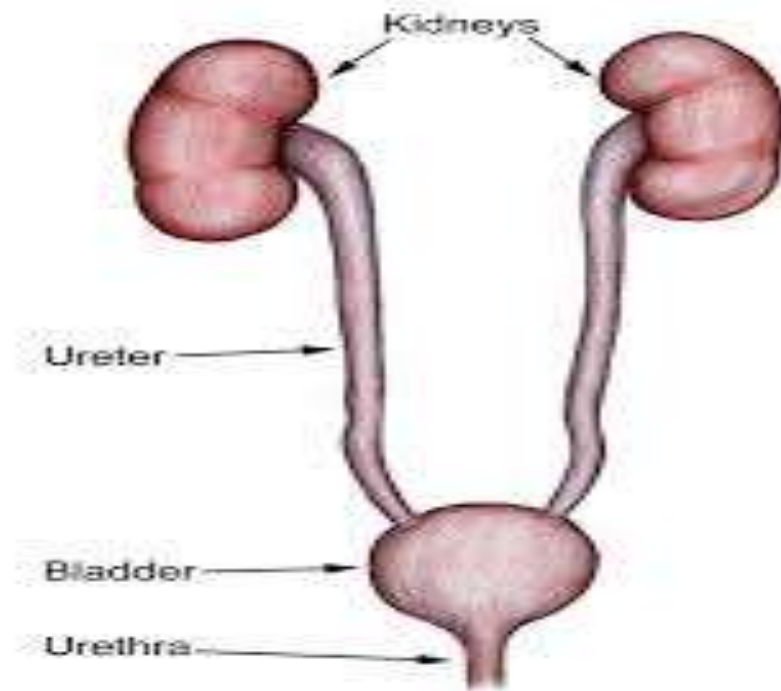
**TOPIC : URETER**



## URETER



- The ureters are bilateral, muscular, tubular structures, responsible for taking urine from one kidney to the urinary bladder for storage, prior to excretion.
- After blood has been filtered in the kidneys, the filtrate undergoes a series of reabsorptions and exudation throughout the length of the convoluted tubules.



10



- The resulting liquid then passes to the collecting tubules, after which it enters the collecting duct.
- From the collecting ducts, the urine passes from the calyces to the renal pelvis, which marks the beginning of the ureters.



## GROSS ANATOMY



The ureter is 25-30 cm long and has three parts:

- Abdominal ureter: from the renal pelvis to the pelvic brim
- Pelvic ureter: from the pelvic brim to the bladder
- Intravesical or intramural ureter: within the bladder wall



## COURSE



- The ureter begins its descent to the bladder by running along the medial aspect of the psoas muscle. Here, the ureter lies anteriorly and slightly medial to the tips of the L2-L5 transverse processes.
- It enters the pelvis anteriorly to the sacroiliac joint at the bifurcation of the common iliac vessels (at the pelvic brim) and then courses anteriorly to the internal iliac artery down the lateral pelvic sidewall.



- At the level of the ischial spine it turns forward and medially to enter the posterolateral wall of the bladder, where it runs an oblique 1-2 cm course, before opening into the bladder at the internal ureteric orifice 1,2.



## RELATIONS



### **Abdominal ureter**

Following the course of the ureter from superior to inferior

posteriorly: psoas muscle; genitofemoral nerve; common iliac vessels; tips of L2-L5 transverse processes

anteriorly

right ureter: descending duodenum (D2); gonadal vessels; right colic vessels; ileocolic vessels, root of small bowel mesentery

left ureter: gonadal artery; left colic artery; loops of jejunum; apex of sigmoid mesocolon and colon





medially

right ureter: IVC

left ureter: abdominal aorta, inferior mesenteric vein



## **Pelvic ureter**

- posteriorly: sacroiliac joint, internal iliac artery
- inferiorly 4
- male: seminal vesicle
- female: lateral fornix of the vagina



- anteriorly
- male: ductus deferens
- female: uterine artery (in the broad ligament)
- medially
- female: cervix



## BLOOD SUPPLY



- Arterial supply: from branches of the renal artery, abdominal aorta, superior and inferior vesical arteries
- Venous drainage: via similarly named veins but is highly variable



## LYMPHATIC DRAINAGE



Abdominal ureter: aorto-caval and common iliac nodes

Pelvic ureter: internal and external iliac nodes



## INNERVATION



Renal plexus and ganglia

Renal and upper ureteric branches from the intermesenteric plexus proximally

Middle ureteric branch of the intermesenteric plexus in the middle segment



## APPLIED ANATOMY



- Ureteral Obstruction
- Kidney Stones
- Ureteral Stricture
- Ureteral Reflux
- Ureteral Cancer
- Ureteropelvic Junction (UPJ) Obstruction
- Ureteritis
- Ureterocele



## ASSESSMENT



- What is the Gross Anatomy of Ureter ?
- What all are the Relations of Ureter ?