



SNS COLLEGE OF ALLIED HEALTH SCIENCES
SNS Kalvi Nagar, Coimbatore - 35
Affiliated to Dr MGR Medical University, Chennai



DEPARTMENT : CARDIAC TECHNOLOGY

COURSE NAME : ANATOMY

UNIT : THORAX

TOPIC : RIBS



RIBS



- The ribs are a set of twelve paired bones which form the protective 'cage' of the thorax. They articulate with the vertebral column posteriorly, and terminate anteriorly as cartilage (known as costal cartilage).



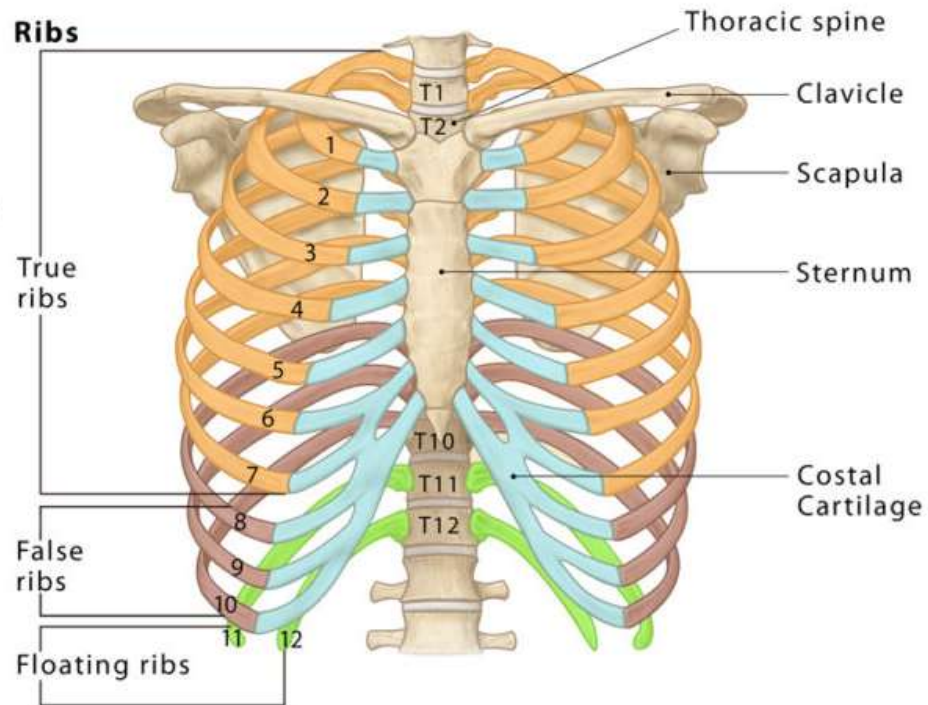
- The ribs form the main structure of the thoracic cage protecting the thoracic organs, however their main function is to aid respiration.
- There are twelve pairs of ribs.



- Each rib articulates posteriorly with two thoracic vertebrae by the costovertebral joint. An exception to this rule is that the first rib articulates with the first thoracic vertebra only.



Rib Bones





CLASSIFICATION OF RIBS



- True ribs – First 7 ribs (Vertebro-sternal ribs)
- False ribs – 8,9,10 (Vertebro-chondral ribs)
- 11 & 12 ribs(Floating ribs)
- Typical – 3 to 9
- Atypical – 1,2,10,11 & 12(*First two & last three)



According to their attachment to the sternum, the ribs are classified into 3 groups: true, false, and floating ribs.

- The true ribs are the ribs that directly articulate with the sternum with their costal cartilages - ribs 1-7. They articulate with the sternum by the sternocostal joints. The first rib is an exception to that rule; it is a synarthrosis and the first rib could uniquely articulate with the clavicle by the costoclavicular joint



- The false ribs (8,9,10) are the ribs that indirectly articulate with the sternum, as their costal cartilages connect with the seventh costal cartilage by the costochondral joint.
- The floating ribs (11,12) do not articulate with the sternum at all (distal two ribs).



- The main function of the thoracic cage is to support thorax and protect the vital structures within it (e.g. heart, lungs, aorta, etc).
- In addition, the rigid structure of the cage allows it to be an attachment point for many muscles of the upper body and to support the weight of the upper limbs.



RIB STRUCTURE



There are two classifications of ribs – atypical and typical. The typical ribs have a generalised structure, while the atypical ribs have variations on this structure.

Typical Ribs

- The typical rib consists of a head, neck and body:



- The **head** is wedge shaped, and has two articular facets separated by a wedge of bone. One facet articulates with the numerically corresponding vertebra, and the other articulates with the vertebra above.
- The **neck** contains no bony prominences, but simply connects the head with the body. Where the neck meets the body there is a roughened tubercle, with a facet for articulation with the transverse process of the corresponding vertebra.



- The **body**, or shaft of the rib is flat and curved. The internal surface of the shaft has a groove for the neurovascular supply of the thorax, protecting the vessels and nerves from damage.

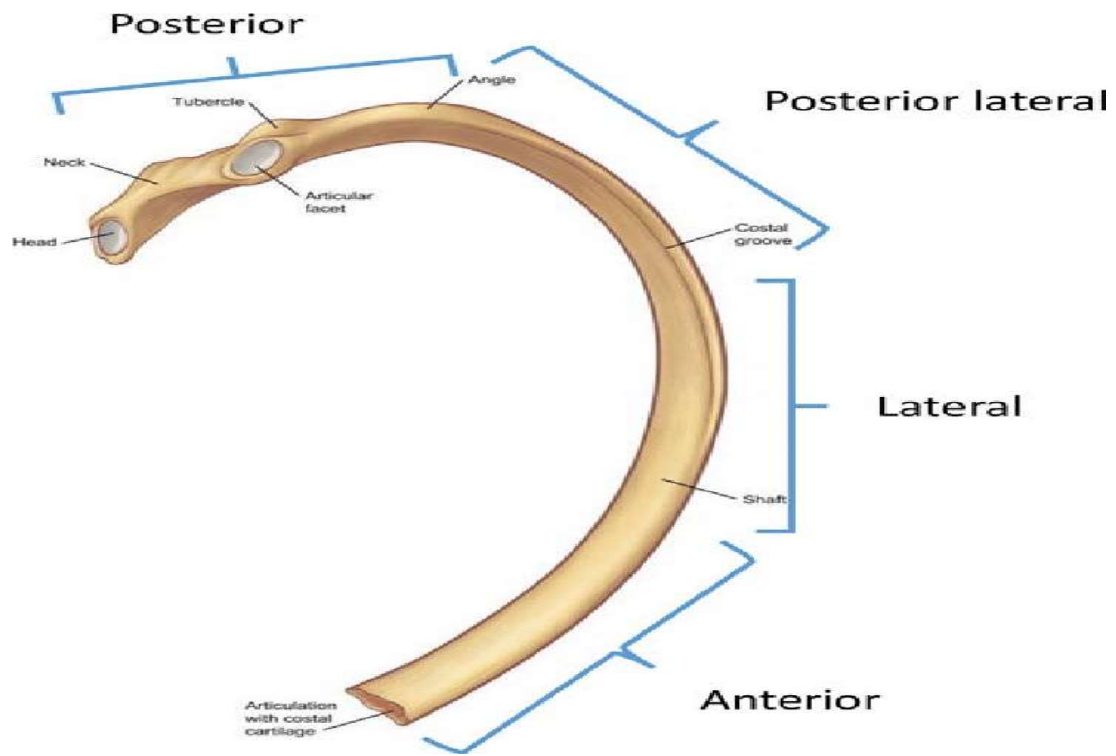


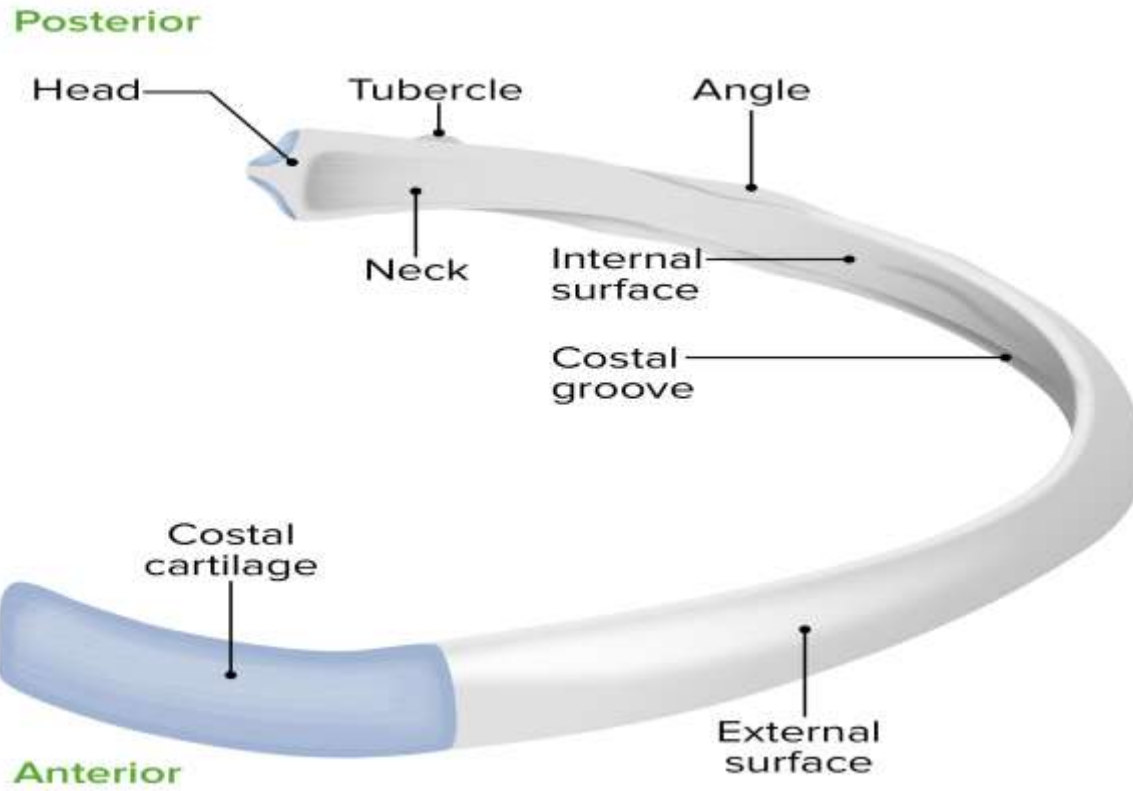
Atypical Ribs

- Ribs 1, 2, 10, 11 and 12 can be described as 'atypical' – they have features that are not common to all the ribs.
- Rib 1 is shorter and wider than the other ribs. It only has one facet on its head for articulation with its corresponding vertebra (there isn't a thoracic vertebra above it). The superior surface is marked by two grooves, which make way for the subclavian vessels.



- Rib 2 is thinner and longer than rib 1, and has two articular facets on the head as normal. It has a roughened area on its upper surface, from which the serratus anterior muscle originates.
- Rib 10 only has one facet – for articulation with its numerically corresponding vertebra.
- Ribs 11 and 12 have no neck, and only contain one facet, which is for articulation with their corresponding vertebra.







ARTICULATIONS



The majority of the ribs have an anterior and posterior articulation.

Posterior

All the twelve ribs articulate posteriorly with the vertebra of the spine.

Each rib forms two joints:

Costotransverse joint – Between the tubercle of the rib, and the transverse costal facet of the corresponding vertebra.

Costovertebral joint – Between the head of the rib, superior costal facet of the corresponding vertebra, and the inferior costal facet of the vertebra above.



Anterior

The anterior attachment of the ribs vary:

Ribs 1-7 attach independently to the sternum.

Ribs 8 – 10 attach to the costal cartilages superior to them.

Ribs 11 and 12 do not have an anterior attachment and end in the abdominal musculature. Because of this, they are sometimes called 'floating ribs'.



MUSCLE ATTACHMENTS



There are a number of muscles related to ribs.

Intercostal muscles: situated in the intercostal spaces.

Diaphragm: arises from the inner surfaces of the costal cartilages on the sixth rib

Serratus anterior: originates anterolaterally from the 1st to 8th ribs



Pectoralis major and minor muscles arise from superior anterior ribs

Latissimus dorsi: originates from the 9th to 12th ribs

Scalenus anterior, posterior and medius muscles have attachments on the first and second ribs

Rectus abdominis: inserts at the xiphisternum and the 5th to 7th costal cartilages[1]



APPLIED ANATOMY



- Costochondritis
- Rib Fractures
- Osteoporosis
- Tietze Syndrome
- Rib Dislocation
- Rib Tumors
- Costovertebral Joint Dysfunction
- Bone Infections (Osteomyelitis)



ASSESSMENT



- What is the Classification of Rib ?
- What all are the Muscle attachments of Rib ?