



**SNS COLLEGE OF ALLIED HEALTH SCIENCES**  
SNS Kalvi Nagar, Coimbatore - 35  
Affiliated to Dr MGR Medical University, Chennai



**DEPARTMENT : CARDIAC TECHNOLOGY**

**COURSE NAME : ANATOMY**

**UNIT : THORAX**

**TOPIC : PLEURA**



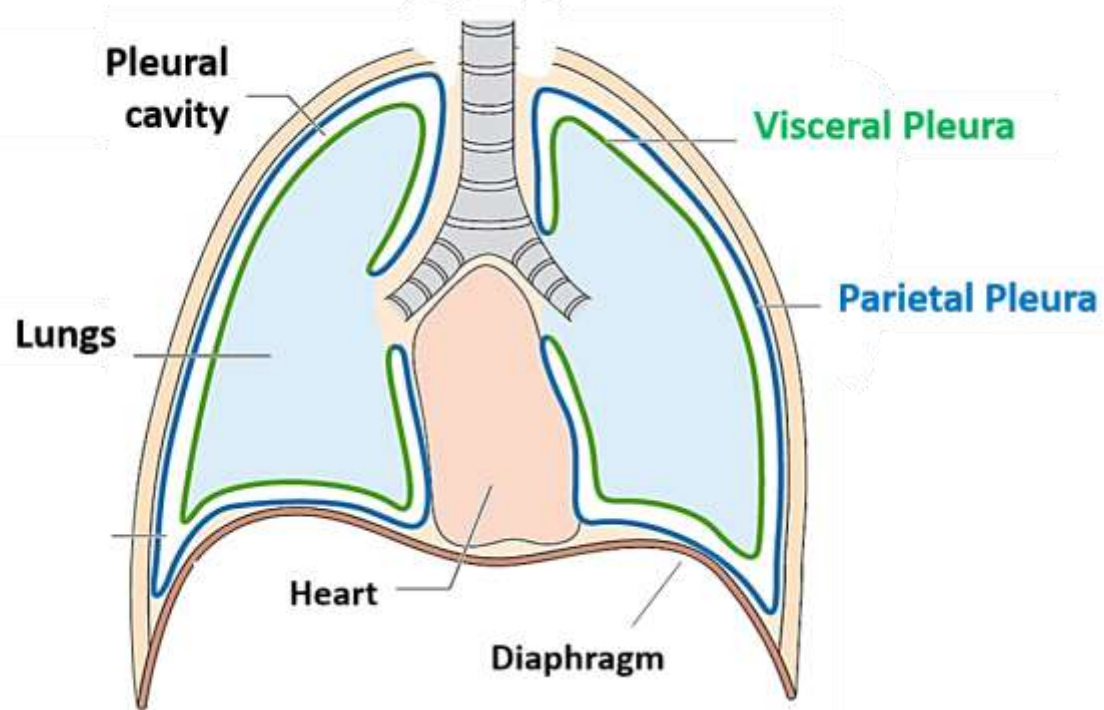
# PLEURA



- The pleura is a double-layered serous membrane that covers each lung and lines the thoracic cage. The outer layer (parietal pleura) attaches to the chest wall.
- The inner layer (visceral pleura) covers the lungs, neurovascular structures of the mediastinum and the bronchi.



### Layers of Pleura





- The space between the parietal and visceral pleurae is called the pleural cavity which contains a small amount of serous fluid (pleural fluid).
- It is important to note that there is no connection between the right and left pleural cavities.



- visceral pleura which covers the surface of the lung and dips into the fissures between its lobes
- parietal pleura which lines the inner of the chest wall and named according to the site it lines:
  - Cervical pleura
  - Costal pleura
  - Diaphragmatic pleura
  - Mediastinal pleura



# PLEURAL FISSURES



- Oblique or major fissure
- Horizontal or minor fissure
- Accessory fissures



## PLEURAL RECESSES



The lungs do not completely fill the anterior and posterior regions of pleural cavities resulting in the formation of pleural recesses. These recesses provide potential spaces in which fluid can collect, they include:

- Costodiaphragmatic recesses (also called costophrenic recesses)
- Costomediastinal recesses
- Phrenicomediastinal recesses
- Vertebromediastinal recesses



## ARTERIAL SUPPLY



- Parietal pleura is supplied by internal thoracic, intercostal and phrenic arteries
- Visceral pleura is supplied by bronchial arteries





# VENOUS DRAINAGE



Parietal: Internal thoracic, intercostal and phrenic veins

Visceral: Pulmonary veins



# VENOUS DRAINAGE



- Intercostal Nerves
- Phrenic Nerve



## LYMPHATIC DRAINAGE



lymphatic vessels drain to lymph nodes within the deep pulmonary plexus



# APPLIED ANATOMY



- Pleurisy (Pleuritis)
- Pleural Effusion
- Pleural Effusion
- Empyema
- Pleural Thickening
- Mesothelioma



# ASSESSMENT



- What all are layers in Pleura ?
- What all are the Applied aspects of Pleura ?