



SNS COLLEGE OF ALLIED HEALTH SCIENCES
SNS Kalvi Nagar, Coimbatore - 35
Affiliated to Dr MGR Medical University, Chennai



DEPARTMENT : CARDIAC TECHNOLOGY

COURSE NAME : ANATOMY

UNIT : INTRODUCTION TO ANATOMY

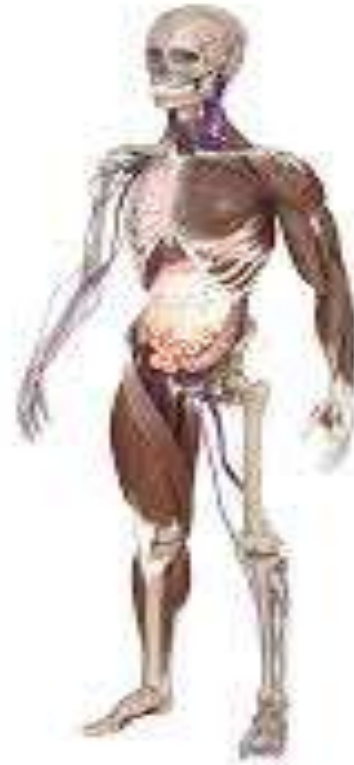TOPIC : BASIC ANATOMICAL TERMINOLOGIES



INTRODUCTION TO ANATOMY



- Anatomy is the identification and description of the structures of living things.
- It is a branch of biology and medicine.





- Human anatomy
- Animal anatomy — zootomy
- Plant anatomy — phytotomy



GROSS ANATOMY



- In medicine, gross, macro, or topographical anatomy refers to the study of the biological structures that the eye can see. In other words, a person does not need a microscope to see these features.
- The study of gross anatomy may involve dissection or noninvasive methods. The aim is to collect data about the larger structures of organs and organ systems.



Anatomical Directions



Anterior (Ventral): Front of the body.

Posterior (Dorsal): Back of the body.

Superior: Upper part or above.

Inferior: Lower part or below.

Medial: Closer to the midline.

Lateral: Away from the midline.

Proximal: Closer to the point of attachment.

Distal: Farther from the point of attachment.



HUMAN ORGAN SYSTEMS



There are 11 organ systems in the human body:

the skeletal system

the muscular system

the lymphatic system

the respiratory system

the digestive system

the nervous system, including the central and autonomic systems

the endocrine system, which regulates hormone production

the cardiovascular system, including the heart

the urinary system

the reproductive system

the integumentary system, which includes the skin, hair, and nails, among other areas



- Circulatory system – including the heart, the blood vessels, properties of the blood, and how circulation works in sickness and health.
- Digestive/excretory system – charting the movement of solids from the mouth to the anus; this includes study of the spleen, liver, and pancreas, the conversion of food into fuel and its final exit from the body.
- Endocrine system – the study of endocrine hormones that carry signals throughout the organism, helping it to respond in concert. The principal endocrine glands – the pituitary, thyroid, adrenals, pancreas, parathyroids, and gonads – are a major focus, but nearly all organs release endocrine hormones.



- Integumentary system – the skin, hair, nails, sweat glands, and sebaceous glands (secreting an oily or waxy substance).
- Musculoskeletal system – the skeleton and muscles, tendons, ligaments, and cartilage. Bone marrow – where red blood cells are made – and how bones store calcium and phosphate are included.
- Nervous system – the central nervous system (brain and spinal cord) and the peripheral nervous system. Study of the nervous system includes research into the senses, memory, emotion, movement, and thought.
- Renal/urinary system – including the kidneys, ureters, bladder, and urethra, this system removes water from the blood, produces urine, and carries away waste.



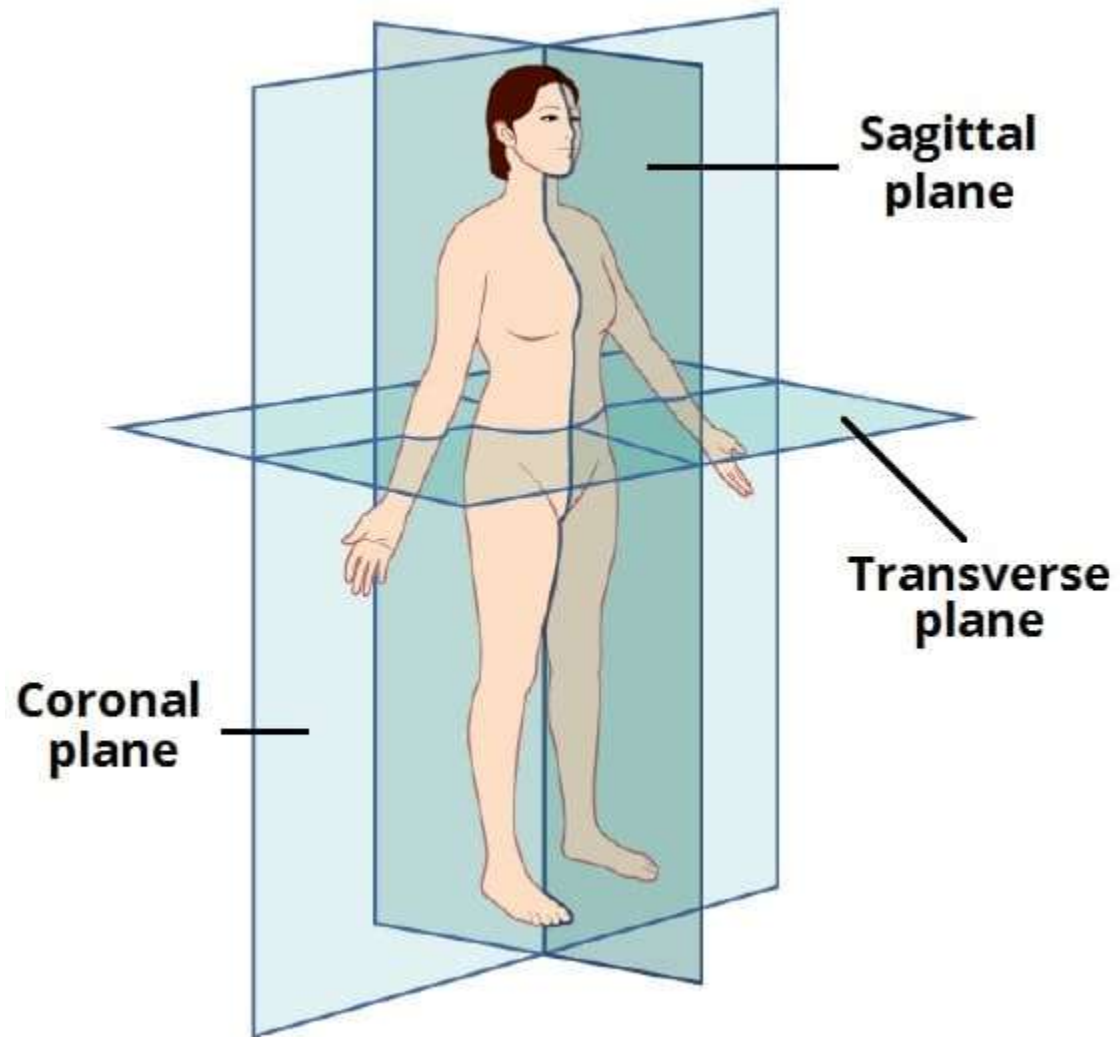
- Immune system – the body’s natural defense system is comprised of white blood cells, the thymus, and lymph systems. A complex array of receptors and molecules combine to protect the host from attacks by pathogens. Molecules such as antibodies and cytokines feature heavily.
- Reproductive system – consisting of the gonads and the sex organs. Study of this system also includes investigating the way a fetus is created and nurtured for 9 months.
- Respiratory system – consisting of the nose, nasopharynx, trachea, and lungs. This system brings in oxygen and expels carbon dioxide and water.



PLANES OF THE BODY



- The anatomical planes are hypothetical planes used to describe the location of structures in human anatomy.
- They are applied to the human body in the anatomical position.
- In this article, we shall look at the anatomical planes in more detail – in particular, the three most commonly used planes: sagittal, coronal and transverse.





SAGITTAL PLANE



- The sagittal plane is a vertical plane which passes through the body longitudinally. It divides the body into a left section and a right section.
- A specific sagittal plane is the median sagittal plane – which passes down the midline of the body, separating it into equal halves.



CORONAL PLANE



- The coronal plane is a vertical plane which also passes through the body longitudinally – but perpendicular (at a right angle) to the sagittal plane.
- It divides the body into a front (anterior) section and back (posterior) section.



TRANSVERSE PLANE



- The transverse plane is a horizontal plane. It is perpendicular to both the sagittal and coronal planes, and parallel to the ground.
- It divides the body into an upper (superior) section and a lower (inferior) section.
- Transverse planes are also known as transaxial planes or axial planes.



Optometry Tissues of the body - epithelium, connective tissue, bone and cartilage



- Epithelial tissue is derived from all three major embryonic layers. The epithelial tissue composing cutaneous membranes develops from the ectoderm.
- Epithelial tissue composing a majority of the mucous membranes originate in the endoderm. Epithelial tissue that lines vessels and open spaces within the body are derived from mesoderm.



- Epithelial tissue that lines vessels in the lymphatic and cardiovascular systems is called endothelium whereas epithelial tissue that forms the serous membranes lining the true cavities is called mesothelium.



- Epithelial cells are typically characterized by unequal distribution of organelles and membrane-bound proteins between their apical and basal surfaces.
- Structures found on some epithelial cells are an adaptation to specific functions.
- For example, cilia are extensions of the apical cell membrane that are supported by microtubules.



CONNECTIVE TISSUE



- Connective tissue, group of tissues in the body that maintain the form of the body and its organs and provide cohesion and internal support.
- The connective tissues include several types of fibrous tissue that vary only in their density and cellularity, as well as the more specialized and recognizable variants—bone, ligaments, tendons, cartilage, and adipose (fat) tissue.



- All forms of connective tissue are composed of (1) extracellular fibres, (2) an amorphous matrix called ground substance, and (3) stationary and migrating cells.
- The anatomical classification of the various types of connective tissue is based largely upon the relative abundance and arrangement of these components.



BONE



- Like other connective tissues, bone consists of cells, fibres, and ground substance, but, in addition, the extracellular components are impregnated with minute crystals of calcium phosphate in the form of the mineral hydroxyapatite.
- The mineralization of the matrix is responsible for the hardness of bone.





- It also provides a large reserve of calcium that can be drawn upon to meet unusual needs for this element elsewhere in the body. The structural organization of bone is adapted to give maximal strength for its weight-bearing function with minimum weight.
- There are bones strong enough to support the weight of an elephant and others light enough to give internal support and leverage to the wings of birds.



CARTILAGE



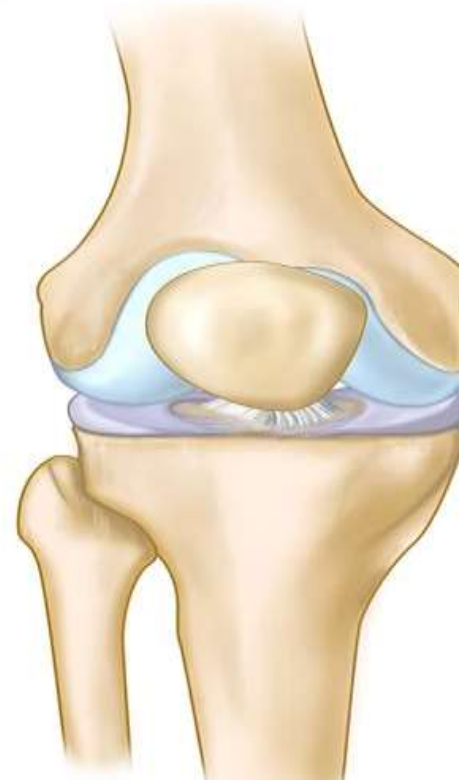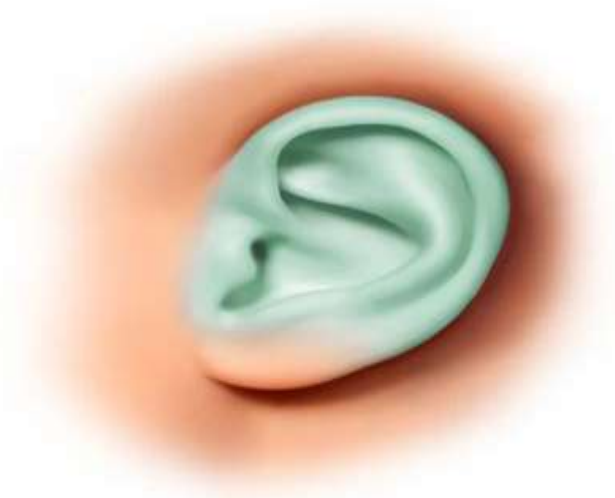- Cartilage is a form of connective tissue in which the ground substance is abundant and of a firmly gelled consistency that endows this tissue with unusual rigidity and resistance to compression.
- The cells of cartilage, called chondrocytes, are isolated in small lacunae within the matrix. Although cartilage is avascular, gaseous metabolites and nutrients can diffuse through the aqueous phase of the gel-like matrix to reach the cells.



Cartilage

Types of cartilage

- Hyaline cartilage
- Elastic cartilage
- Fibrocartilage





- Cartilage is enclosed by the perichondrium, a dense fibrous layer lined by cells that have the capacity to secrete hyaline matrix. Cartilage grows by formation of additional matrix and incorporation of new cells from the inner chondrogenic layer of the perichondrium.
- In addition, the young chondrocytes retain the capacity to divide even after they become isolated in lacunae within the matrix.



- Hyaline cartilage, the most widely distributed form, has a pearl-gray semitranslucent matrix containing randomly oriented collagen fibrils but relatively little elastin.
- It is normally found on surfaces of joints and in the cartilage making up the fetal skeleton. In elastic cartilage, on the other hand, the matrix has a pale yellow appearance owing to the abundance of elastic fibres embedded in its substance.



- Its cells occupy lacunae that are often arranged in rows between the coarse bundles of collagen. It is found in intervertebral disks, at sites of attachment of tendons to bone, and in the articular disks of certain joints.
- Any cartilage type may have foci of calcification.



Types of cells and their arrangements



Epithelial Cells:

Simple Squamous Epithelium: These cells are a single layer of flattened cells found in areas where filtration or diffusion occurs, like the lining of blood vessels (endothelium) or air sacs in the lungs (alveoli).

Stratified Squamous Epithelium: Multiple layers of flat cells that form the outer layer of skin (epidermis) and line body cavities, offering protection against mechanical stress.



Simple Cuboidal Epithelium: Single layer of cube-shaped cells found in kidney tubules and glandular ducts, involved in secretion and absorption.

Simple Columnar Epithelium: Single layer of tall, elongated cells found in the lining of the digestive tract, playing a role in absorption and secretion.

Pseudostratified Columnar Epithelium: Appears stratified but is actually a single layer of cells with varying heights, often seen in the respiratory tract.



Connective Tissue Cells:

Fibroblasts: These cells are found in connective tissues and produce the extracellular matrix and collagen fibers.

Adipocytes: Fat cells that store energy in the form of fat droplets within connective tissue.

Chondrocytes: Cells found in cartilage that produce and maintain the cartilaginous matrix.

Osteocytes: Bone cells embedded in the bone matrix responsible for maintaining bone structure.



Muscle Cells:

Skeletal Muscle Cells (Myocytes): These cells are long and multinucleated, forming striated muscle tissue attached to bones and responsible for voluntary movements.

Smooth Muscle Cells: Non-striated, spindle-shaped cells found in the walls of hollow organs like the intestines and blood vessels, controlling involuntary movements.

Cardiac Muscle Cells: Branched cells forming the heart muscle, exhibiting striations and interconnected by intercalated discs, allowing synchronized contractions.



Nervous Tissue Cells:

Neurons: Transmit electrical signals and are composed of a cell body, dendrites (receiving signals), and an axon (transmitting signals).

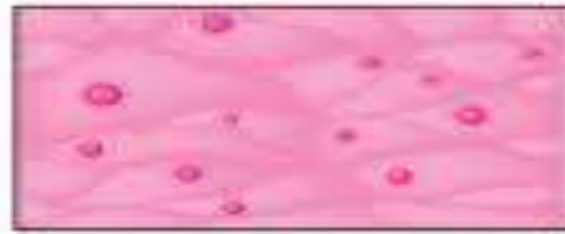Neuroglial Cells (Glial Cells): Supporting cells in the nervous system that provide physical support, insulation, and nutrients to neurons.



Four Types of Tissues



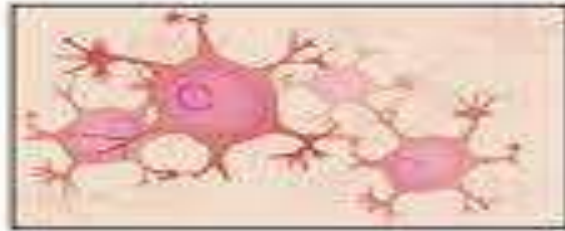Connective tissue



Epithelial tissue



Muscle tissue



Nervous tissue



ASSESSMENT



- What all are the Planes of the Body ?
- What all are the Types of cells and how it is arranged ?