



SNS COLLEGE OF ALLIED HEALTH SCIENCES
SNS Kalvi Nagar, Coimbatore - 35
Affiliated to Dr MGR Medical University, Chennai



**DEPARTMENT : CARDIO PULMONARY PERFUSION
CARE TECHNOLOGY**

COURSE NAME : ANATOMY

UNIT : EXCRETORY SYSTEM

TOPIC : BLADDER



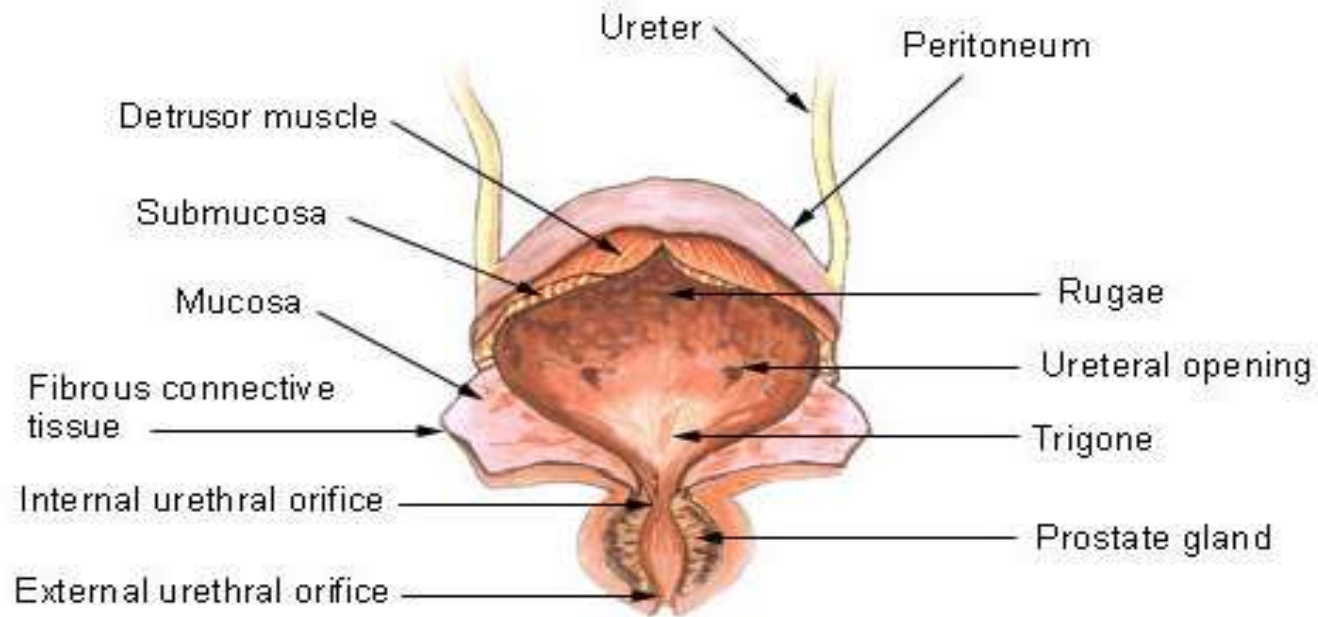
BLADDER



- The urinary bladder is a hollow, muscular, and distensible organ that sits on the pelvic floor and below the peritoneum. Generally, when empty it is pear-shaped with an apex, a base (fundus), neck, superior surface and two inferolateral surfaces.
- However, the size, shape, position, and relationships to adjacent structures of the bladder can change considerably depending on the amount of urine it holds.



Urinary Bladder

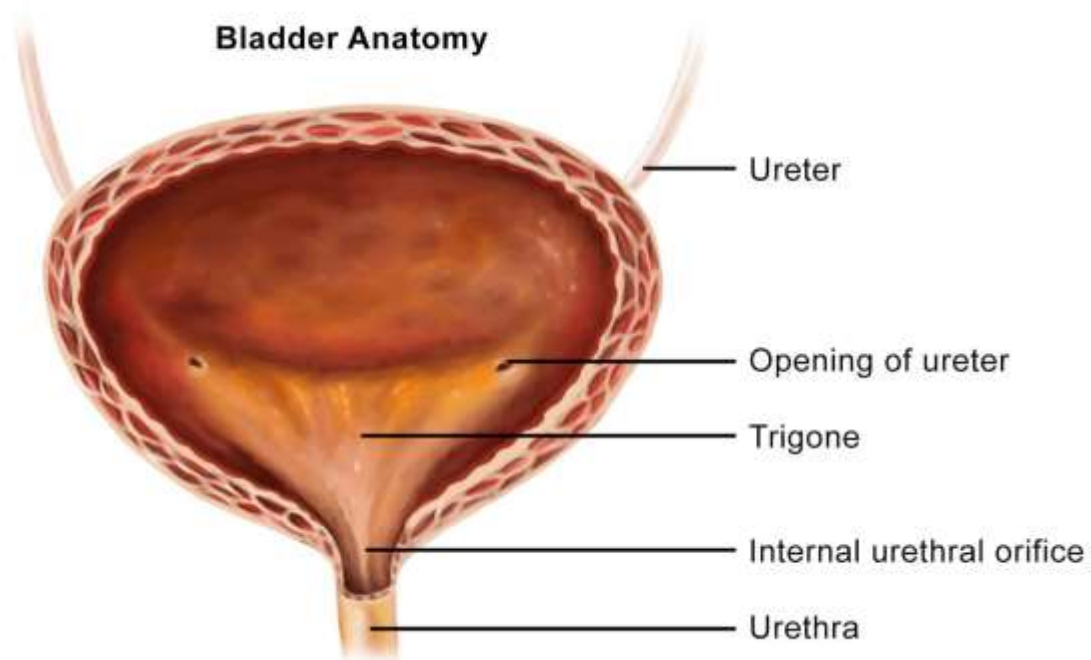




- In men and people assigned male at birth (AMAB), it rests between the pubic bone in the front and the rectum in the back.
- In women and people assigned female at birth (AFAB), it rests in front of the vagina and uterus.



Bladder Anatomy





TRIGONE OF THE BLADDER



- The trigon is a triangular region at the base of the bladder, lined with smooth muscle, collagen, and elastin to a lesser degree.
- Located between the internal-urethral meatus and the two ureteral orifices



EXTERNAL FEATURES



- **Apex** – located superiorly, pointing towards the pubic symphysis. It is connected to the umbilicus by the median umbilical ligament (a remnant of the urachus).
- **Body** – main part of the bladder, located between the apex and the fundus
- **Fundus (or base)** – located posteriorly. It is triangular-shaped, with the tip of the triangle pointing backwards.
- **Neck** – formed by the convergence of the fundus and the two inferolateral surfaces. It is continuous with the urethra.



URETHRAL SPHINCTERS



Internal urethral sphincter:

Male – consists of circular smooth fibres, which are under autonomic control. It is thought to prevent seminal regurgitation during ejaculation.

Females – thought to be a functional sphincter (i.e. no sphincteric muscle present). It is formed by the anatomy of the bladder neck and proximal urethra.



External urethral sphincter – has the same structure in both sexes. It is skeletal muscle, and under voluntary control. However, in males the external sphincteric mechanism is more complex, as it correlates with fibres of the rectourethralis muscle and the levator ani muscle



BLOOD SUPPLY



- Arterial supply is via the superior vesical branch of the internal iliac artery. In males, this is supplemented by the inferior vesical artery, and in females by the vaginal arteries. In both sexes, the obturator and inferior gluteal arteries may also contribute small branches.



- Venous drainage is achieved by the vesical venous plexus, which empties into the internal iliac veins. The vesical plexus in males is in continuity at the retropubic space with the prostate venous plexus (plexus of Santorini), which also receives blood from the dorsal vein of the penis



LYMPHATIC DRAINAGE



- The neck and fundus of the bladder through internal, sacral, and common iliac lymph nodes.
- The superolateral aspect of the bladder is through the external iliac lymph nodes.



NERVE SUPPLY



Sympathetic – hypogastric nerve (T12 – L2). It causes relaxation of the detrusor muscle, promoting urine retention.

Parasympathetic – pelvic nerve (S2-S4). Increased signals from this nerve causes contraction of the detrusor muscle, stimulating micturition.

Somatic – pudendal nerve (S2-4). It innervates the external urethral sphincter, providing voluntary control over micturition.



APPLIED ANATOMY



- Bladder cancer
- Cystitis
- Interstitial cystitis/bladder pain syndrome (IC/BPS)
- Urinary incontinence
- Bladder stones
- Overactive bladder



ASSESSMENT



- What is the Trigone of Bladder ?
- What is the Lymphatic Drainage of Bladder ?