



SNS COLLEGE OF ALLIED HEALTH SCIENCES
SNS Kalvi Nagar, Coimbatore - 35
Affiliated to Dr MGR Medical University, Chennai



**DEPARTMENT : CARDIO PULMONARY PERFUSION
CARE TECHNOLOGY**

COURSE NAME : ANATOMY

UNIT : THORAX

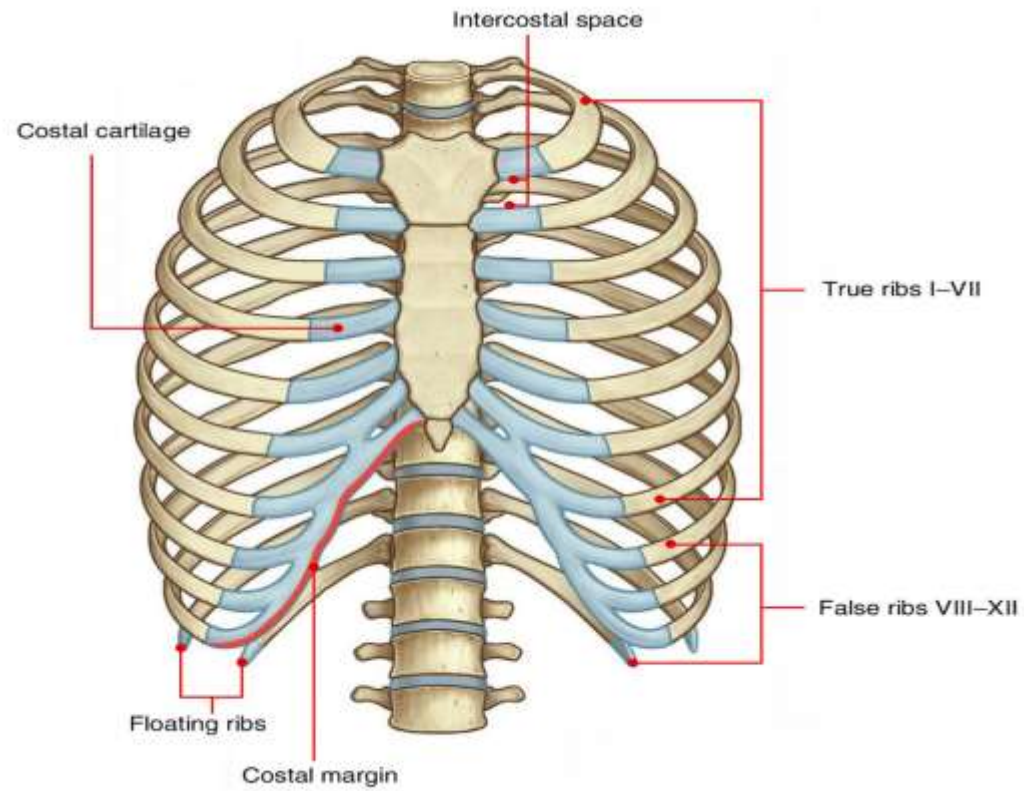
TOPIC : INTERCOSTAL SPACE



INTERCOSTAL SPACE



The intercostal space (ICS) is the anatomic space between two ribs. Since there are 12 ribs on each side, there are 11 intercostal spaces, each numbered for the rib superior to it.





The space located between the ribs is called the intercostal space. Because there are 12 ribs on each side of the thorax, there are 11 intercostal spaces, which comprise intercostal muscles and membranes and neurovascular structures



- The intercostal spaces are the spaces between the ribs in the human rib cage. These spaces are filled with muscles, nerves, blood vessels, and connective tissue that provide support, protection, and facilitate various movements of the chest wall during breathing.
- There are 11 pairs of intercostal spaces (numbered 1-11), corresponding to the 12 pairs of ribs in humans (the 1st intercostal space is between the 1st and 2nd ribs, the 2nd space is between the 2nd and 3rd ribs, and so on).



STRUCTURES IN INTERCOSTAL SPACE



- Intercostal muscle
- Intercostal arteries and intercostal veins
- Intercostal lymph nodes
- Intercostal nerves



INTERCOSTAL MUSCLES



Intercostal Muscles: There are three layers of intercostal muscles:

External Intercostal Muscles: These run obliquely downward and forward from rib above to rib below. They aid in inhalation by elevating the ribs and increasing the thoracic cavity's dimensions.

Internal Intercostal Muscles: These muscles run in the opposite direction to the external intercostals (obliquely downward and backward) and assist in forced expiration by depressing the ribs and decreasing the thoracic cavity's size.

Innermost Intercostal Muscles: Situated deep to the internal intercostals, these muscles are involved in aiding expiration and fine-tuning the movements of the rib cage.



NEUROVASCULAR BUNDLE



- The neurovascular bundle, located in the costal groove in the undersurface of each rib, between the internal intercostal muscle and innermost intercostal muscle, supplies much of the innervation and vascular supply to the thoracic wall.
- The neurovascular bundle is arranged as Vein, Artery and Nerve, from the most superior to the most inferior. An easy way to remember that is to use a mnemonic **VAN**.



INTERCOSTAL ARTERIES



Posterior Intercostal Arteries:

Upper Intercostal Arteries: The first two intercostal spaces are typically supplied by branches called superior intercostal arteries. These arteries arise directly from the costocervical trunk, a branch of the subclavian artery.

Lower Intercostal Arteries: From the thoracic aorta, nine pairs of posterior intercostal arteries (typically) arise, corresponding to the 3rd through 11th intercostal spaces. These arteries travel in the costal grooves along the inferior borders of the ribs.



Collateral Branches:

Muscular Branches: These branches supply the intercostal muscles and adjacent tissues.

Anterior Intercostal Arteries: Some of the lower intercostal spaces also receive blood supply from branches of the internal thoracic artery. These anterior intercostal arteries anastomose (connect) with the posterior intercostal arteries, forming an intercostal arterial network.



INTERCOSTAL VEIN



- The intercostal veins follow a similar distribution with the intercostal nerves and arteries. The anterior intercostal veins drain into the internal thoracic vein, adjacent to the internal thoracic artery.
- The first two posterior intercostal veins drain into the brachiocephalic vein, adjacent to the internal thoracic vein. The lower nine posterior intercostal veins accompany the posterior intercostal arteries, draining into the azygos system.



INTERCOSTAL LYMPH NODES



The superficial tissues, including the breast, are drained by the axillary, and parasternal nodes. Lymphatics drain posteriorly into the intercostal lymph nodes, lying adjacent to the azygous and hemizygous veins.



INTERCOSTAL NERVE



- Intercostal nerves originate segmentally from the anterior rami of spinal nerves T1-T11.
- In addition to motor nerves to the intercostal muscles, they contain sensory afferents from the skin, intercostal muscle, ribs, pleura, and peritoneum.



APPLIED ANATOMY



- Intercostal Muscle Strain
- Intercostal Neuralgia
- Intercostal Nerve Entrapment
- Intercostal Muscle Tears or Rib Fractures
- Intercostal Artery or Vein Injury



ASSESSMENT



- What all are Structures in Intercostal space ?
- What all are the Intercostal muscles ?