



SNS COLLEGE OF ALLIED HEALTH SCIENCES

SNS Kalvi Nagar, Coimbatore - 35

Affiliated to Dr MGR Medical University, Chennai



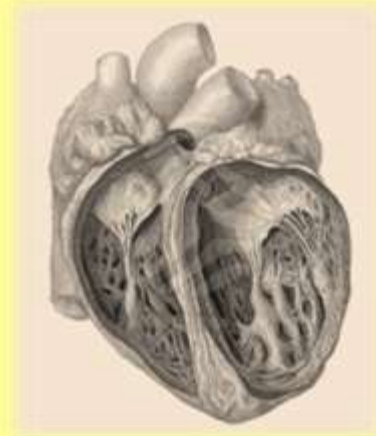DEPARTMENT OF CARDIAC TECHNOLOGY-II YEAR

UNIT V : CONGENITAL HEART DISEASES

ECHO ASSESSMENT



Congenital Heart Diseases





CHD - diagnosing

- Most of CHD diagnosed in newborn and early childhood (VSD, AVSD, ToF, TGA, CoA, PDA, etc.)
- Some of them can be diagnosed in adults: ASD (only smaller), CoA, ccTGA, Ebstein disease of TV, etc. (generally less serious forms)



CHD – diagnosing/follow-up

- History
- Symptoms and Signs
- ECG, pulse oximetry
- Cardiopulmonary exercise testing - especially for timing of (re)intervention
- Holter ECG (24-hours monitor)
- **Echocardiography**
- Chest X-ray
- Cardiac CT and MRI (precise anatomy of heart and big vessels, assessment of RV volume and function, quantification of valvular regurgitation etc.)
- Invasive testing – catheterization – haemodynamics (shunt quantification, pulmonary pressure/resistance measurement etc.) OR electrophysiology testing (assessment of arrhythmias)



CHD – general problems

- **Heart failure** (valvular defect, shunts, volume and/or pressure overloading of ventricles, RV in systemic position)
 - Pharmacotherapy (ACEi, BB, diuretics)
 - CRT (Cardiac resynchronisation therapy) – biventricular stimulation in case of ineffective (dyssynchronous) contraction
 - Heart transplantation
- **Arrhythmias and SCD** (sudden cardiac death)
 - More difficult issue than in normal heart
 - Risk stratification, investigation, and choice of treatment are often different from those applied to the normally formed heart (drugs poorly tolerated, side effects)
 - EP and ablation is prefer
 - Onset of arrhythmias may be a signal of haemodynamic decompensation
 - SCD – especially in: ToF, TGA, ccTGA, aortic stenosis (AS), and UVHs – various risk factors - ICD



CHD – general problems

- **Infectious endocarditis**
 - High risk particularly in:
 - Cyanotic CHD without surgical repair, residual defects, palliative shunts
 - Prosthetic valves
 - Residual defects (generally) after surgical or cath. closure
 - Patients with previous IE



CHD – general problems

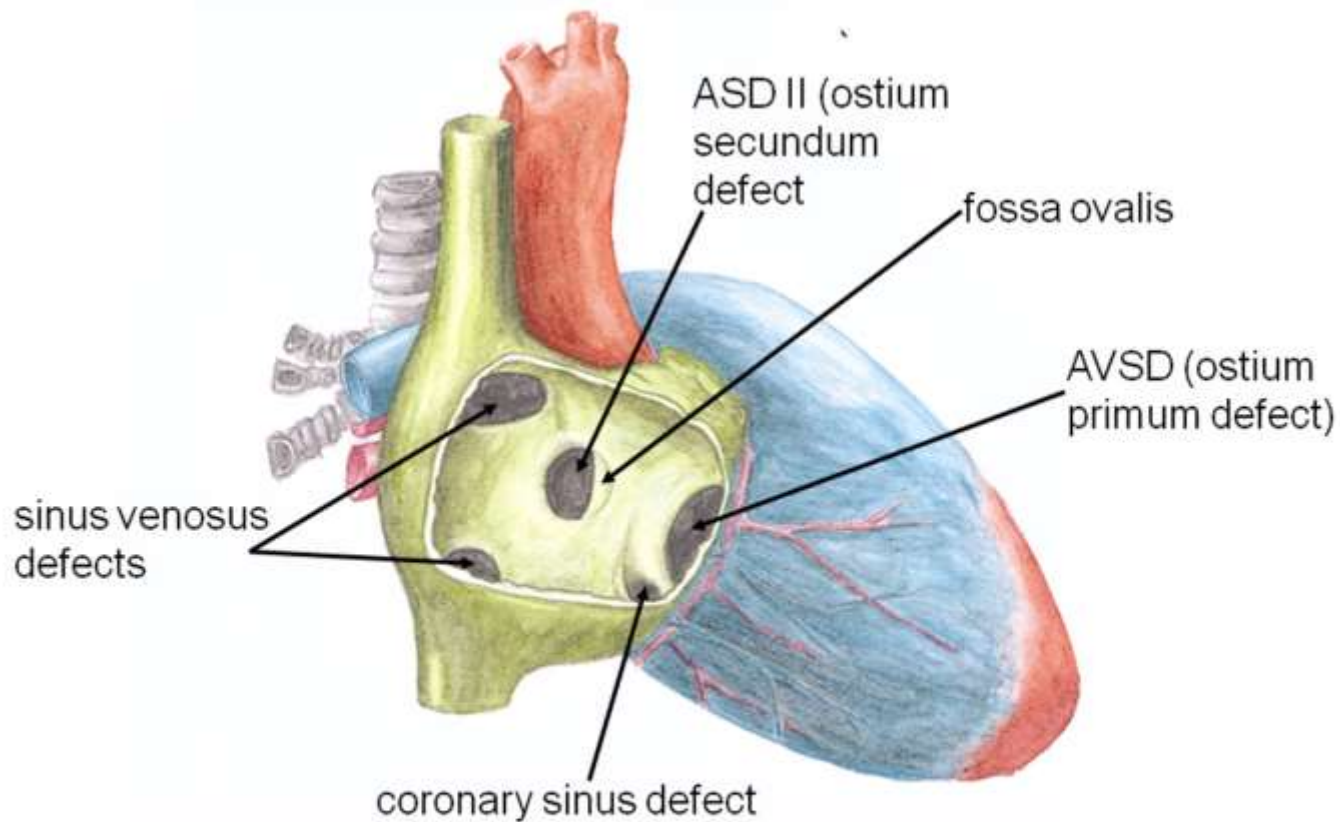
- **Pregnancy**
 - Generally well tolerated but
 - Extremely High risk (high mortality 30-50%):
 - Severe pulmonary art. hypertension (Eisenmenger sy)
 - High risk
 - Cyanosis (esp. SpO₂ <85%)
 - Stenotic left valve disease (AS, MS)
 - Poor EF LV (<40%)
 - NYHA II<
 - Aortic root dilation (Marfan sy)
 - Arrhythmias



Atrial septal defect

- Different anatomic types:
 - Secundum ASD (80% of ASDs; located in the region of the fossa ovalis and its surrounding)
 - Primum ASD (15%, synonym: partial atrioventricular septal defect (AVSD), located near the crux, AV valves are typically malformed resulting in various degrees of regurgitation (esp. Mitral))
 - Superior sinus venosus defect (5%, located near the superior vena cava (SVC) entry, associated with partial or complete connection of right pulmonary veins to SVC/right atrium (RA))
 - Inferior sinus venosus defect (1%, located near the inferior vena cava (IVC) entry)
 - Unroofed coronary sinus (1%, separation from the left atrium can be partially or completely missing)

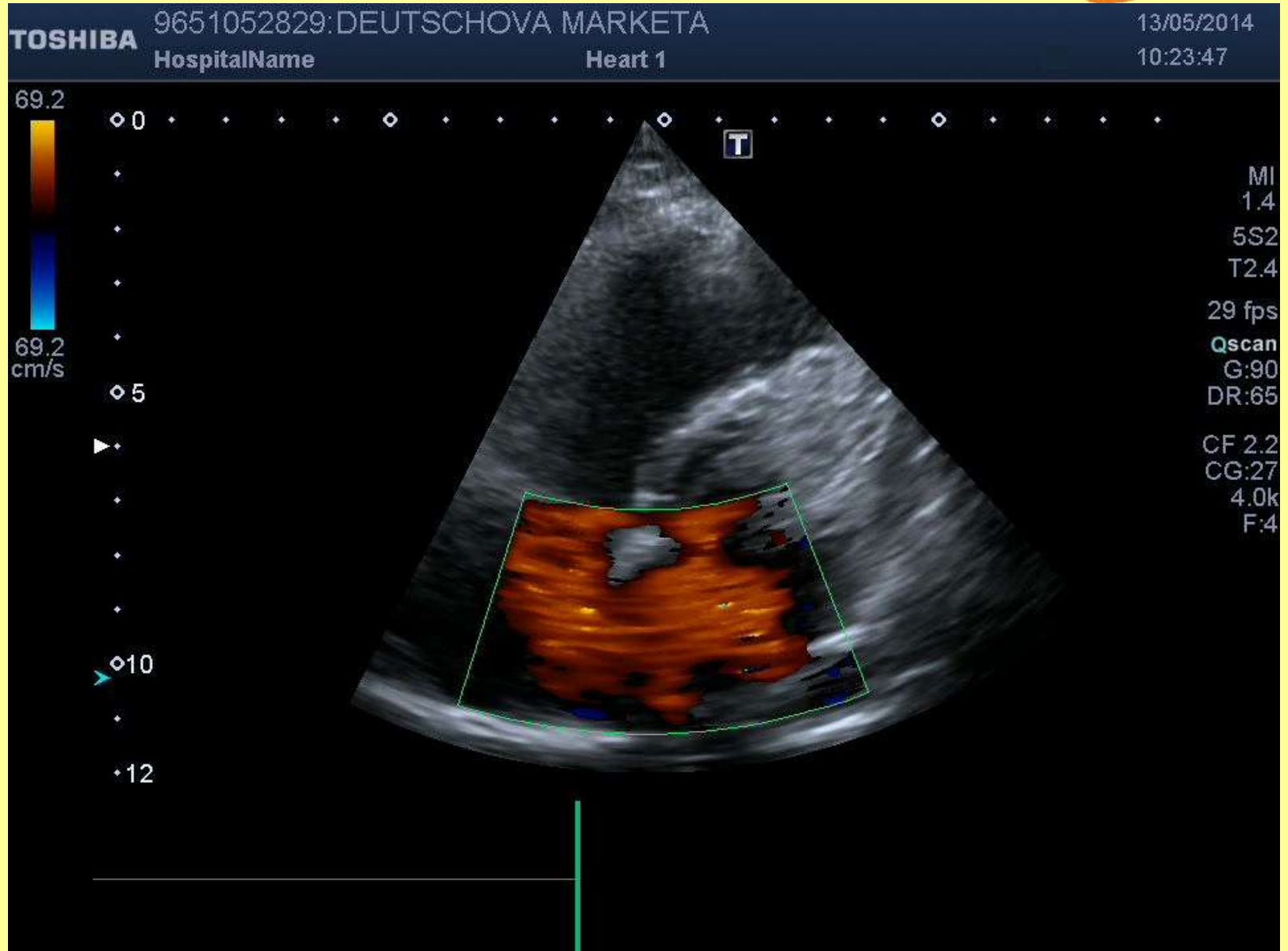
Atrial septal defect



Types of atrial septal defects with their locations



Atrial septal defect - echocardiography





2D echo assessment of ASD

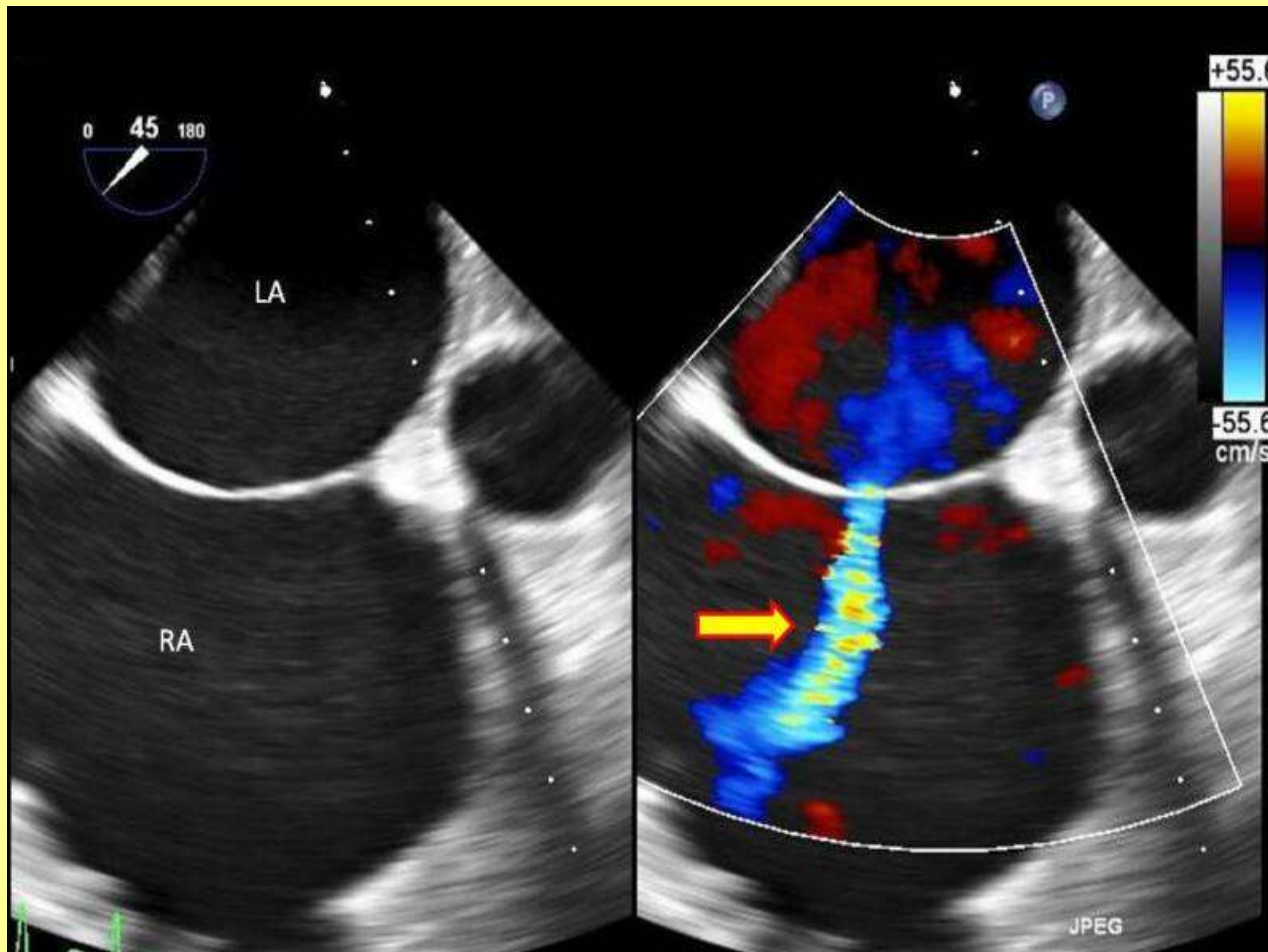
- . Position as well as size of the defect.
- .enlarged RA / RV and PAs
- . Associated abnormalities such as MVP , PS and Pulmonary venous return

Colour doppler can visualize

- .qualitative assessment of ASD
- .Quantitative assessment of systemic and pulmonary blood flow ratio Q_p / Q_s also made.



2D ASSESSMENT





Atrial septal defect - pathophysiology

- Naturally L to R shunt (higher BP in LA)
- Volume overloading of RV – dilation RA+RV
- Arrhythmias (Atrial fibrillation, flutter) (5th decade)
- Increase of transpulmonary flow – reactive higher pulmonary vascular resistance
- severe PAH (only in 5%) and bidirectional shunt (Eisenmenger physiology)
- Paradoxical embolism (thrombus from lower limb veins through ASD to systemic circulation e.g. CNS)



Atrial septal defect - diagnosing

- Symptoms – exertional shortness of breath, fatigue, palpitation
- Signs – fixed splitting of the second heart sound, systolic pulmonary flow murmur, ECG – iRBBB, right axis deviation

and/or

- Symptoms and signs connected with paradoxical embolism

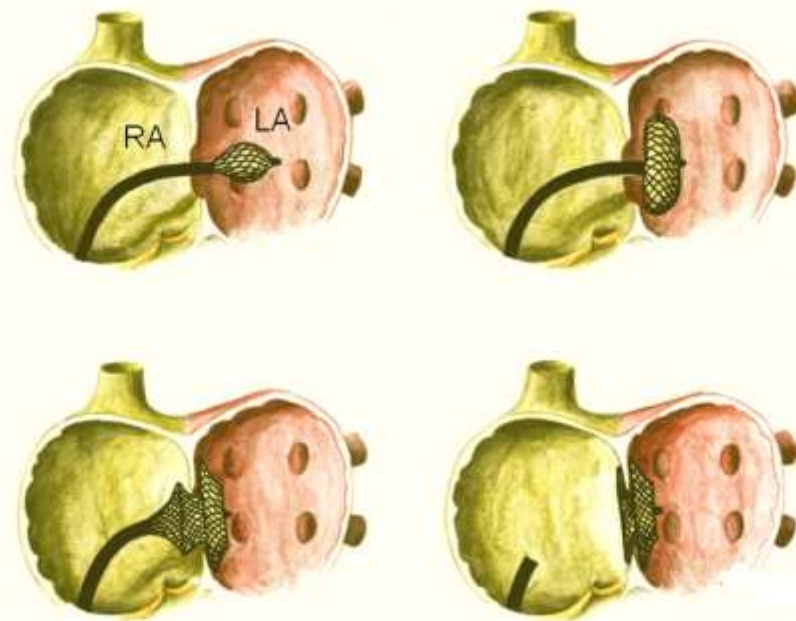



Atrial septal defect - treatment

- Surgical or Percutaneous closure
- Only significant defects:
 - Symptoms, Arrhythmias
 - Dilation of RV (volume overloading sign)
 - Significant shunt – $Q_p/Q_s > 1,5$
 - Paradoxical embolism
 - (Planned pregnancy) – prevention of paradoxical embolism
 - Eisenmenger sy (severe PAH with high pulmonary vascular resistance) – contraindication of closure

Atrial septal defect - treatment

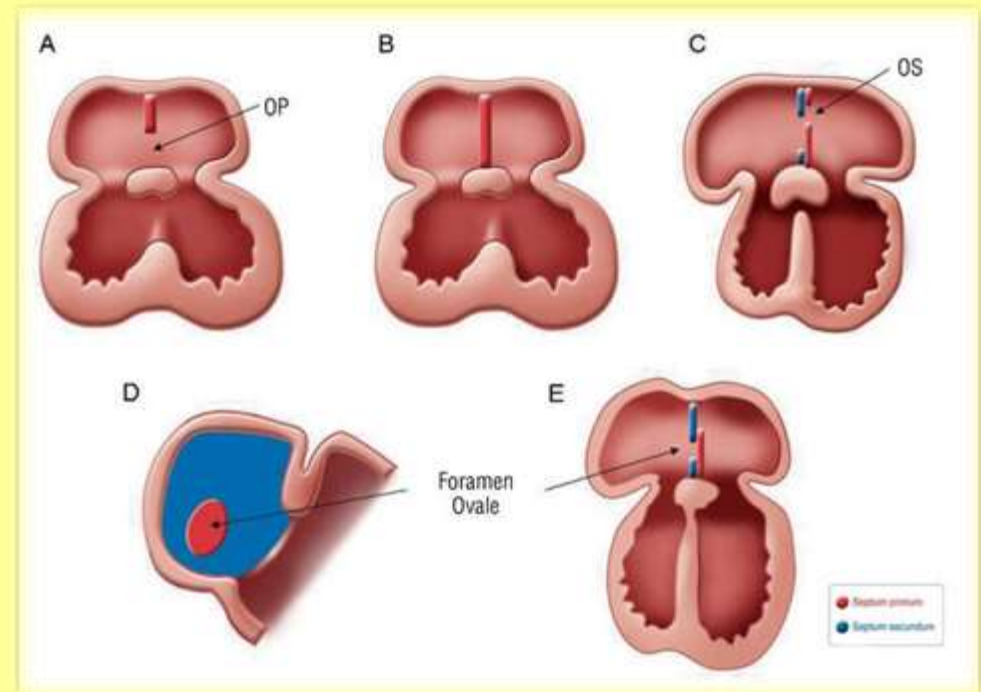
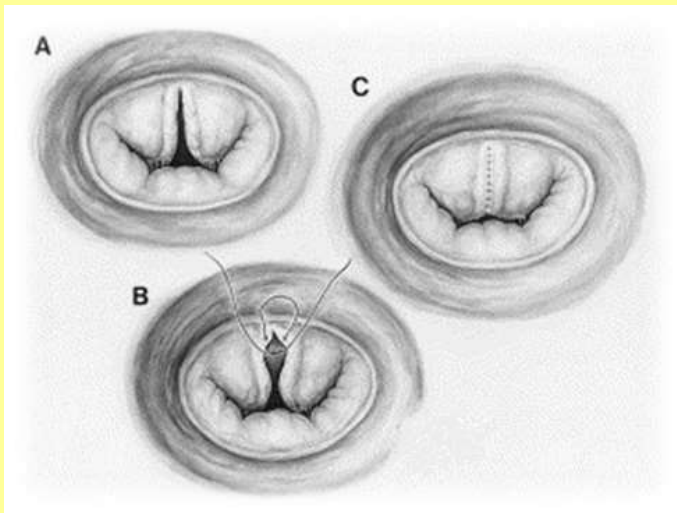
- ASD secundum – (if possible catheterisation device closure is prefer)



Closure of an atrial septal defect with an Amplatzer septal occluder

Atrial septal defect - treatment

- ASD primum – connected with cleft of anterior mitral leaflet with mitral regurgitation (mostly significant) - surgical treatment usually necessary

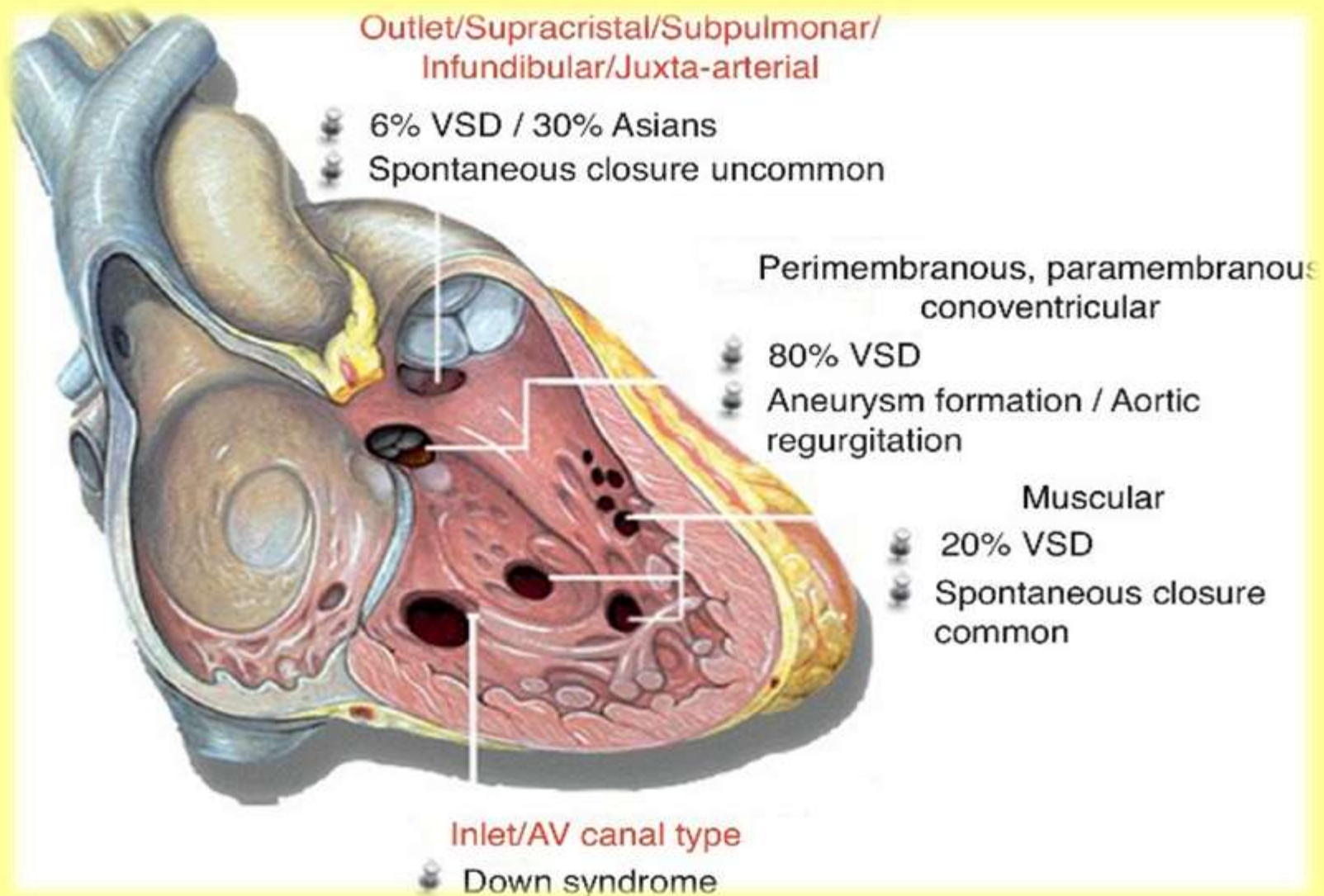




Atrial septal defect - treatment

- ASD sinus venosus superior – connected with partial anomalous pulmonary venous connection – PAPVC (mostly right upper pulmonary vein to RA) – L-R shunt
- Only surgical treatment
- Big ASD generally operated in childhood (3-5y)

Ventricular septal defect



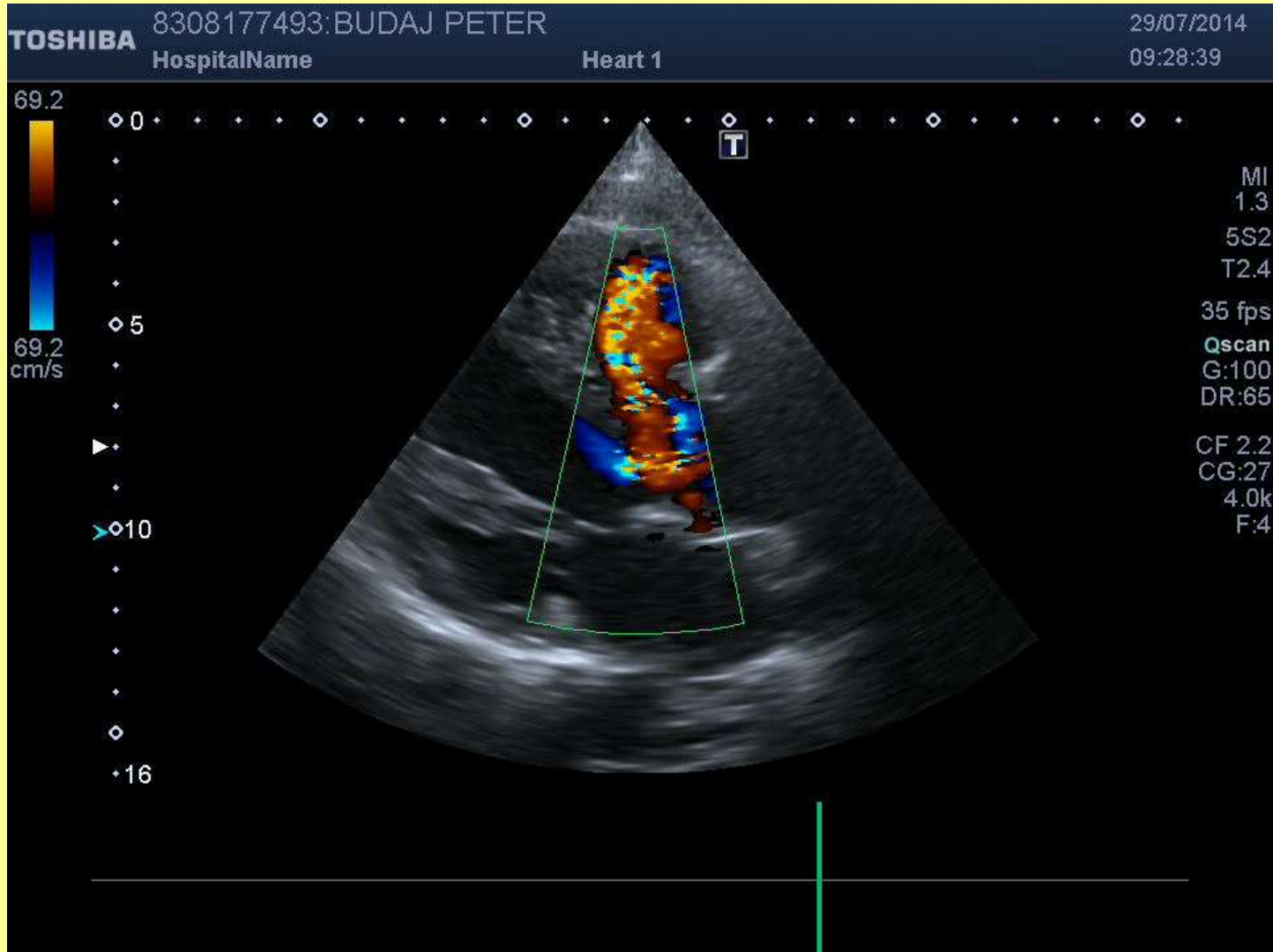


Ventricular septal defect - pathophysiology

- Naturally L to R shunt (much higher BP in LV)
- If significant defect:
 - Volume overloading of LV – dilation
 - Pressure overloading of RV – hypertrophy
 - Increase of transpulmonary flow and blood pressure in AP – reactive increase pulmonary vascular resistance
 - severe PAH and bidirectional shunt (Eisenmenger physiology) is developed early (within 1st year)
 - (Infants are operated in 3-5months)

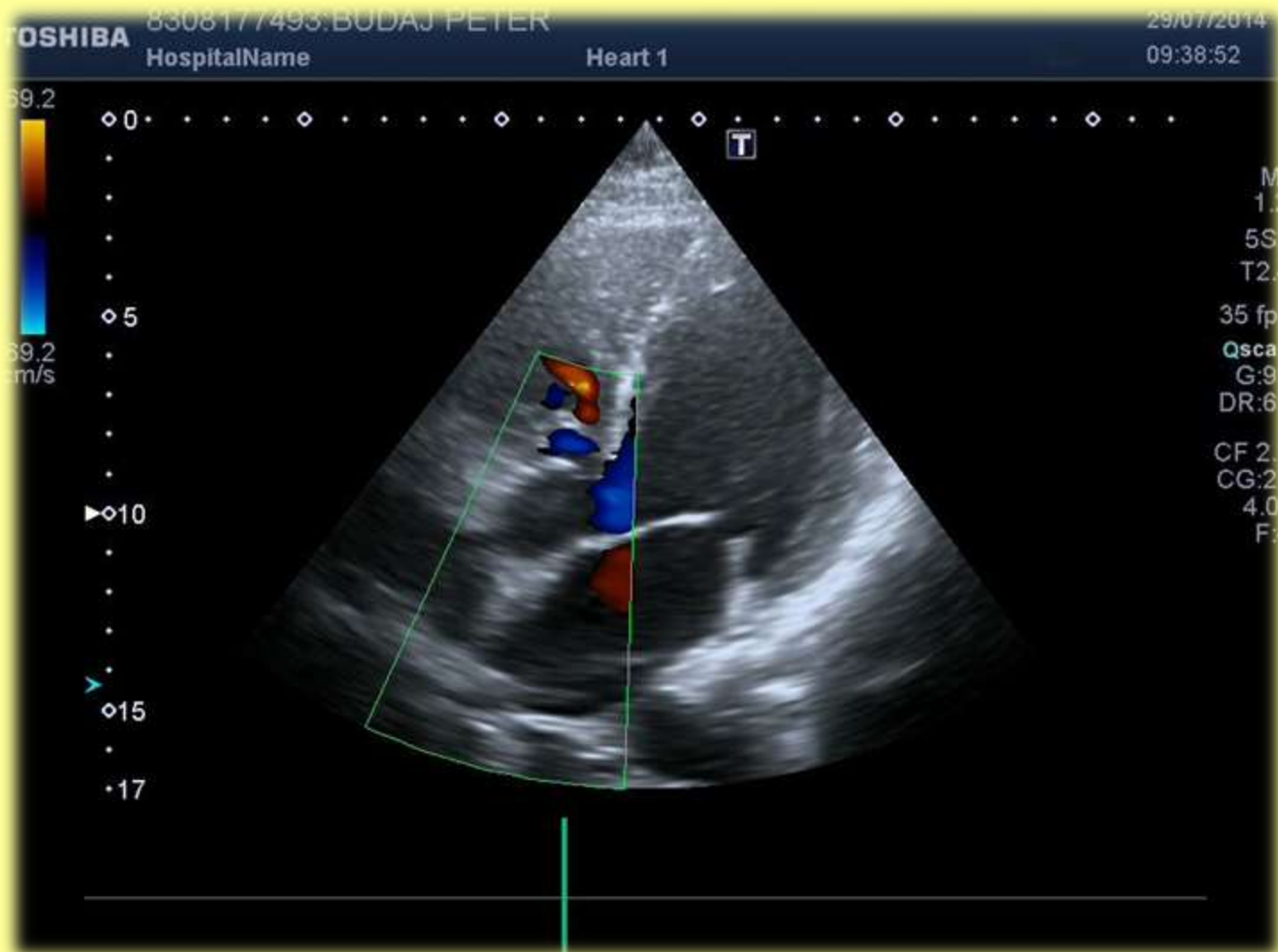


Ventricular septal defect - echocardiography





Ventricular septal defect - echocardiography





Ventricular septal defect - treatment

- Insignificant (restrictive) defect (with loud systolic murmur and high pressure gradient)
 - Conservative, only observation, IE prophylaxis
- Significant (unrestrictive) – (prefer) surgical closure
 - Symptoms
 - Signs of LV volume overloading (dilation)
 - History of IE
 - Significant shunt ($Q_p/Q_s > 1,5$) and no severe PAH and vascular resistance
 - Progressive Aortic regurgitation due to prolapse of aortic valve cusp (suck to defect)



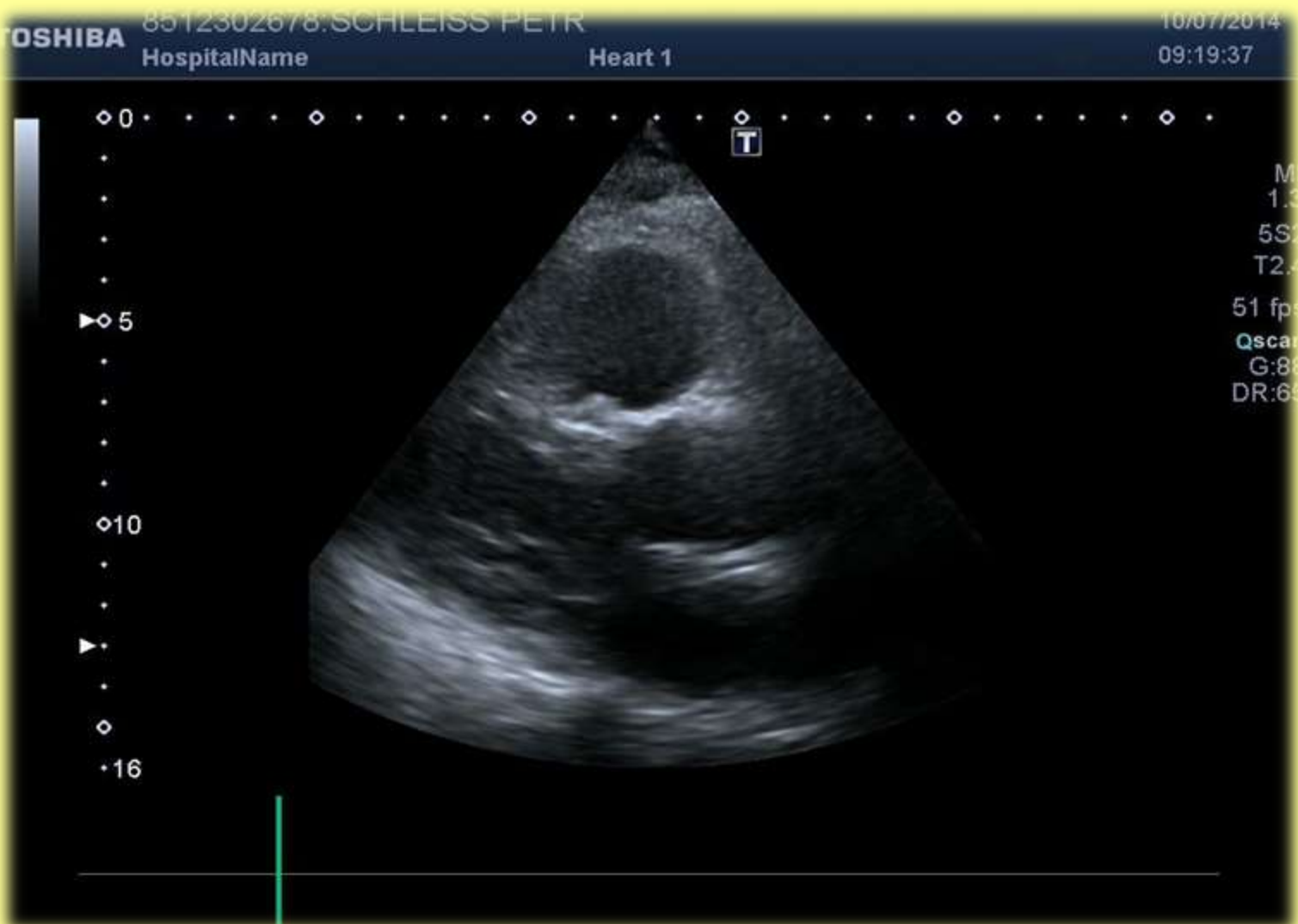
Tetralogy of Fallot

1. non-restrictive VSD
2. overriding aorta (but <50%)
3. RVOTO which may be infundibular, valvular, or (usually) a combination of both, with or without supra-valvular or branch PA stenosis
4. RV hypertrophy

- 10% of CHD
- Surgical treatment – VSD closure + relief of RVOTO (with resection of the infundibulum and pulmonary valvotomy)
- Common complication in adulthood (after repair) :
 - Pulmonary regurgitation, Residual RVOTO, Aortic root dilation with valve regurgitation, RV dilation and dysfunction, Residual VSD
 - All patients should be followed-up in specialized GUCH centers

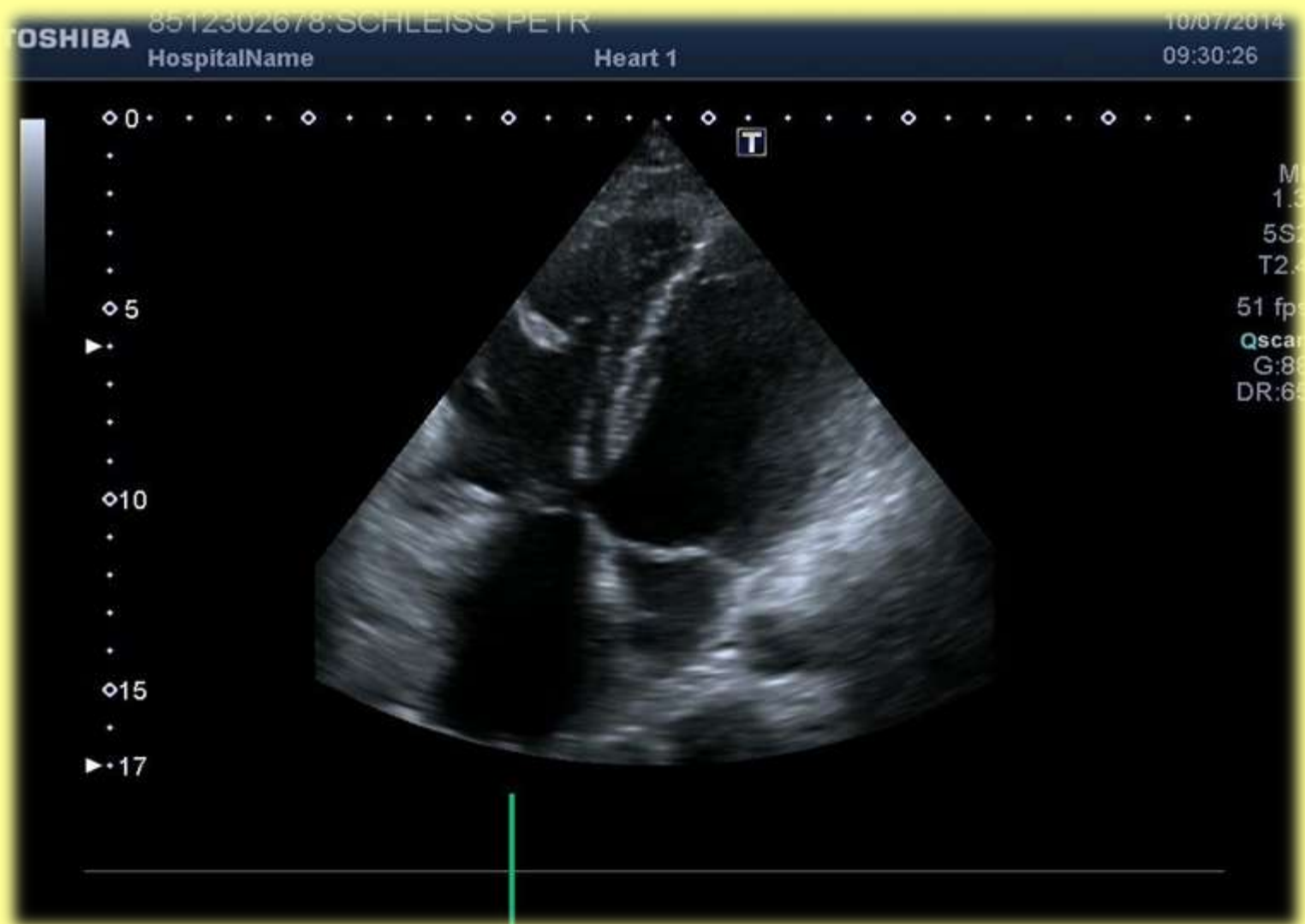

Tetralogy of Fallot after repair





Tetralogy of Fallot after repair





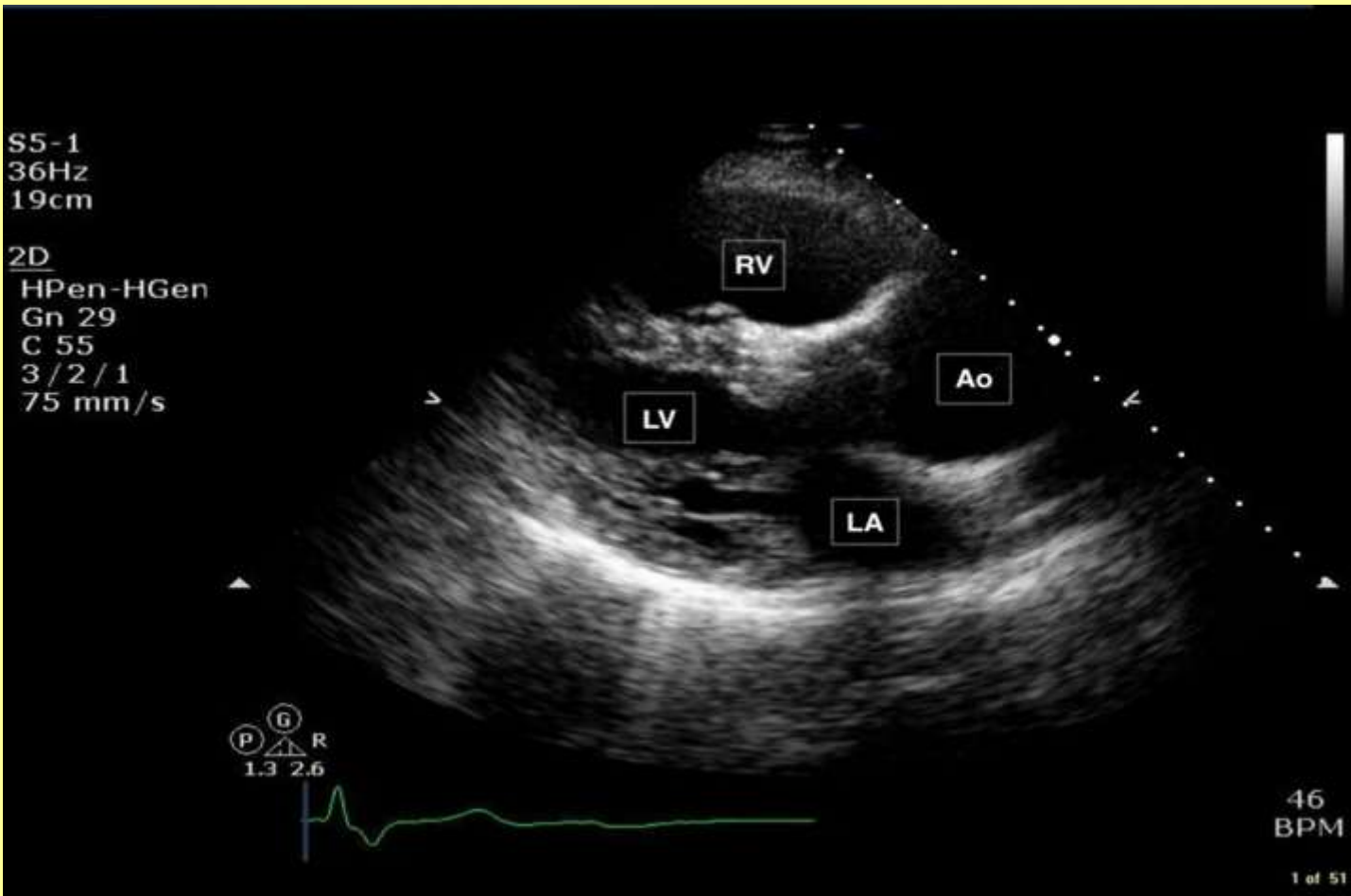
echo assessment :

- 2D echo and doppler can assess the quantitative study of TOF severity
- A large perimembraneous infundibular VSD and overriding of aorta are readily imaged in PLAX view
- The RVOT , PV and pulmonary annulus and MPA are visualized in PSAX and subcostal short axis view.



- doppler study estimate the pressure gradient across RVOT obstruction.
- Anomalous of coronary artery distribution can be imaged accurately
- major concern is to ruleout any branches of coronary arteries crossing the RVOT
- associated anomalous such as ASD and LSVC
Left superior venacava can be imaged.

RVH AND OVERRIDING OF AORTA

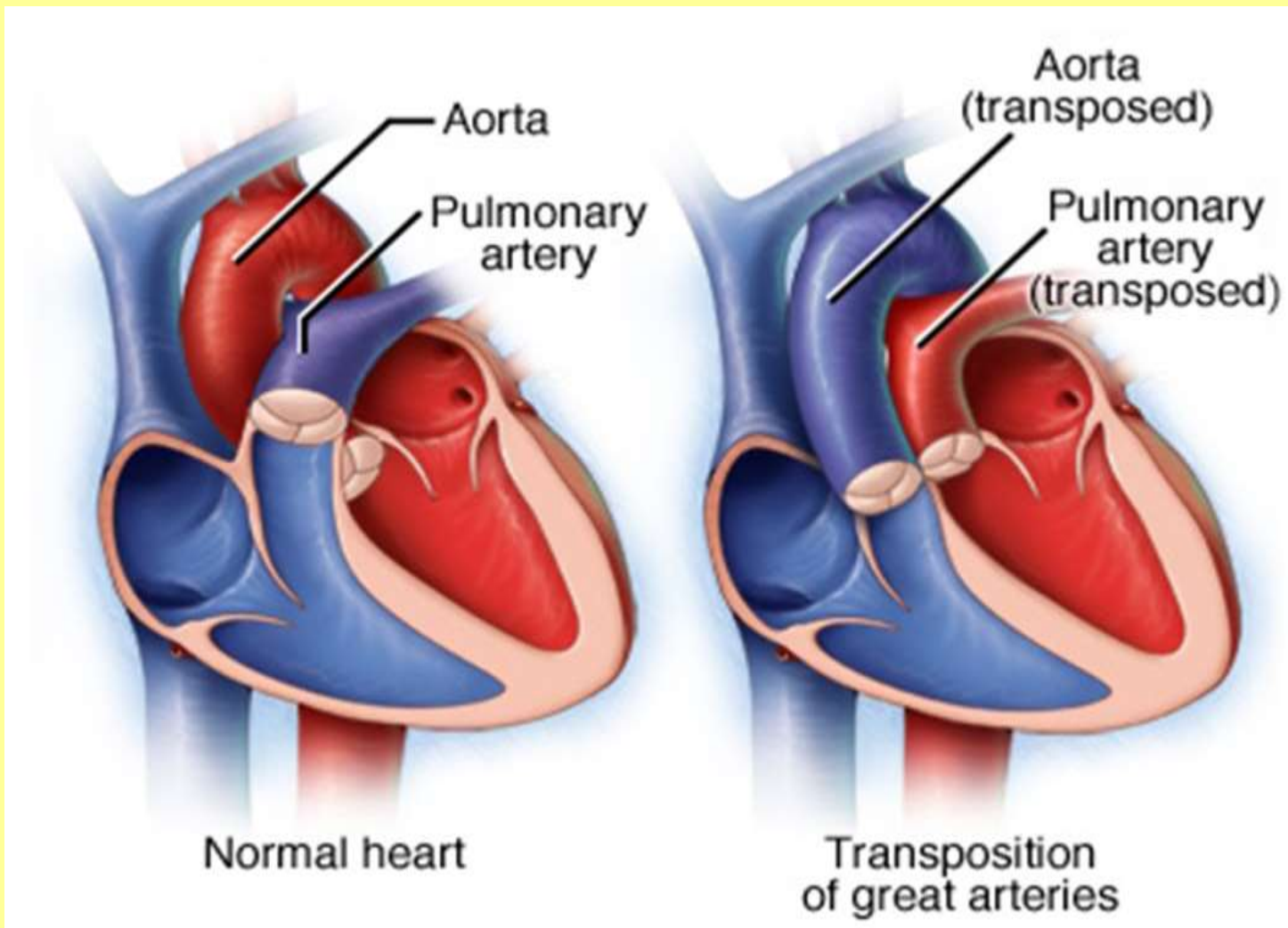




Transposition of the Great Arteries (TGA)

- Counts ~ 5% of CHD
- Ventriculo-arterial discordance + (Atrio-ventricular concordance)
- 45% Complex TGA – TGA + VSD (45%), LVOTO (25%), CoA (5%)
- Male predominance 2:1
- Simple TGA is critical CHD (incompatible with life without shunts) – repair in early newborn age
 - 1st degree – palliative atrioseptostomy (Rashkind procedure)
 - 2nd degree – definitive repair

Transposition of the Great Arteries (TGA)



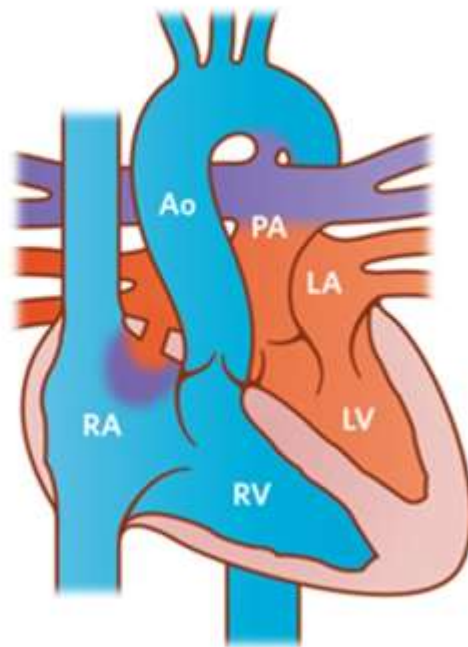


Transposition of the Great Arteries (TGA)

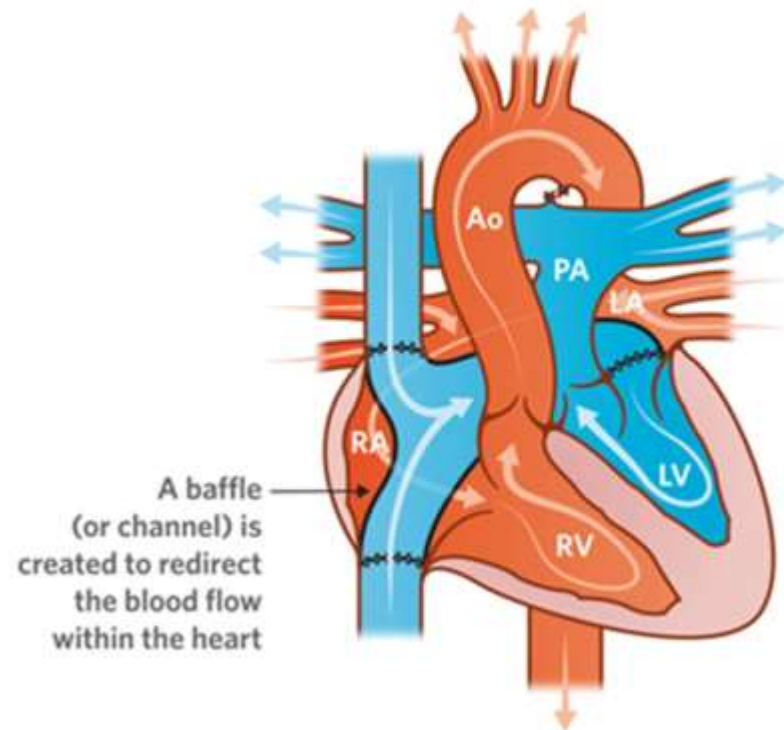
- 2 types of repair:
 - **Atrial switch** (Senning or Mustard procedure)
 - Older type of repair - developed and first performed by Senning in 1957, method of first choice till the turn of the 80s and 90s
 - Creation of atrial baffle/conduit channeling blood from the superior and inferior vena cava towards the mitral valve (LV) and blood from pulmonary veins towards tricuspid valve (RV)
 - (anatomically) RV is in systemic position!

Transposition of the Great Arteries (TGA)

Surgery for transposition of the great arteries — Senning operation



Pre surgical anatomy



A baffle
(or channel)
is created to
redirect
the blood flow
within the heart

After Senning procedure

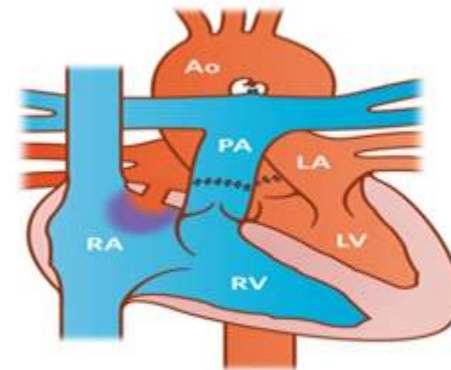
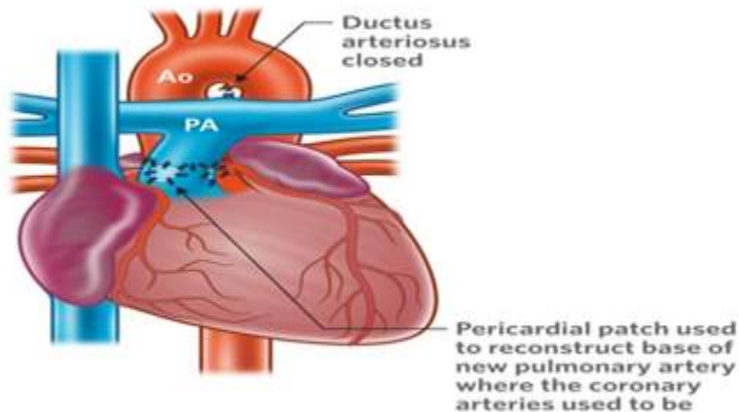
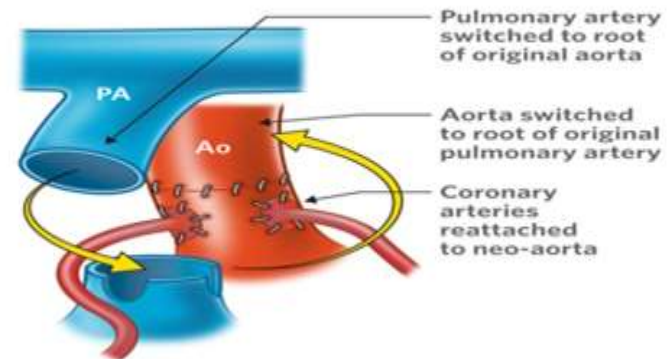
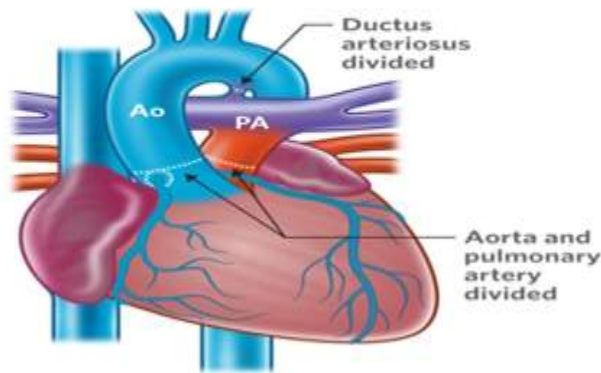


Transposition of the Great Arteries (TGA)

- 2 types of repair:
 - **Arterial switch** (Jatene procedure)
 - Newer type of repair - developed and first performed by Jatene in 1975 (in common practice since 90s)
 - Change (reimplantation) of great arteries to corresponding ventricles, coronary arteries also reimplanted to “neoaorta”
 - Result of this procedure – physiological circulation

Transposition of the Great Arteries (TGA)

Surgery for transposition of the great arteries — Arterial switch



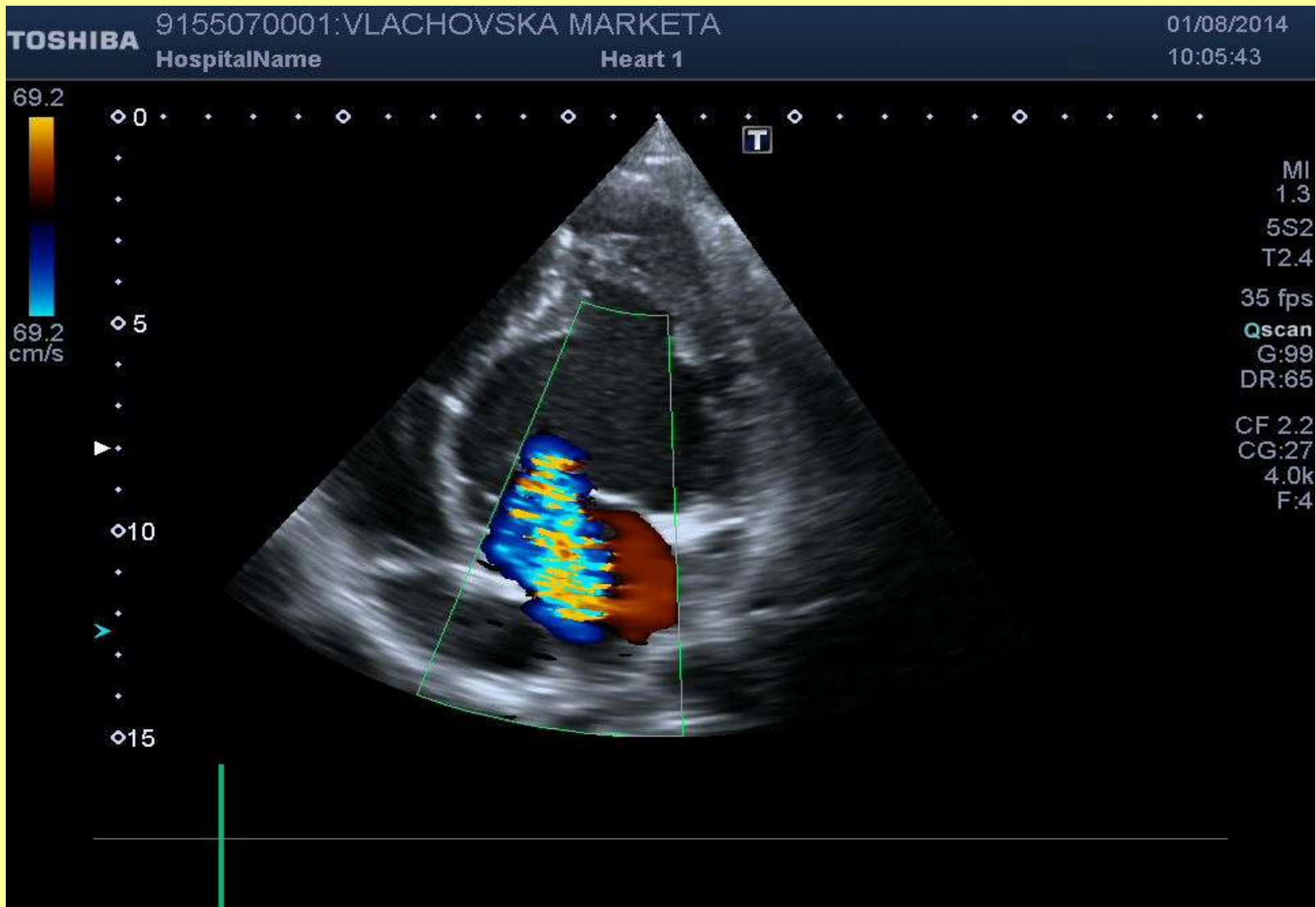


Transposition of the Great Arteries (TGA)

- Complications after Atrial switch:
 - RV failure (progressive dilation, dysfunction)
 - TV regurgitation
 - Sinus node dysfunction (symptomatic bradycardia)
 - Tachyarrhythmias (SVT – AF, VT with risk of sudden death)
 - Intra-atrial tunnel stenosis (systemic vein or pulmonary vein with corresponding symptoms)
- Progressive heart failure is the most severe complication requiring Heart Tx



TGA after Senning procedure





Transposition of the Great Arteries (TGA)

- Complications after Arterial switch:
 - Coronary artery stenosis (after reimplantation) with LV ischemia – systolic dysfunction, ventricular arrhythmias
 - Dilation of ascending aorta with AR
 - Pulmonary stenosis (supravalvular and branches)
- Large majority of pts. after arterial switch are long term without complication

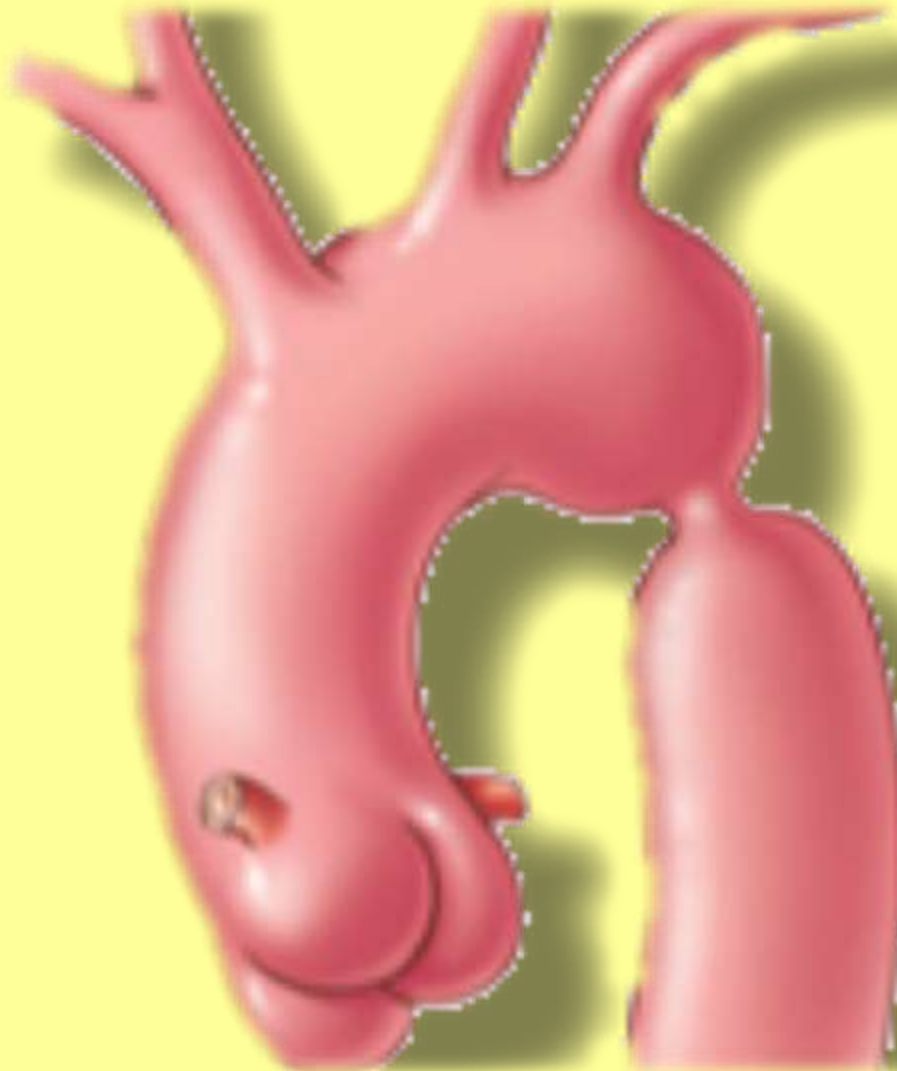


Coarctation of Aorta (CoA)

- Accounts 5-8% of CHD
- Circumscript narrowing typically located in the area where the ductus arteriosus inserts (rare occurs ectopically (asc., desc., abd.)
- Often associated with:
 - Bicuspid aortic valve (85%), subvalvular, valvular, or supravalvular AS, mitral valve stenosis or complex congenital heart defects, Turner sy



Coarctation of Aorta





Coarctation of Aorta - pathophysiology

- Narrowing causes significant afterload on the LV, resulting in increased wall stress, compensatory LVH, LV dysfunction, and the development of arterial collaterals
- Fibrosis in the ascending and descending aorta, resulting in an increased stiffness of the aorta and carotid arteries
- Accelerated atherosclerosis in part circulation in front of stenosis with higher pressure (including coronary arteries)



Coarctation of Aorta - diagnosing

- Mild forms detected in adulthood
- Symptoms:
 - headache, nosebleeds, dizziness, tinnitus, shortness of breath, abdominal angina, leg claudication, exertional leg fatigue, and cold feet
- Signs:
 - upper body systolic hypertension, lower body hypotension, **a blood pressure gradient (20 mmHg) is significant CoA**
 - radio-femoral pulse delay
 - suprasternal thrill, **vascular murmur in the back**, or continuous murmurs (due to collateral vessels).
 - chest X-ray findings may include rib notching of the third and fourth ribs from collaterals, ectatic ascending aorta, kinking or double contouring in the descending aorta ('figure 3' sign), widening of the left subclavian artery



Coarctation of Aorta - treatment

- Surgery (end-to-end anastomosis, resection and extended end-to-end anastomosis, prosthetic patch aortoplasty, subclavian flap aortoplasty, interposition of (tube) graft, and bypass tube (jump) grafts)
 - usually in native CoA in childhood and in adults if anatomy is not attractive for angioplasty

X

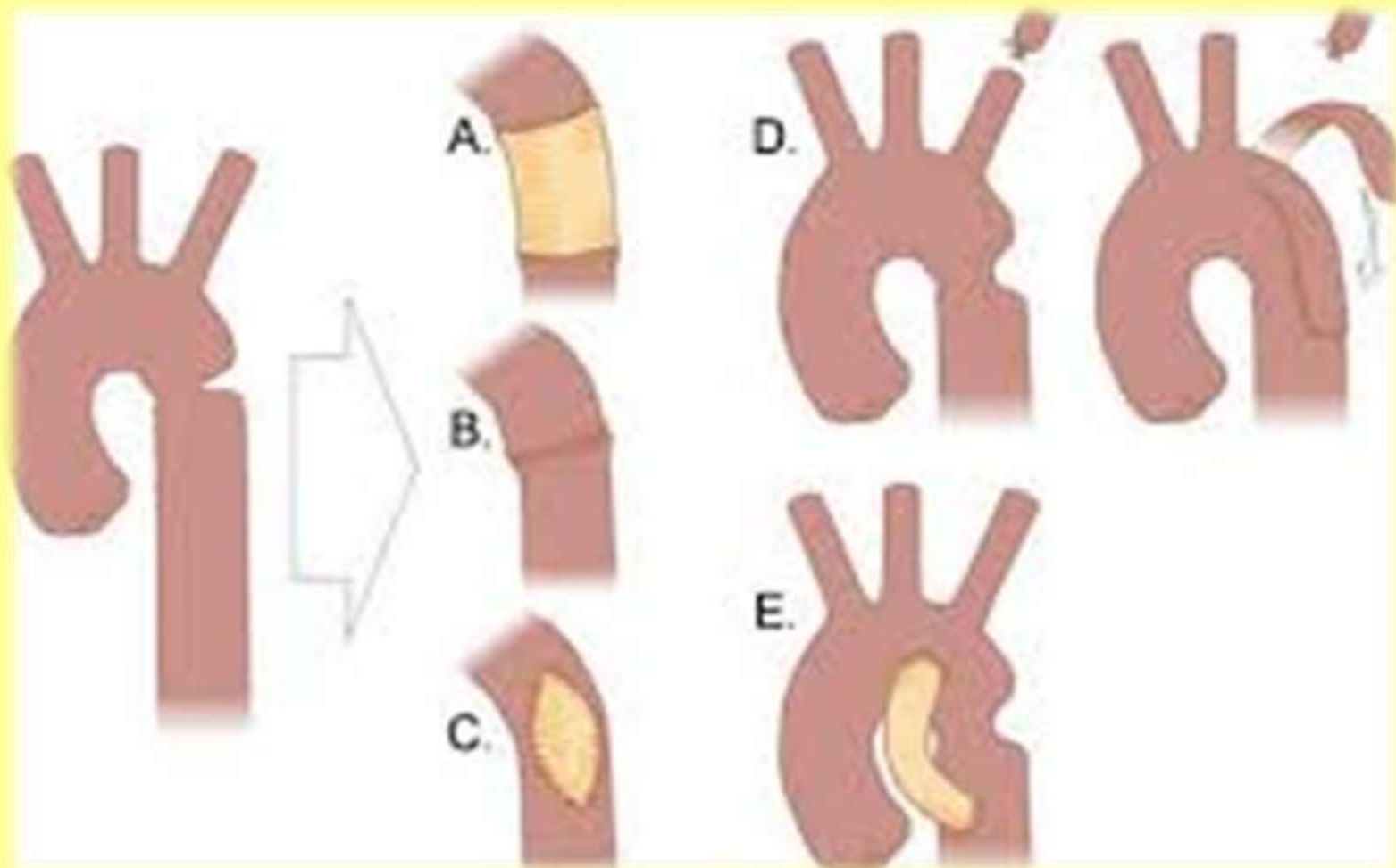
- Catheterization (angioplasty with or without stent)
- – if anatomy convenient, more often used in reCoA after surgery



Coarctation of Aorta – indication for intervention

- non-invasive pressure difference >20 mmHg between upper and lower limbs
- upper limb hypertension (>140/90 mmHg in adults)
- pathological blood pressure response during exercise
- significant LVH
- patients with ≥50% aortic narrowing relative to the aortic diameter at the diaphragm level (on cMRI, CT, or invasive angiography)

Coarctation of Aorta - surgery





Other rarer CHDs

(for interested of you - next time)

- Univentricular Heart (with Fontan circulation)
- Pulmonary atresia (with or without VSD)
- Ebstein's anomaly of tricuspid valve
- Eisenmenger sy (reactive severe and irreversible pulmonary hypertension)
- ...



THANK YOU