



SNS COLLEGE OF ALLIED HEALTH SCIENCES
SNS Kalvi Nagar, Coimbatore - 35
Affiliated to Dr MGR Medical University, Chennai



DEPARTMENT OF CARDIO PULMONARY PERFUSION CARE
TECHNOLOGY

COURSE NAME : PRINCIPLES OF PERFUSION TECHNOLOGY

II YEAR

PATHOLOGY OF HEART

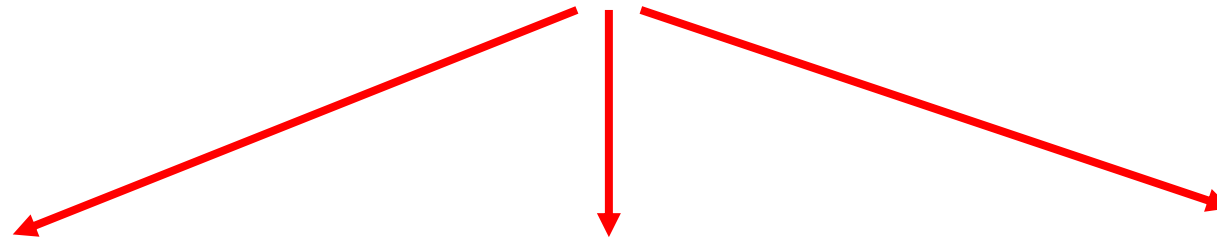
TOPIC : CONGENITAL HEART DISEASES (R TO L SHUNT)



Right – to – Left Shunts (Cyanotic Group)



Right to left shunt cyanotic heart disease includes,



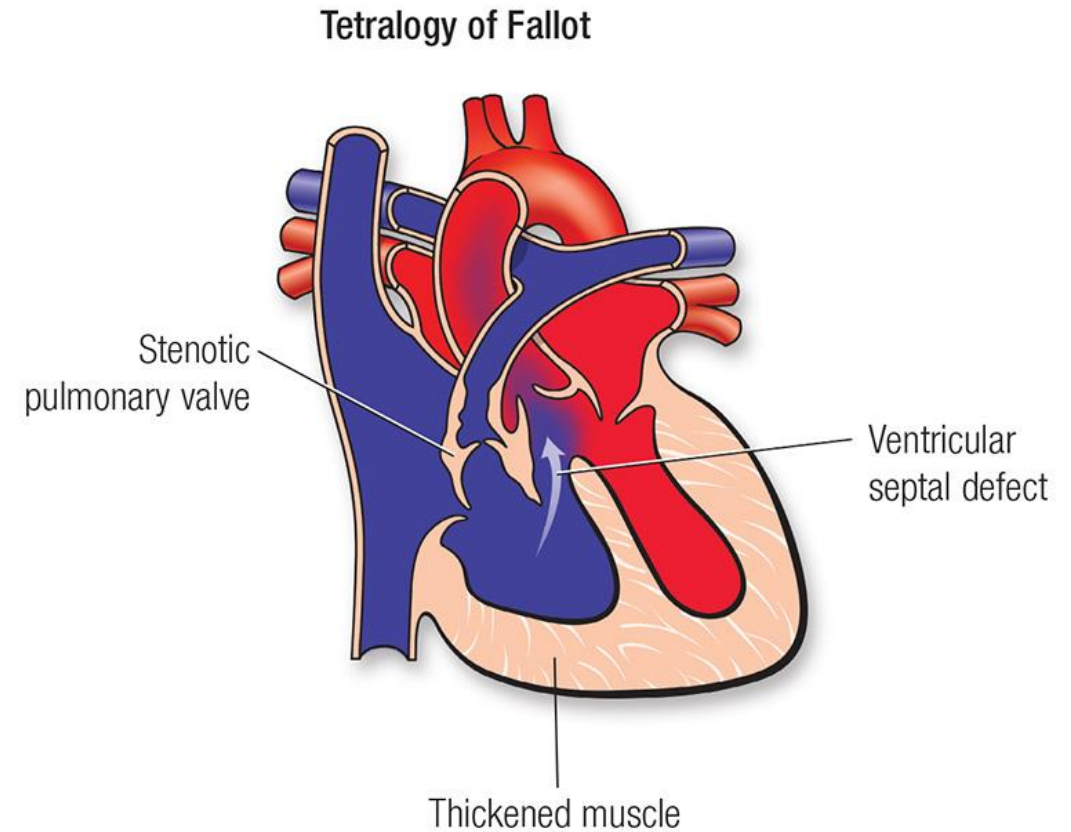
Tetralogy of Fallot

Transposition of Great Vessels

Truncus Arteriosus

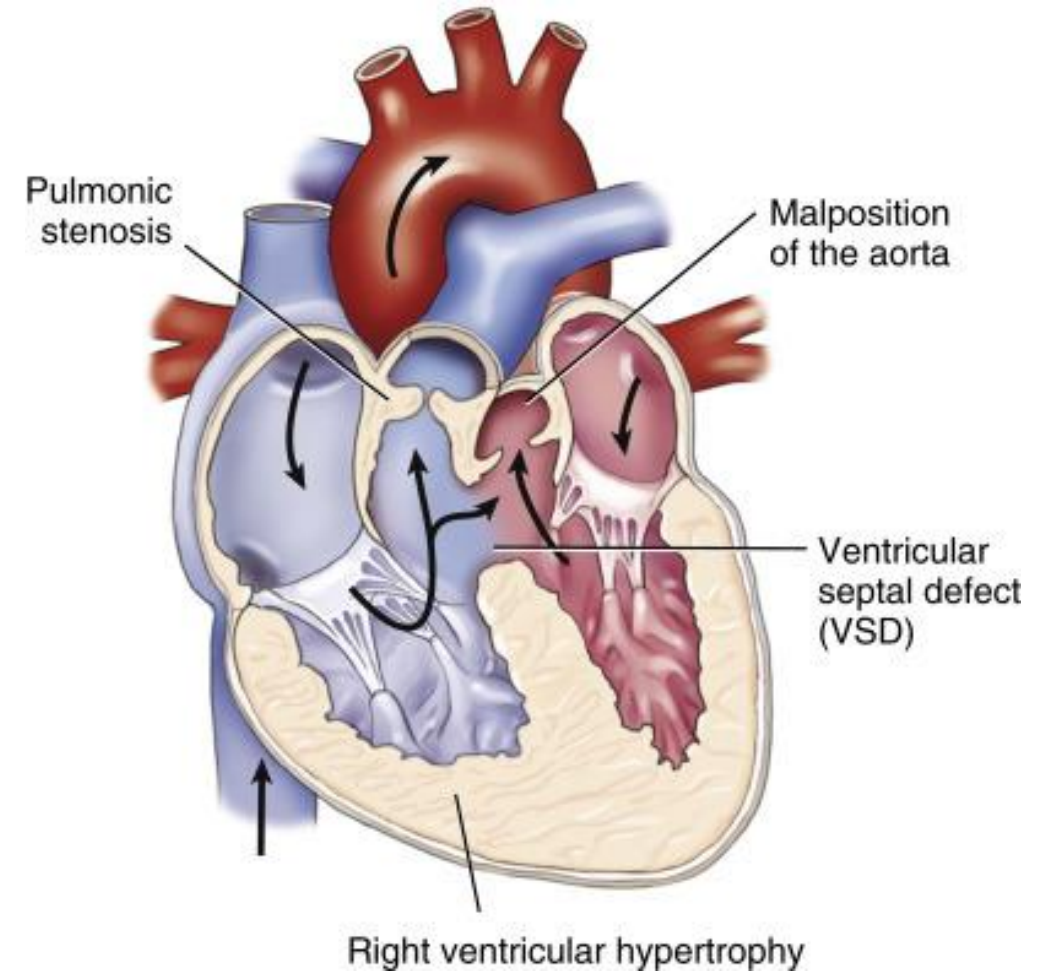
Tetralogy of Fallot

Tetralogy of Fallot is the most common cyanotic congenital heart disease, found in about 10% of children with anomalies of the heart.



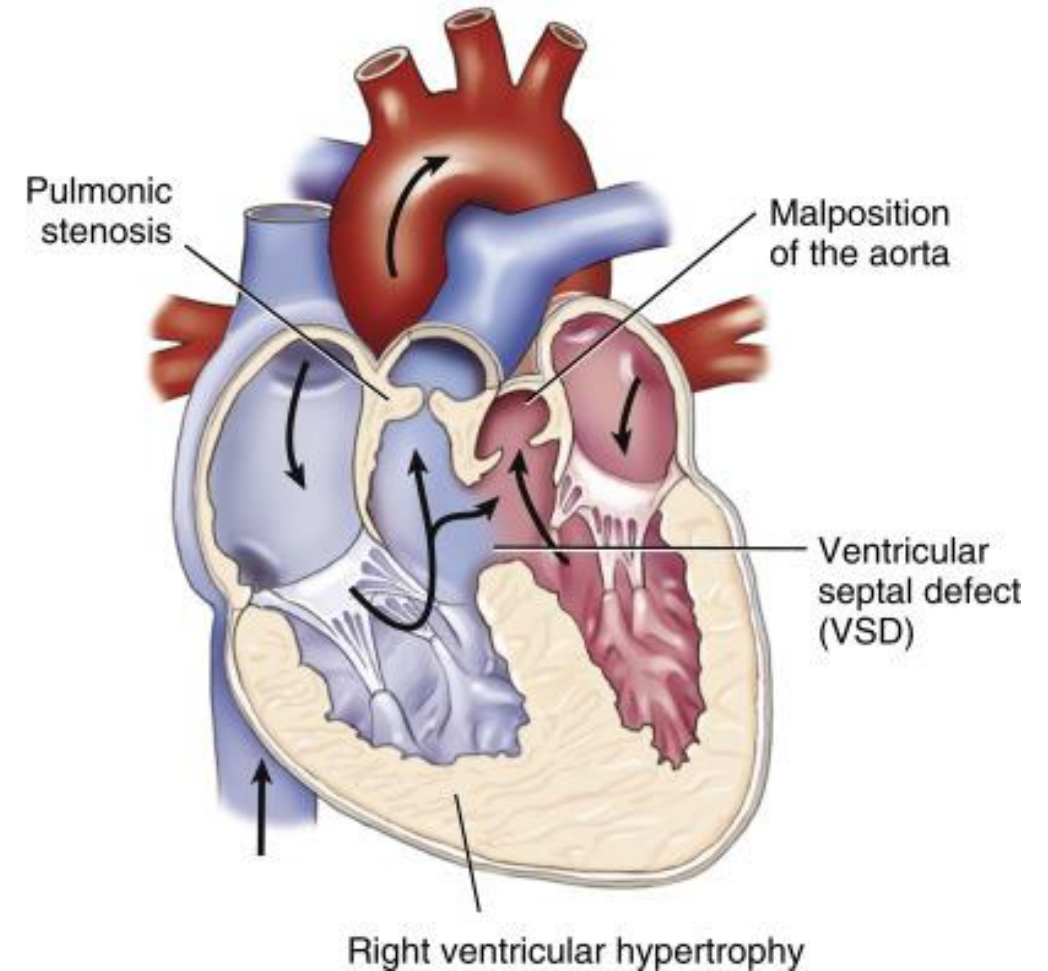
Features of TOF

- Ventricular septal defect (VSD) (*'shunt'*)
- Displacement of the aorta to right so that it overrides the VSD.
- Pulmonary stenosis (*'obstruction'*)
- Right ventricular hypertrophy



Features of TOF

- The aorta arises from the right ventricle and the pulmonic trunk from the left ventricle a VSD, or ASD with PDA, is needed for extrauterine survival.
- The blood flow is from right ventricle to aorta and left ventricle to pulmonary artery
- There is right-to-left shunting





Forms of TOF

There are two forms of tetralogy: cyanotic and acyanotic:

Cyanotic tetralogy - **Pulmonary stenosis** is greater and the VSD is mild.



More resistance to the outflow



Right-to-left shunt



Acyanotic tetralogy - The **VSD** is larger and pulmonary stenosis is mild.



Forms of TOF

Acyanotic tetralogy - The **VSD** is larger and pulmonary stenosis is mild.



Increased pulmonary flow and increased volume in the left heart



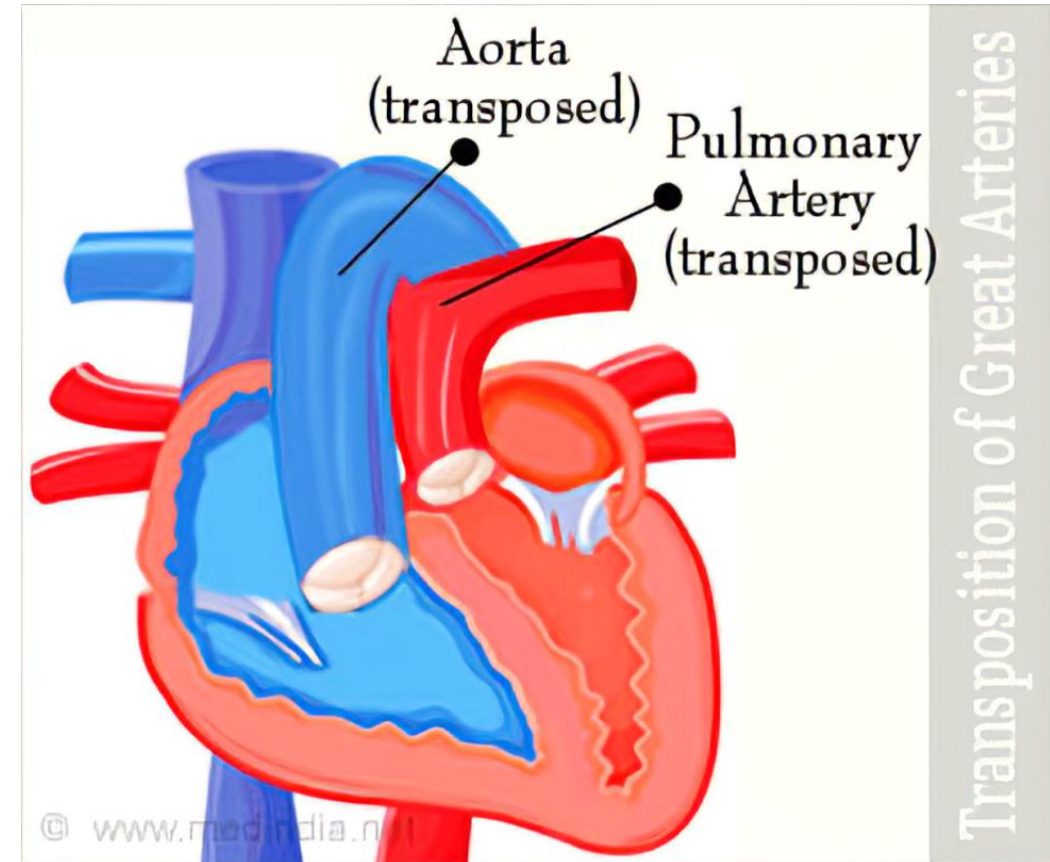
No cyanosis



Left-to-right shunt

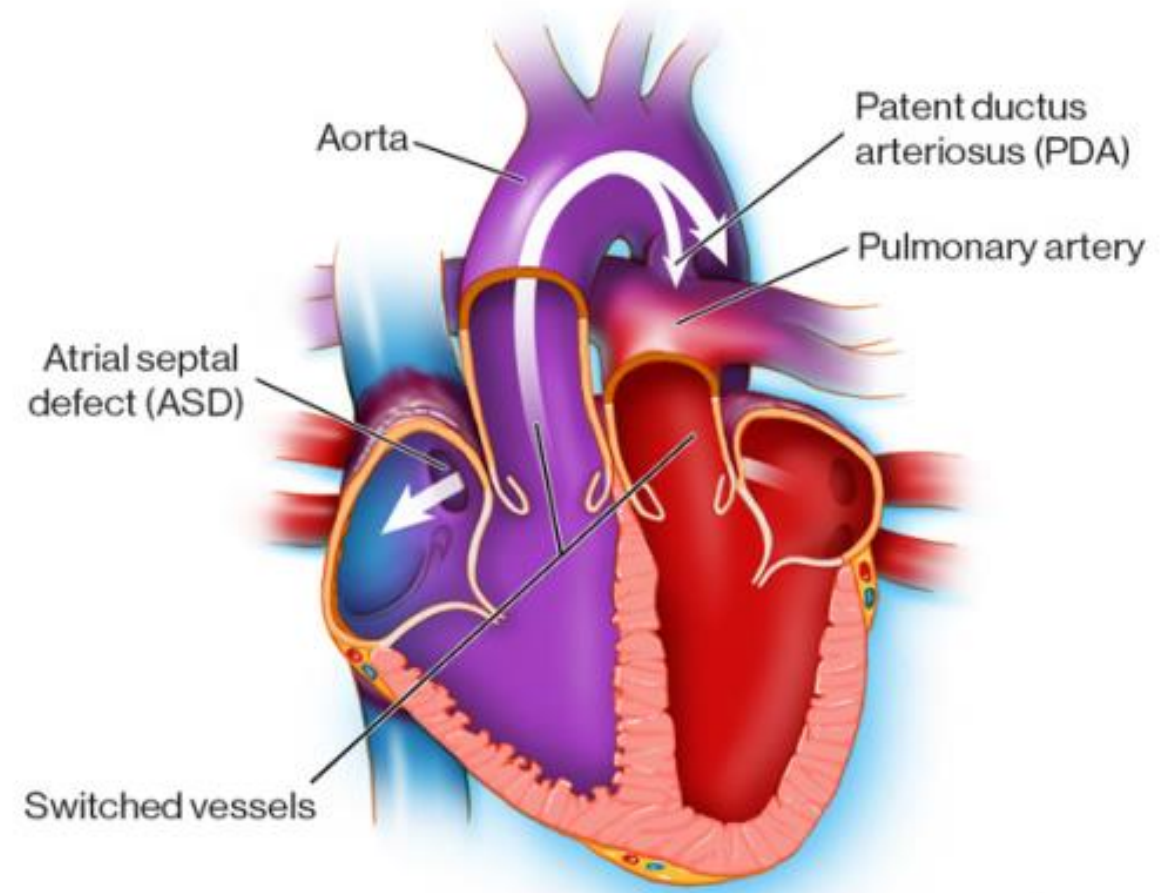
Transposition of Great Arteries (TGA)

- The term transposition is used for complex malformations
- Position of aorta, pulmonary trunk, atrioventricular orifices
- Left ventricle a VSD, or ASD with PDA, is needed for extrauterine survival.



Forms of TGA

- **Regular transposition** is the most common type, the aorta is anteriorly placed
- In regular complete transposition, the aorta emerges from the right ventricle and the pulmonary trunk from the left ventricle so that there is cyanosis from birth.





Forms of TGA



- **Corrected transposition** is an uncommon anomaly.
- There is **complete transposition of the great arteries** with aorta arising from the right ventricle and the pulmonary trunk from the left ventricle, as well as transposition of the great veins so that the pulmonary veins enter the right atrium and the systemic veins drain into the left atrium.
- This results in a **physiologically corrected circulation**

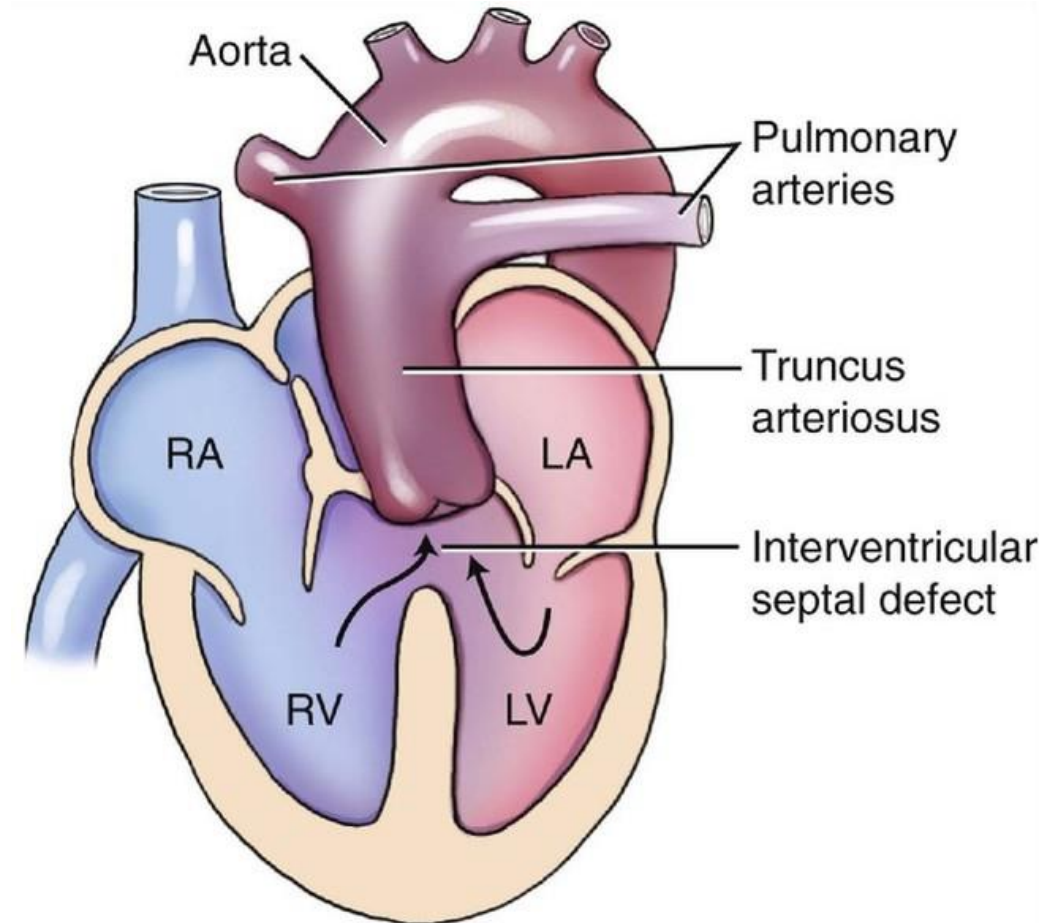
Persistent Truncus Arteriosus (PTA)

- It's a rare anomaly
- The arch that normally separates the aorta from the pulmonary artery fails to develop.



Single large common vessel

- The orifice may have 3 to 6 cusps
- There is often an associated VSD, this leads to poor prognosis

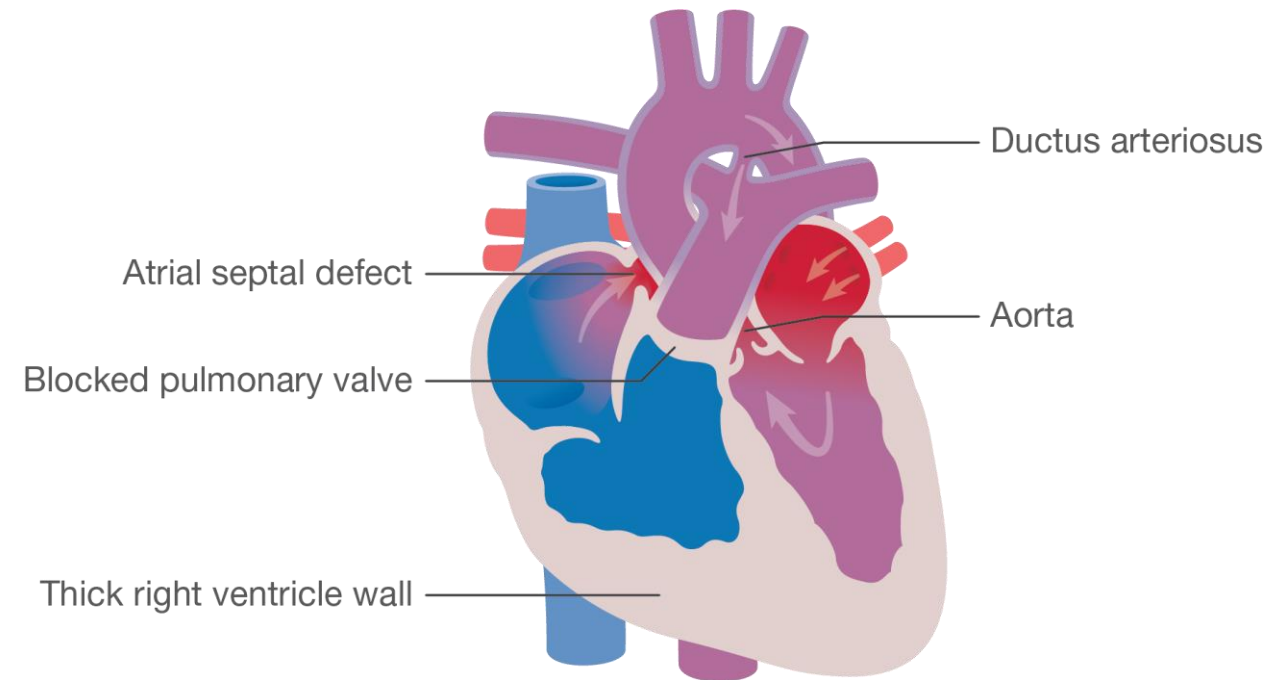




Pulmonary Stenosis / Atresia with Intact Ventricular Septum



- Obstruction at the pulmonary valve.
- When the valve is entirely atretic, the anomaly is commonly associated with a hypoplastic right ventricle and an ASD.

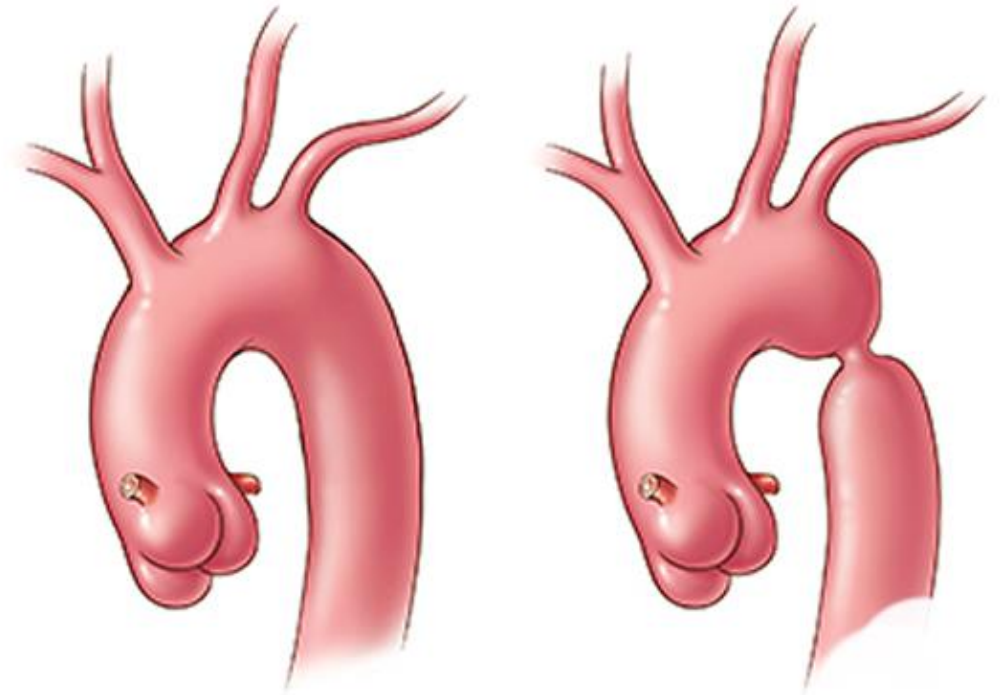




Coarctation of Aorta

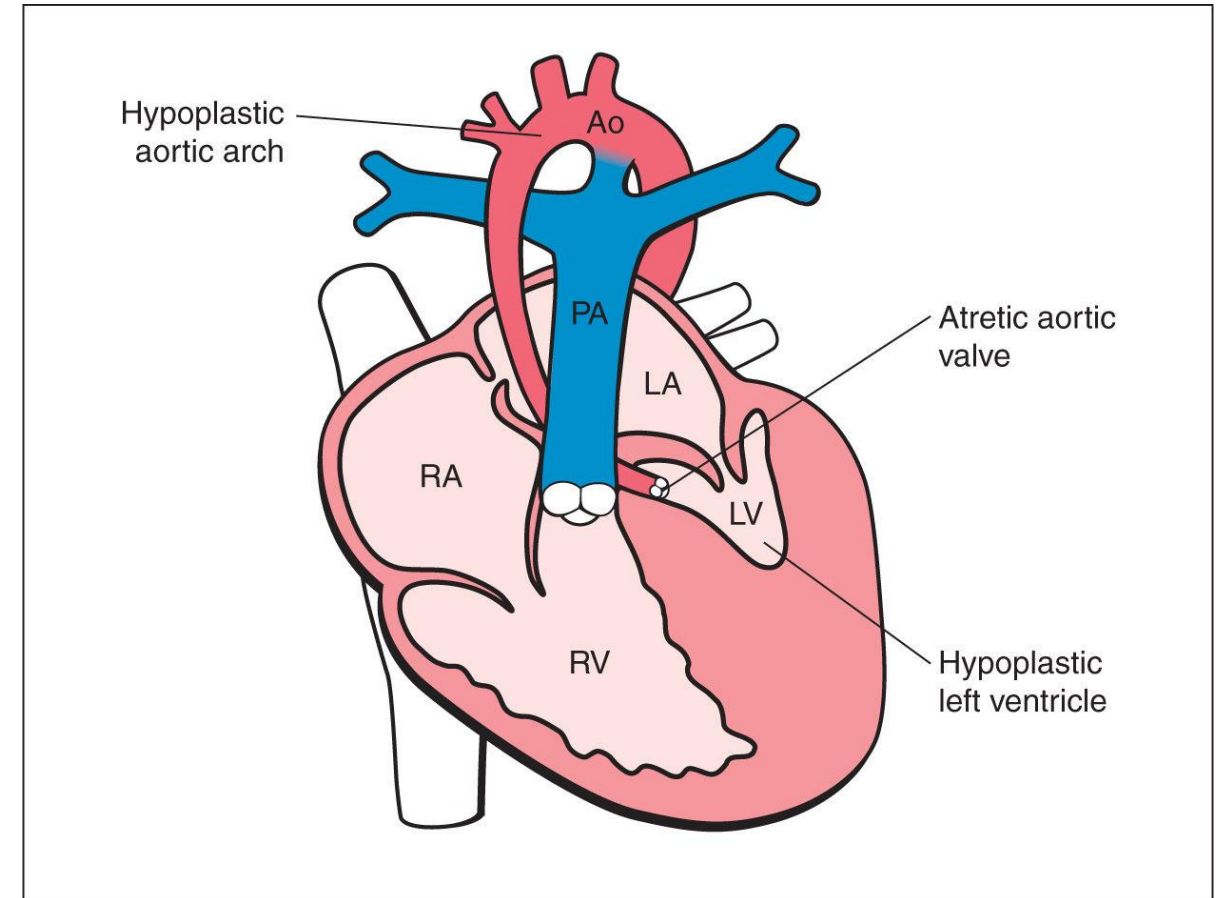


Coarctation of Aorta either just proximal (infantile form) or just distal (adult form) to the ductus arteriosus is a narrowing of the aortic lumen, leading to outflow obstruction



Aortic Stenosis and Atresia

The aortic valvular orifice may be narrowed or stenosed by acquired disease (RHD, degenerative calcific aortic stenosis), by anomalous development (atresia or stenosis), or by a combination of both (calcification of a congenitally malformed valve).





Thank You



References:

Text book of Pathology, Harsh Mohan

<https://obgynkey.com/hypoplastic-left-heart-syndrome-and-critical-aortic-stenosis/>