



SNS COLLEGE OF ALLIED HEALTH SCIENCES

SNS Kalvi Nagar, Coimbatore - 35

Affiliated to Dr MGR Medical University, Chennai



DEPARTMENT OF CARDIAC TECHNOLOGY

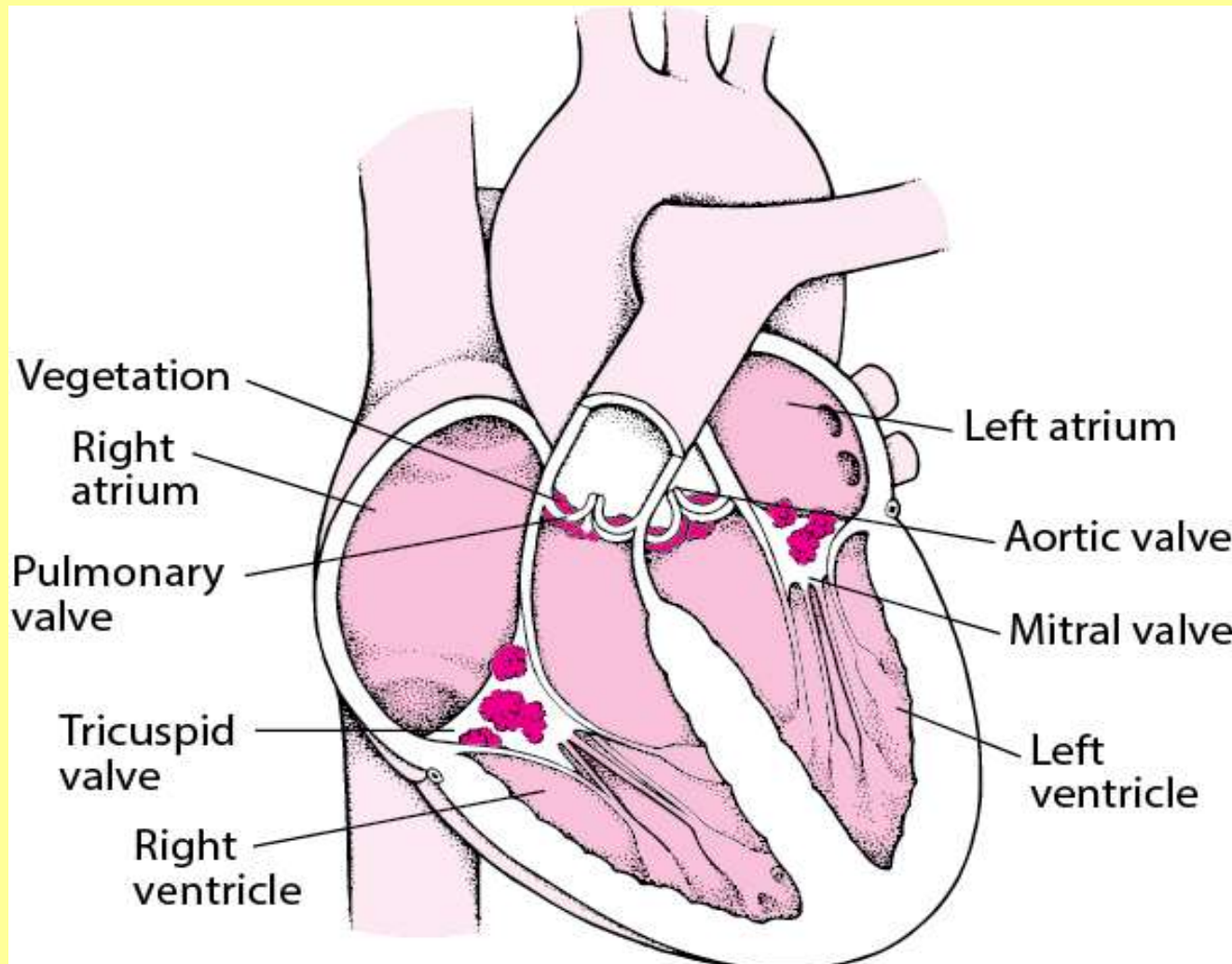
COURSE NAME: PATHOLOGY

I YEAR

SYSTEMIC PATHOLOGY:

TOPIC II: INFECTIVE ENDOCARDITIS

Infective Endocarditis





Introduction

- Endocarditis is a life-threatening inflammation of the inner lining of the heart's chambers and valves. This lining is called the endocardium.

Causes

- Endocarditis is usually caused by an infection. Bacteria, fungi or other germs get into the bloodstream and attach to damaged areas in the heart.



Types



Bacterial acute endocarditis-is usually caused by staphylococcus aureus bacteria and occasionally by the bacterial strains brucella and listeria. This form of infective endocarditis, compared to other forms, is more likely to affect normal heart valves.

Bacterial subacute endocarditis-It's an infection that occurs when bacteria enter the bloodstream and attack the lining of the heart valves. This causes growths, called vegetations, on the heart valves



Types



prosthetic valvular endocarditis (PVA)- PVE is usually classified as early PVE (acquired perioperatively) and late PVE (resulting from infections unrelated to the valve operation).

Atypical verrucous endocarditis

- Libman-Sacks endocarditis, also known as mural or verrucous endocarditis, is a form of nonbacterial thrombotic endocarditis (NBTE) which involves the presence of sterile vegetations on the cardiac valves
- **Treatment**- anticoagulation therapy.



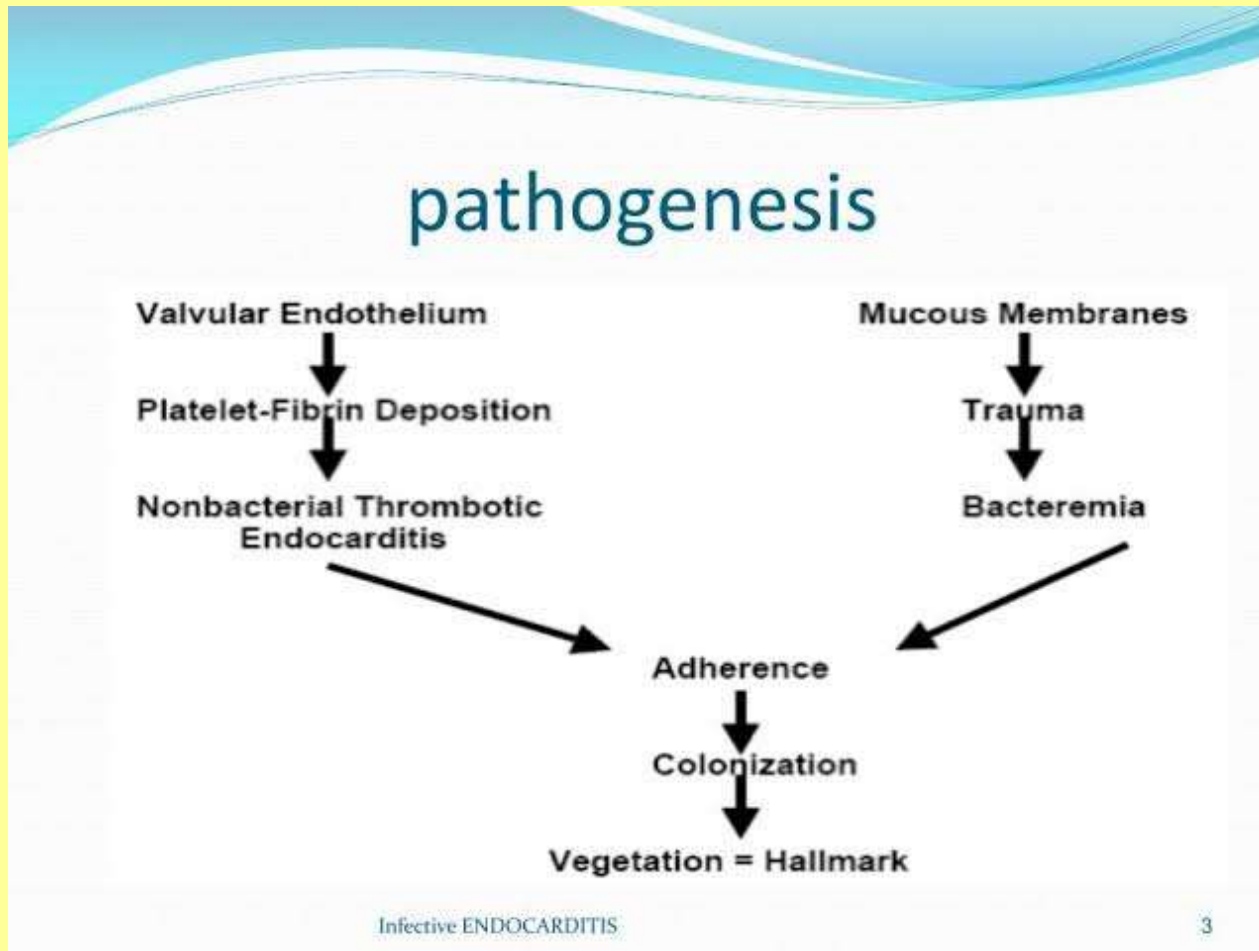
Nonbacterial thrombotic endocarditis



- Nonbacterial thrombotic endocarditis (NBTE) is a rare condition that refers to a spectrum of noninfectious lesions of the heart valves that is most commonly seen in advanced malignancy
- **Treatment**-Heparin is more effective than warfarin for hypercoagulability associated with malignancy.



Pathophysiology





CLINICAL FEATURES



- Heart murmur
- A higher fever of 100 – 103 degrees F
- Flu-like symptoms including chills
- Shortness of breath at rest
- Night sweats
- Chest pain while breathing
- Swelling in the feet, legs or abdomen
- Rapid heartbeat (tachycardia)
- Loss of appetite leading to weight loss
- Blood or blood cells in the urine (hematuria)
- Small red spots in the conjunctiva of the eyes and fingernails (splinter hemorrhages)
- Small painless spots on the palms of the hands or soles of the feet (Janeway lesions)
- Pain nodules in the fingertips (Osler nodes)



Risk factors



- Older age
- Artificial heart valves
- Congenital heart defects
- Implanted heart device
- Long-term catheter use.



Complication



- Heart failure
- Heart valve damage
- Stroke
- Pockets of collected pus (abscesses) that develop in the heart, brain, lungs and other organs
- pulmonary embolism
- Kidney damage
- Enlarged spleen



DIAGNOSIS

- **History collection**
- **Physical examination**
- **Blood culture test-** to rule out the infection causing microorganisms
- **Complete blood count-** particularly to detect the WBC level in the blood, Leukocytosis, low haemoglobin content, proteinuria, microscopic hematuria, raised ESR and CRP, hypergammaglobulinemia, hypocomplementemia, rheumatoid factor (+ve), high blood urea, and serum creatinine levels.
- **ECG-**ECG may reveal conduction defect due to abscess formation/ infarction due to emboli.
- Chest x-ray shows evidence of cardiomegaly or heart failure.
- Echocardiography for detection of valve vegetations.
- **Transesophageal echocardiogram-** can view the flow obstruction
- **Transthoracic echocardiogram-** dilation of chambers



Treatment-Antibiotics



Organism	Option I	Option II	Duration
Streptococcus viridans	Penicillin and aminoglycoside	Cefazolin and aminoglycoside	4 wk
Group A streptococci	Penicillin and aminoglycoside	Cefazolin and aminoglycoside	4 wk
Streptococcus Faecalis	Ampicillin and aminoglycoside	Vancomycin and aminoglycoside	6 wk
Escherichia coli	Ceftriaxone and aminoglycoside	Ampicillin and aminoglycoside	6 wk
Culture negative	Ampicillin and aminoglycoside	Cloxacillin and aminoglycoside	6 wk



Treatment



- **Medical management**-Antibiotic therapy for 6weeks
- **Surgical management**- to remove the dead tissue, scar tissue, fluid buildup, or debris from infected tissue. Surgery may also be done to repair or remove the damaged heart valve, and replace it with either man-made material or animal tissue- **Valve replacement therapy.**