



SNS COLLEGE OF ALLIED HEALTH SCIENCES

SNS Kalvi Nagar, Coimbatore - 35

Affiliated to Dr MGR Medical University, Chennai



DEPARTMENT OF CARDIAC TECHNOLOGY

COURSE NAME: PATHOLOGY

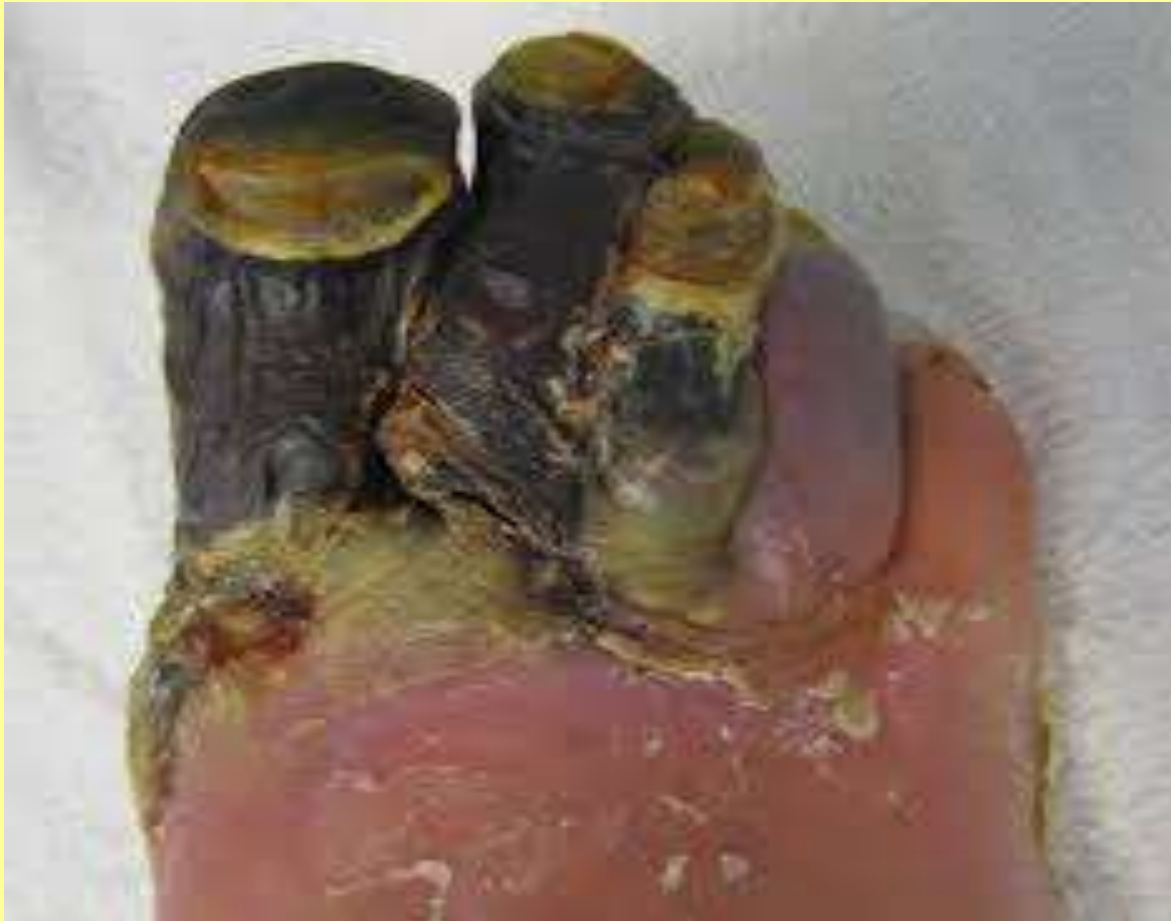I YEAR

GENERAL PATHOLOGY:

TOPIC 10: GANGRENE



GANGRENE





GANGRENE



- Gangrene is a type of dead tissue in the body
- Dead tissue is caused by an **infection** or **lack of blood flow**.
- The death of tissue often occurs in the extremities or skin from loss of blood supply. The condition often affects toes, fingers and limbs, it can also affect muscles and organs.



ETIOLOGY OF GANGRENE



- **Lack of blood supply;** blood provides oxygen and nutrients to the body. It also provides immune system with antibodies to ward off infections.
- Without a proper blood supply, cells can't survive, and the tissue decays.
- **Infection.** An untreated bacterial infection can cause gangrene.
- **Traumatic injury.** Gunshot wounds or crushing injuries from car crashes can cause open wounds that let bacteria into the body. If the bacteria infect tissues and remain untreated, gangrene can occur.



CAUSING MICROORGANISMS



- clostridia myonecrosis
- *C. perfringens*
- *Clostridium tetani*,
- *Clostridium sordelli*



TYPES

- **Dry gangrene.** This type of gangrene involves dry and shriveled skin that looks brown to purplish blue or black. Dry gangrene may develop slowly. It occurs most commonly in people who have diabetes or blood vessel disease, such as atherosclerosis.
- **Wet gangrene.** Gangrene is referred to as wet if there's a bacterial infection in the affected tissue. Swelling, blistering and a wet appearance are common features of wet gangrene. Wet gangrene may develop after a severe burn, frostbite or injury. It often occurs in people with diabetes who unknowingly injure a toe or foot. Wet gangrene needs to be treated immediately because it spreads quickly and can be deadly.



TYPES



- **Fournier's gangrene.** Fournier's gangrene involves the genital organs. Men are more often affected, but women also can develop this type of gangrene. An infection in the genital area or urinary tract causes this type of gangrene.
- **Meleney's gangrene.** This rare type of gangrene — also called **progressive bacterial synergistic gangrene** — is usually a complication of surgery. People with Meleney's gangrene develop painful skin lesions one to two weeks after their operations.



PATHOPHYSIOLOGY



Due to any causes the normal tissue got infected in extremities → loss of blood supply to the tissues → it starts necrosing → the colour of tissues turns grayish black in colour → foul smell → gangrene is formed.

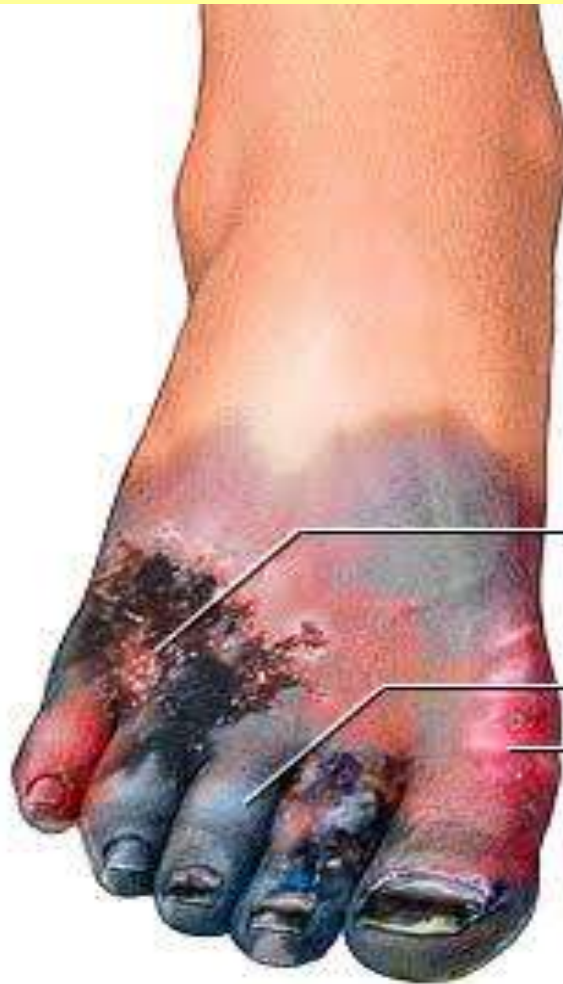

Risk factors



- Diabetes
- Blood vessel disease
- Severe injury or surgery
- Smoking
- Obesity
- Immuno suppression
- Medications or drugs that are injected.
- Complications of COVID-19(coagulopathy)

CLINICAL FEATURES



Gangrene is the death of tissue in part of the body.

Foul-smelling discharge

Surface and subsurface discoloration



CLINICAL FEATURES



- Skin discoloration — ranging from pale to blue, purple, black, bronze or red, depending on the type of gangrene you have
- Swelling
- Blisters
- Sudden, severe pain followed by a feeling of numbness
- A foul-smelling discharge leaking from a sore
- Thin, shiny skin, or skin without hair
- Skin that feels cool or cold to the touch



DIAGNOSIS



- History collection
- Physical examination

Lab investigation

- Blood test- to rule out the infection(if it is the WBC count will be increased)
- Blood culture-to the specific causative organism
- Fluid Sample collection(from affected site blisters)

Medical imaging

- Arteriogram- to rule out whether if it is related to the circulatory problem



DIAGNOSIS



- **CT & MRI-** by using these imaging we can find out the spreading of the gangrene throughout the body



COMPLICATION



- Bacteria can spread quickly to other tissues and organs. If not treated a body part need to be removed (**amputated**) to save the patients life.
- Removal of infected tissue can lead to scarring or the need for reconstructive surgery



MEDICAL MANAGEMENT



- **Antibiotics**

Mild infection-cephalexin , Dicloxacillin

amoxicillin-clavulanate, clindamycin

Severe infection-intravenously with

ciprofloxacin-clindamycin

piperacillin-tazobactam

imipenem-cilastatin.



SURGICAL MANAGEMENT



- **Surgery to remove the dead tissue.** This is called **debridement**. It can help to keep the gangrene from spreading to healthy tissues nearby. In cases where the gangrene is widespread, a finger, toe, or even a limb may need to be amputated.



- **Maggot debridement.** This is a nonsurgical alternative to traditional debridement. During this procedure, clean fly larvae are placed on the affected area to eat away dead tissue and remove bacteria. This is a painless procedure.
- **Hyperbaric oxygen therapy.** During this procedure, the patient can be placed in a special pressurized chamber that administers oxygen at high pressures, forcing more oxygen into the affected area. This can promote speed healing and help kill bacteria. This treatment is especially effective in people who develop gangrene from diabetic foot ulcers.



- **Vascular surgery-Restoring blood flow**

Bypass surgery –redirects the flow of blood and bypasses the blockage by connecting (grafting) one of the veins to a healthy part of an artery

Angioplasty –a tiny balloon is placed into a narrow or blocked artery and is inflated to open up the vessel; a small metal tube, known as a stent, may also be inserted into the artery to help keep it open



- **Reconstructive surgery**
- Reconstructive surgery using a skin graft & used to cover the area of skin damaged by gangrene.
- During a skin graft, remove healthy skin from another part of the body (usually a part that would be covered by clothing), and reconnect it over to the another damaged area.



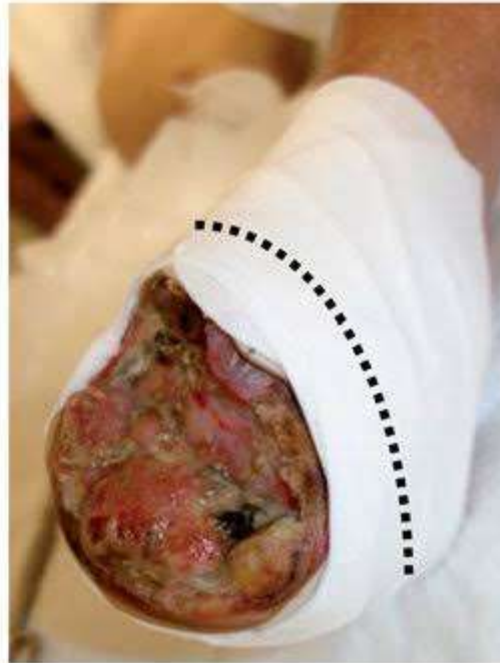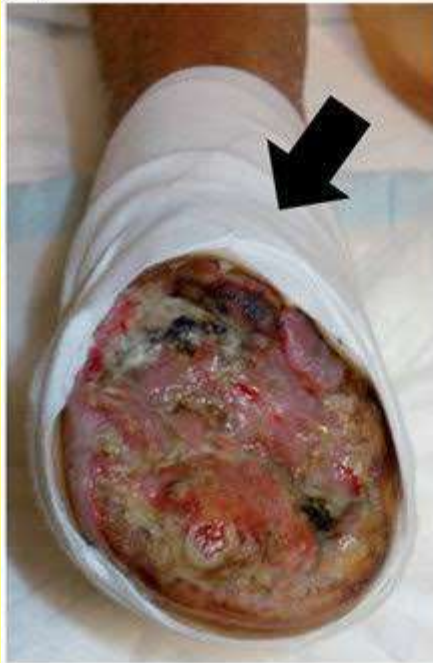PREVENTION



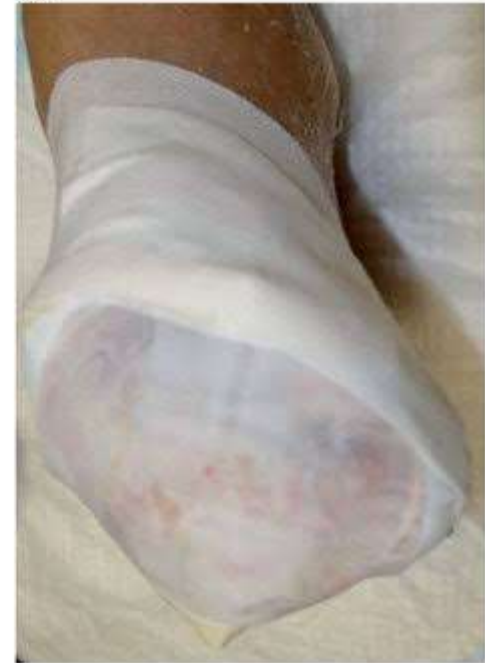- Cessation of tobacco usage
- Precautions from infections
- Proper diet control

Maggot debridement

(a)



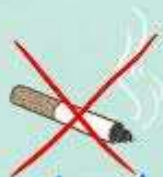(b)



How to Prepare for Hyperbaric Chamber Treatment



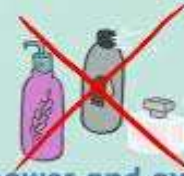Follow instructions
for yawning and
swallowing



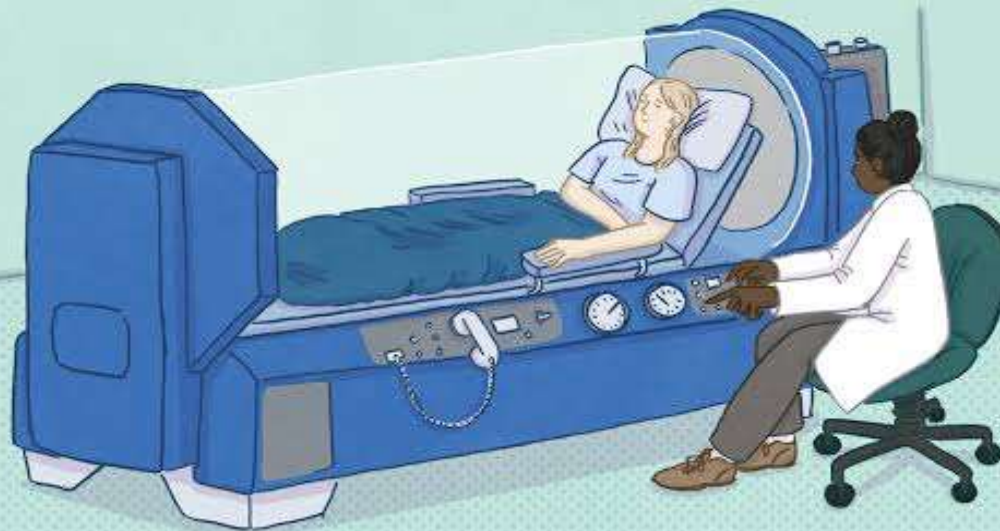
Do not smoke



Avoid alcohol
and carbonated
beverages

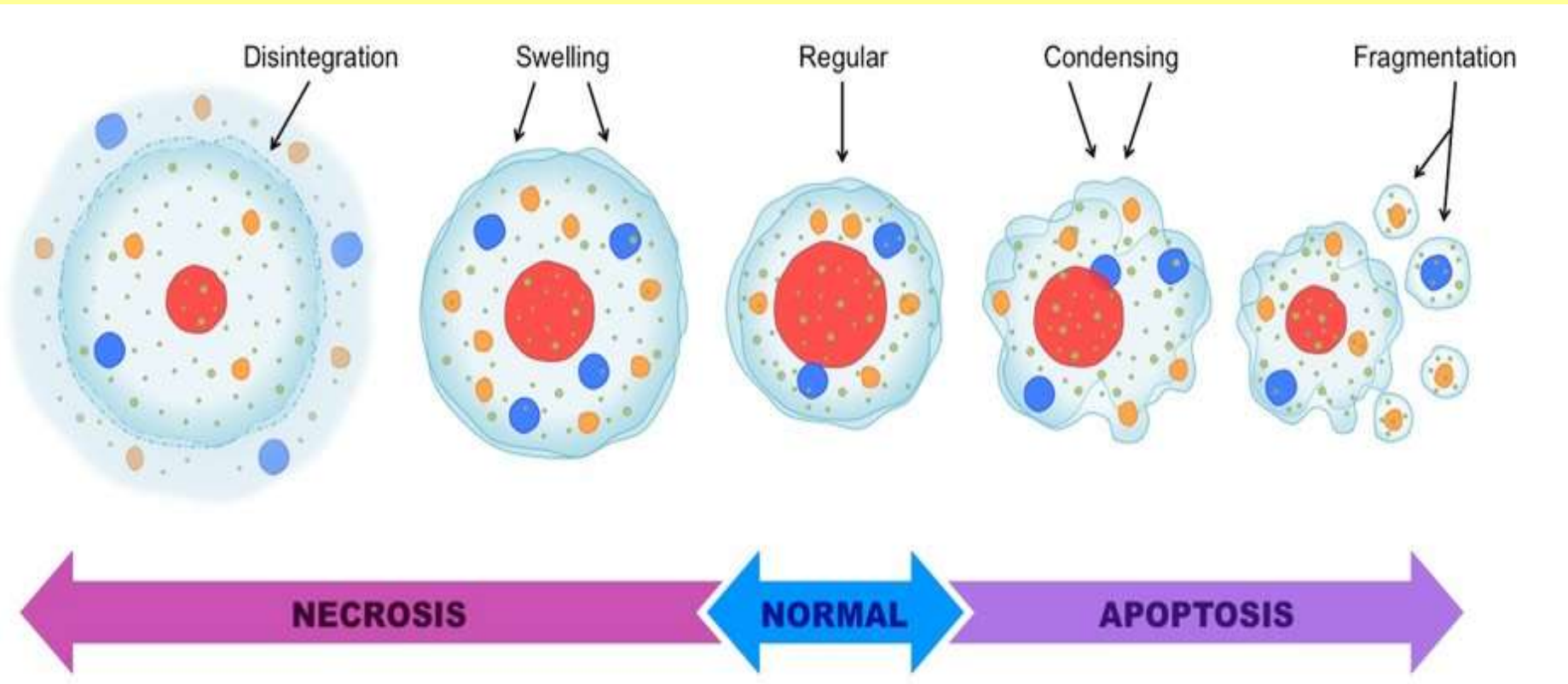


Shower and avoid
all perfumes
or lotions





NECROSIS & APOPTOSIS





TYPES OF NECROSIS



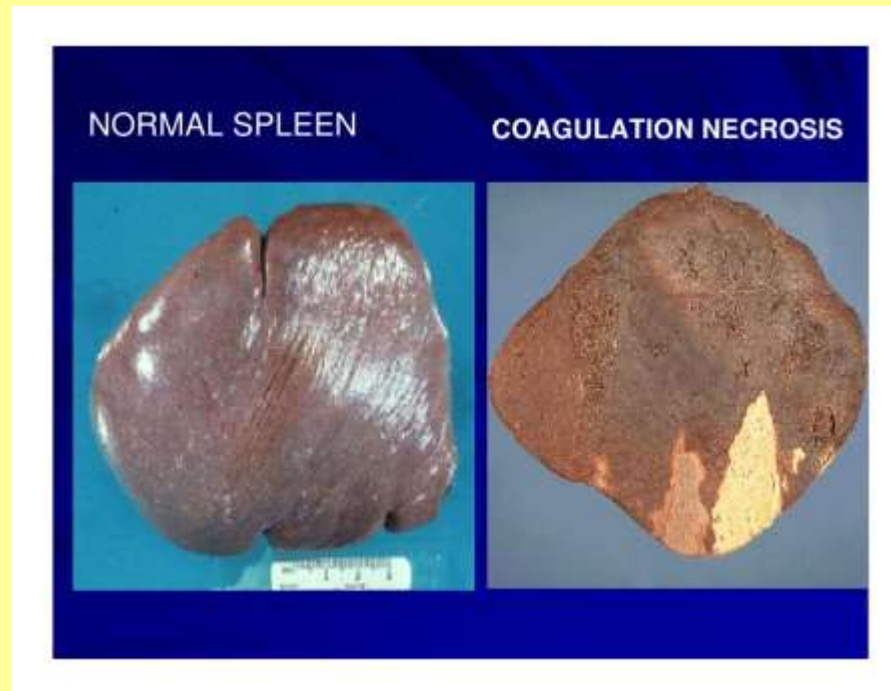- Coagulative necrosis
- Liquefactive necrosis
- Caseous necrosis
- Fat necrosis
- Fibrinoid necrosis



COAGULATIVE NECROSIS



- Preservation of general tissue architecture
- Affected tissue is firm Denaturation of structural proteins and enzymatic digestion of cells. Example – Heart, kidney, spleen.

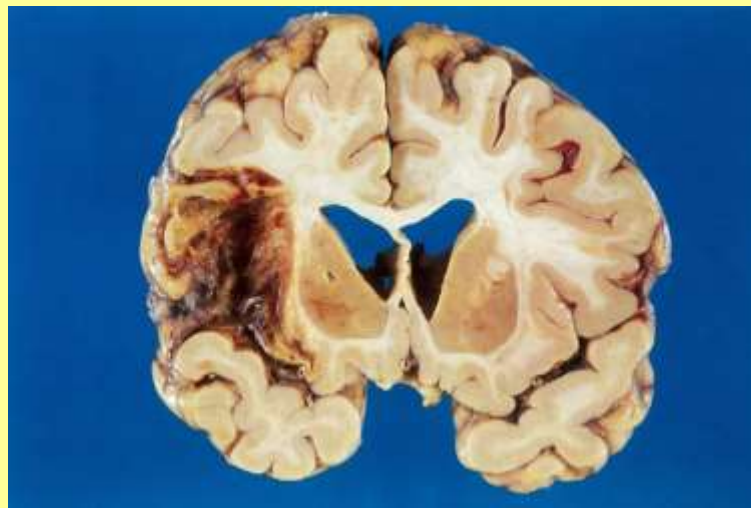



LIQUIFACTIVE NECROSIS



- The tissue becomes liquid viscous mass
- Material is creamy yellow in colour
- Seen in brain, abscess.





WET GANGRENE

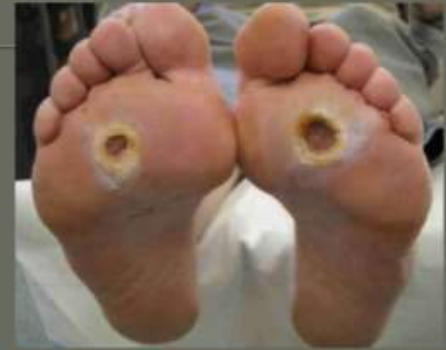

- Occurs in moist tissues like mouth, bowel, lung, cervix, Diabetic foot Bed sores

Wet Gangrene

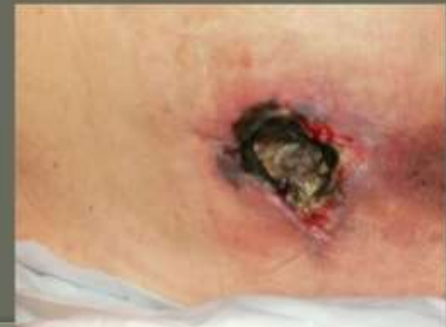- **Diabetic foot**

- high sugar content in the necrosed tissue which favours growth of bacteria.



- **Bed sores**

- bed-ridden patient due to pressure on sites like the sacrum, buttocks and heels





DRY GANGRENE



- Toes and feet, hand due to arteriosclerosis

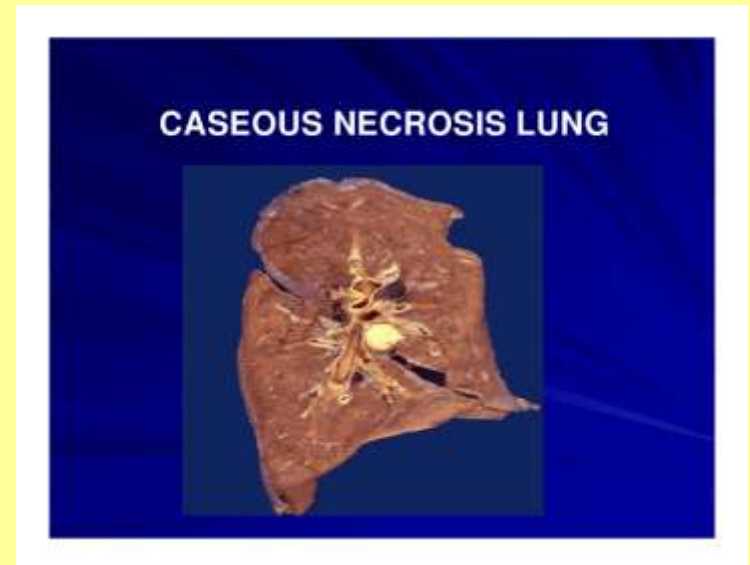




CASEOUS NECROSIS



- Type of coagulative necrosis
- Seen in Tuberculosis infections
- Tissue is cheesy white in appearance
- The tissue architecture is preserved

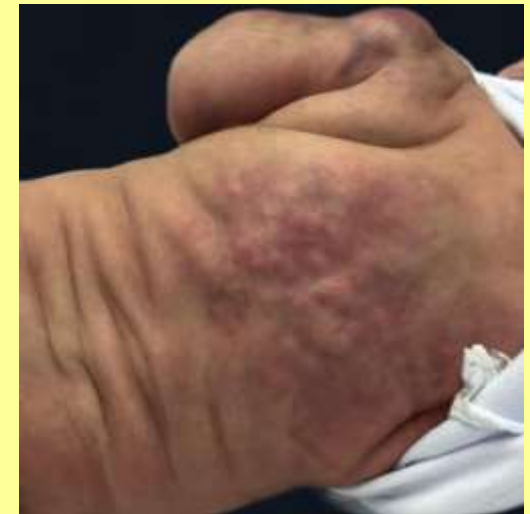



FAT NECROSIS



- Seen in pancreas, breast
- In acute pancreatitis ,activated lipase causes fat necrosis.
- Grossly visible chalky white areas.
- Presence of shadowy outlines of necrotic cells.





FIBRINOID NECROSIS



- Deposition of fibrin like material Seen in immunologic cell injury, hypertension ,peptic ulcer.

