



**SNS COLLEGE OF ALLIED HEALTH SCIENCES
SNS KALVI NAGAR, COIMBATORE-35
AFFILIATED TO Dr MGR UNIVERSITY, CHENNAI**

**DEPARTMENT OF OPERATION THEATRE AND ANAESTHESIA
TECHNOLOGY**

3rd YEAR

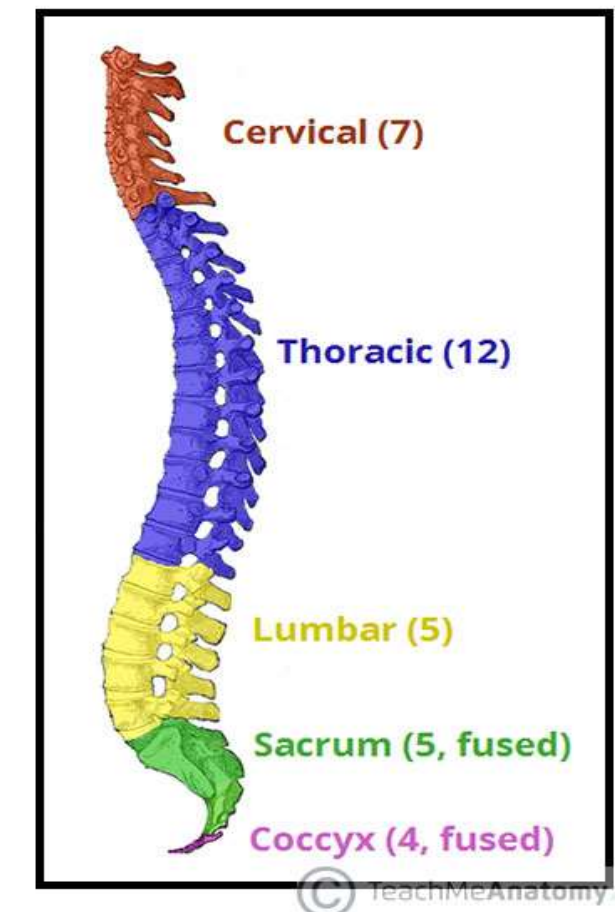
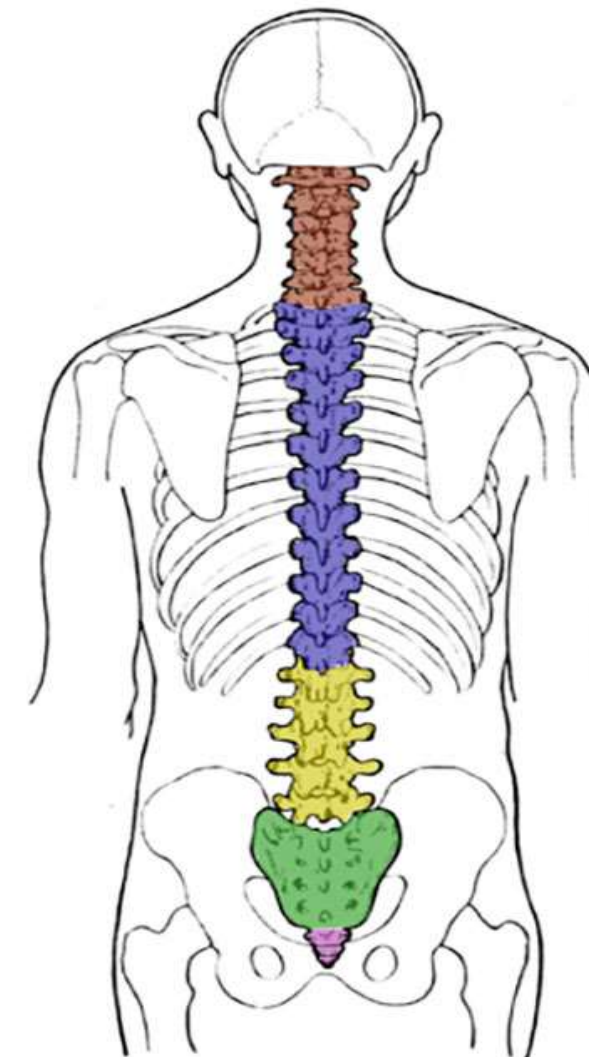
PAPER 2: PRINCIPLES OF ANAESTHESIA -2

TOPIC: EPIDURAL ANAESTHESIA

APPLIED ANATOMY:

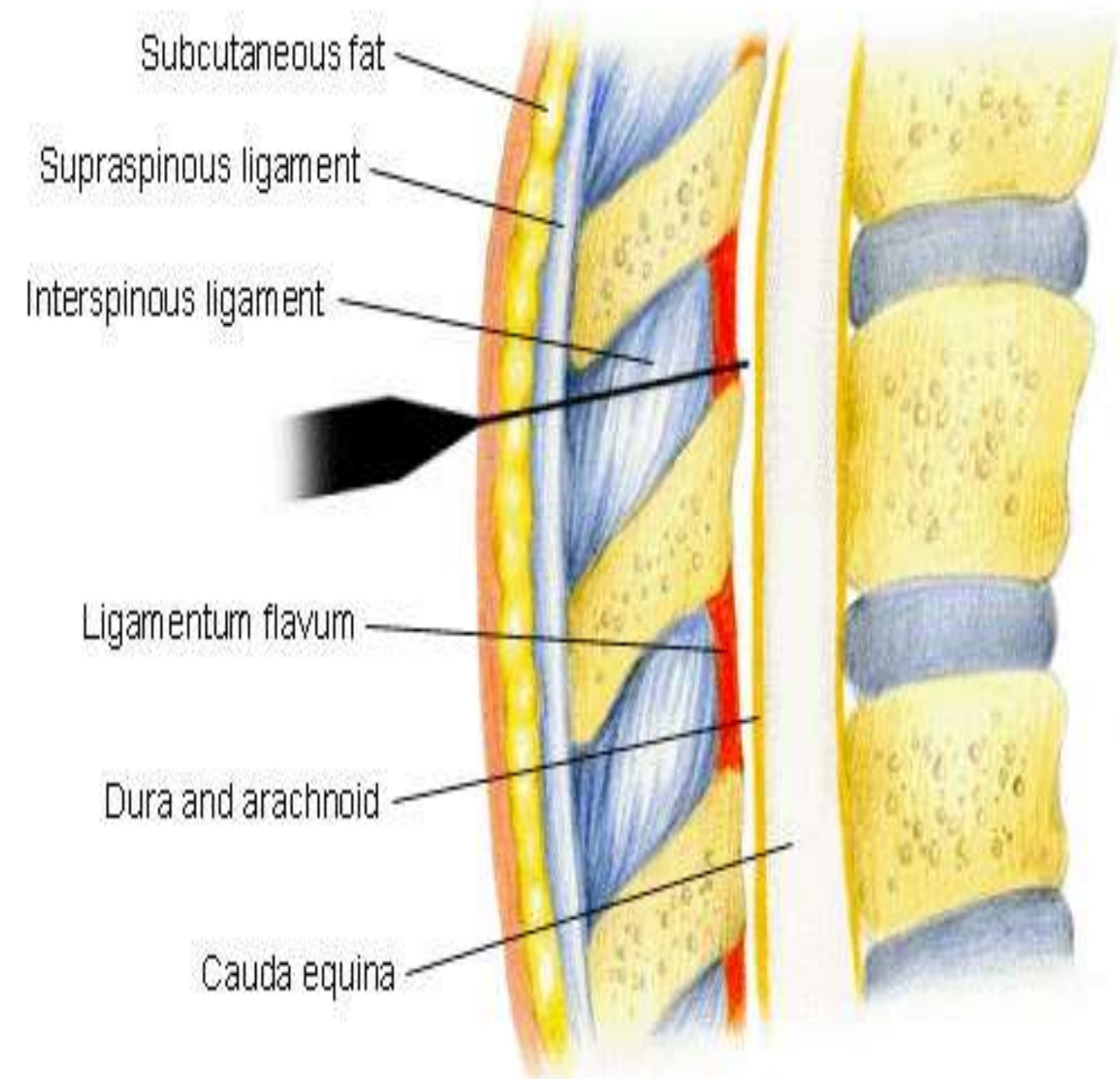
VERTIBRAL COLUMN CONSISTS OF **33** VERTEBRAE:

CERVICAL-7
THORACIC-12
LUMBAR-5
SACCRUM -5
COCCYX-4



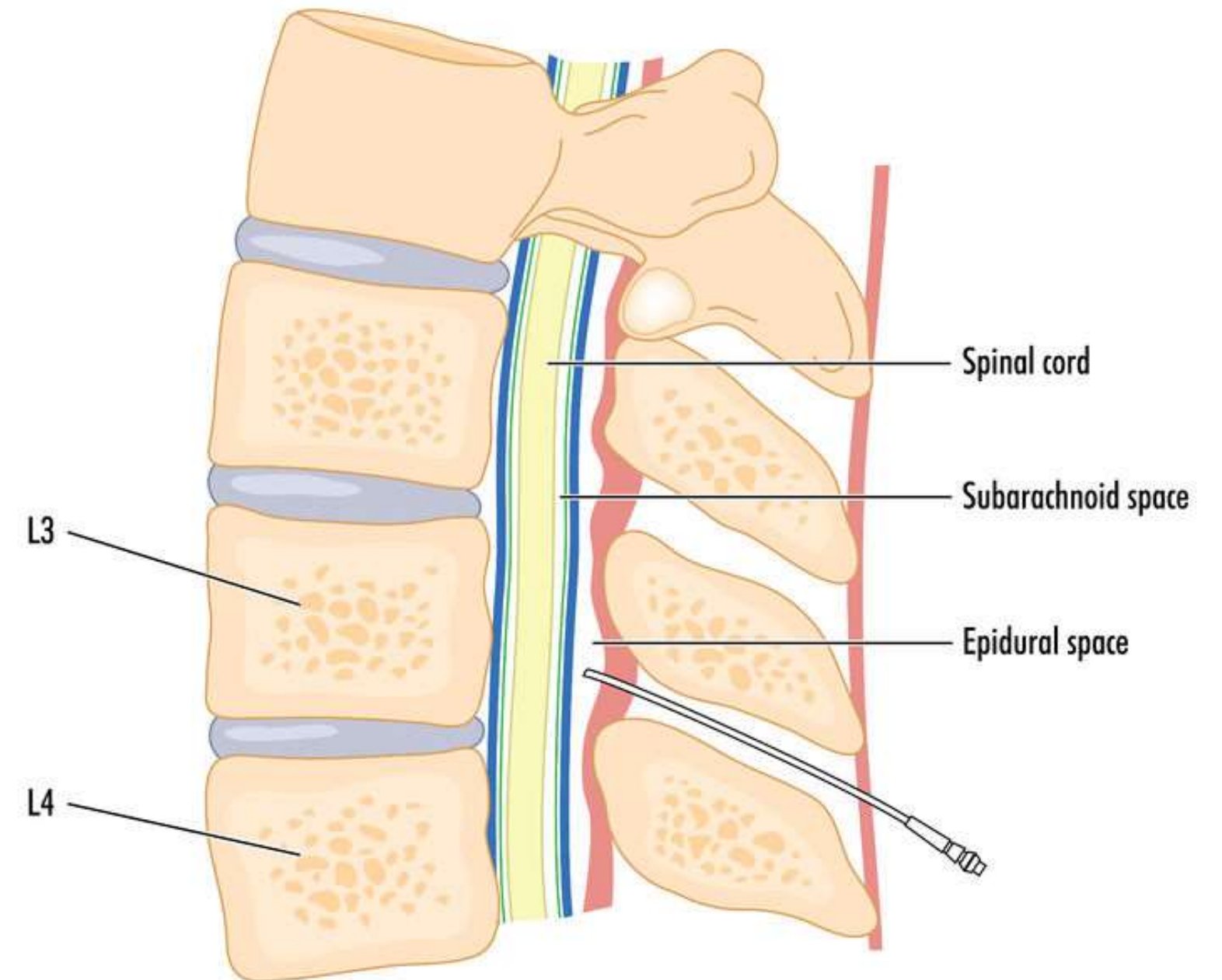
STRUCTURES:

1. SKIN
2. SUBCUTANEOUS TISSUE
3. SUPRASPINOUS LIGAMENT
4. INTERSPINOUS LIGAMENT
5. LIGAMENTUM FLAVUM
6. DURA MATER
7. ARACHNOID MATER
8. PIA MATER



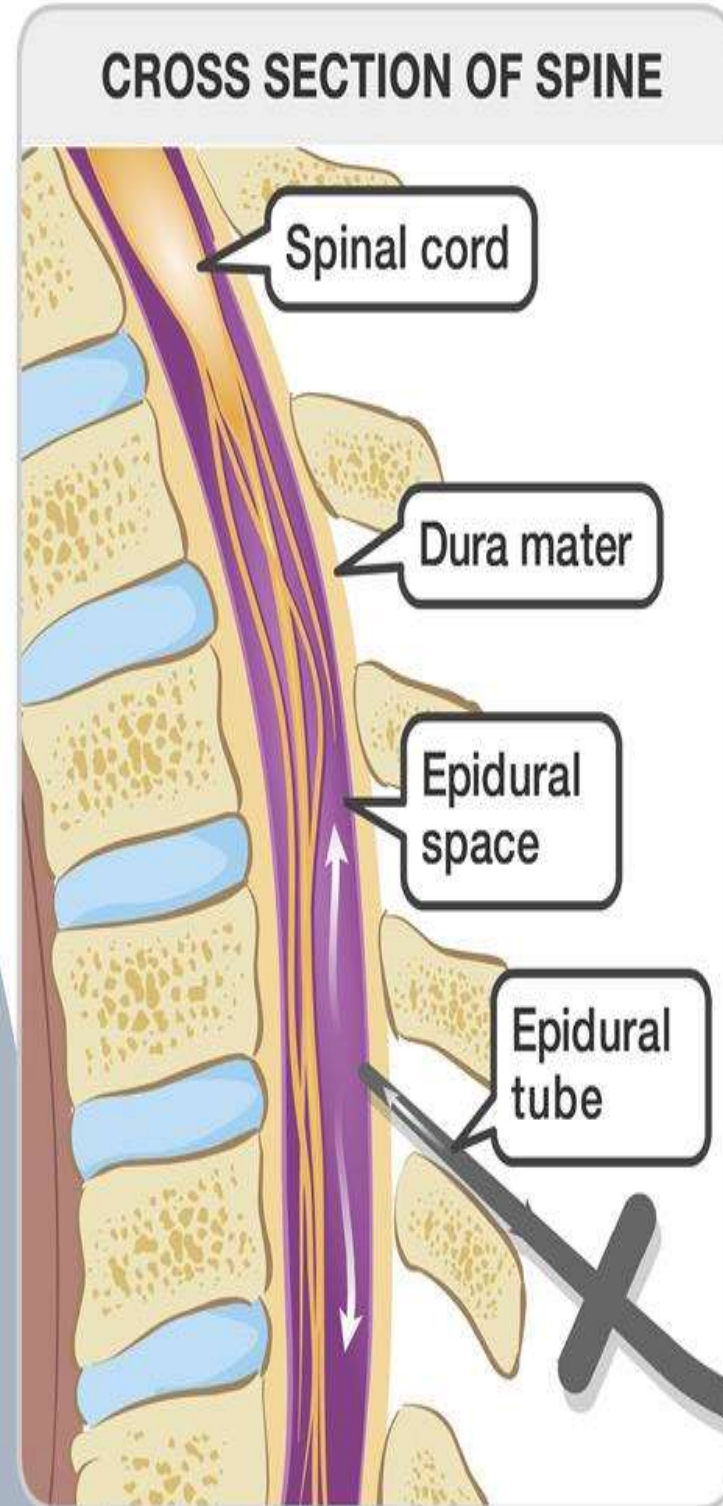
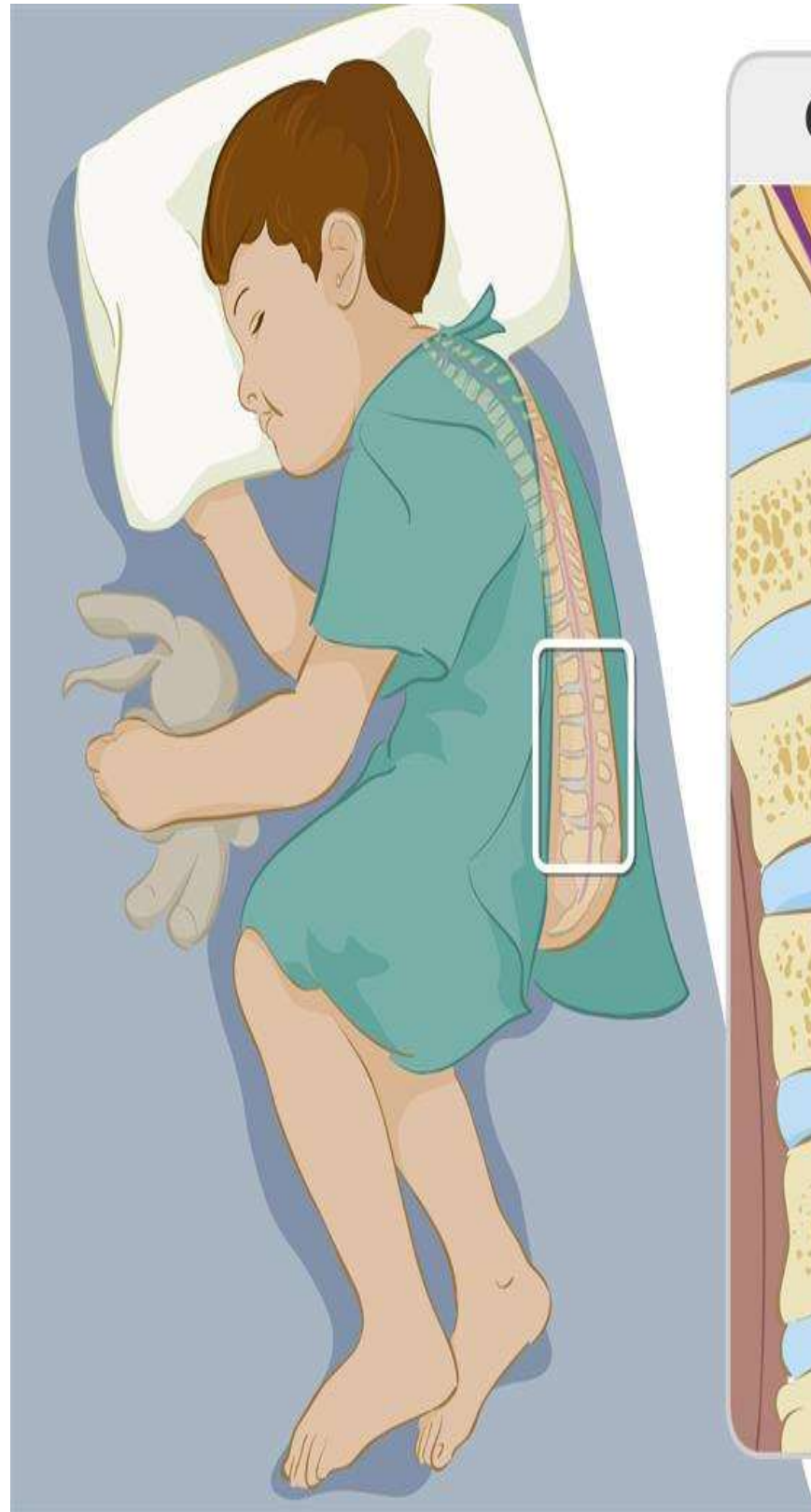
EPIDURAL SPACE:

- LIES OUTSIDE THE DURAMATER (BETWEEN DURA & LIGAMENTUM FLAVUM).
- EPIDURAL GIVES IN THIS SPACE.



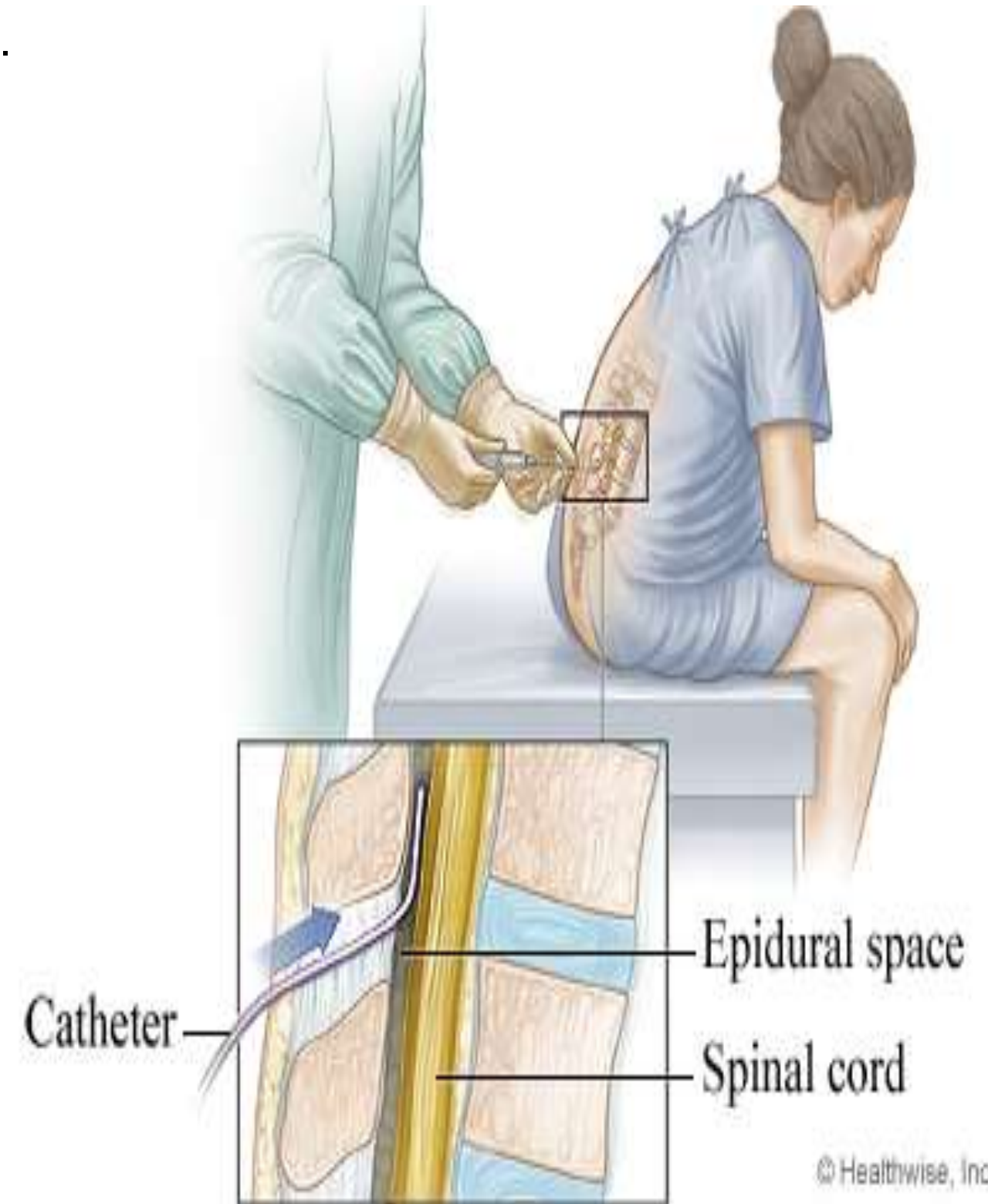
POSITION:

1.



© AboutKidsHealth.ca

2.



© Healthwise, Incorporated



EPIDURAL NEEDLE:

TUOHY NEEDLE

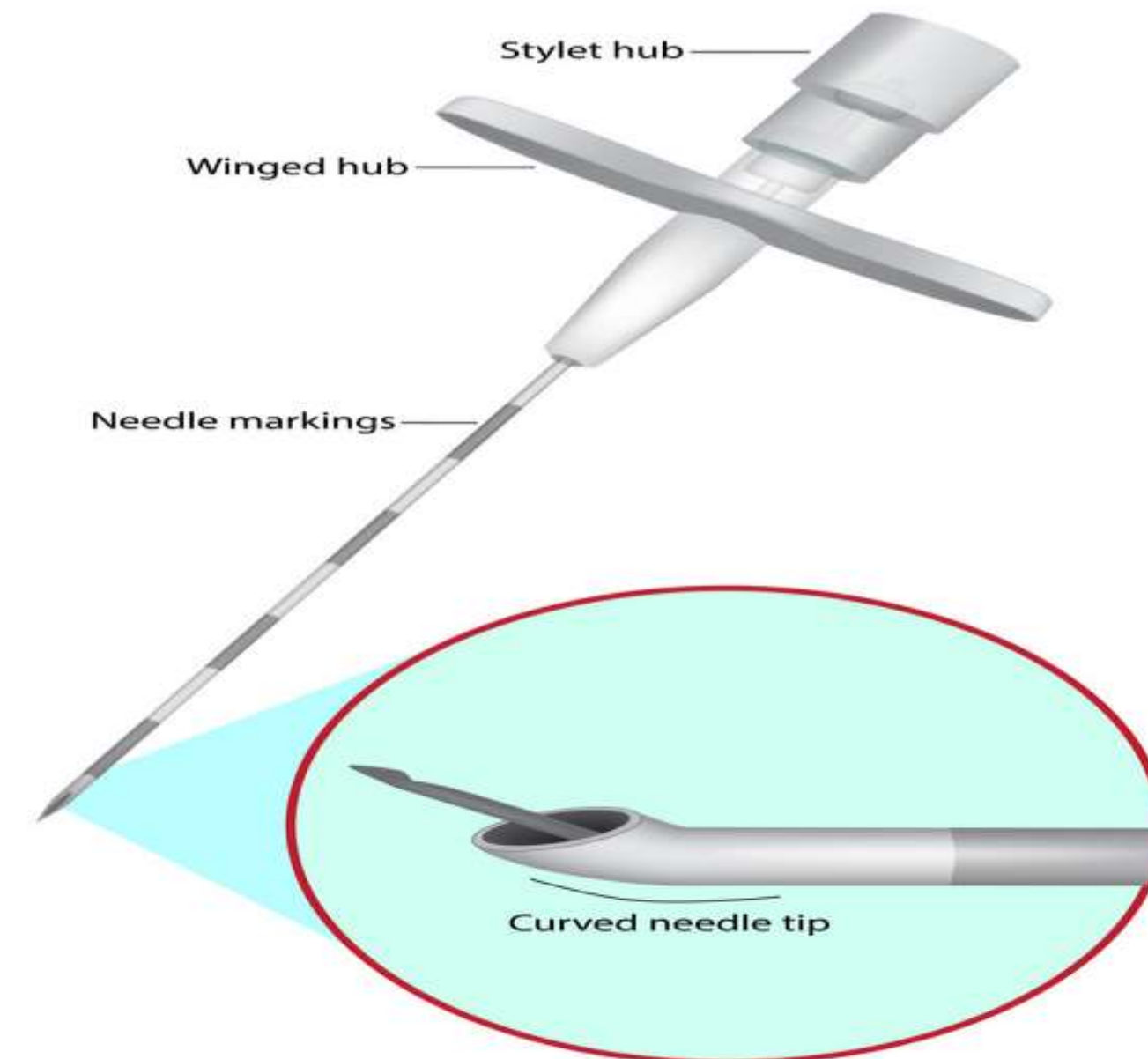
TOTAL LENGTH -9CM

NEEDLE LENGTH -8CM

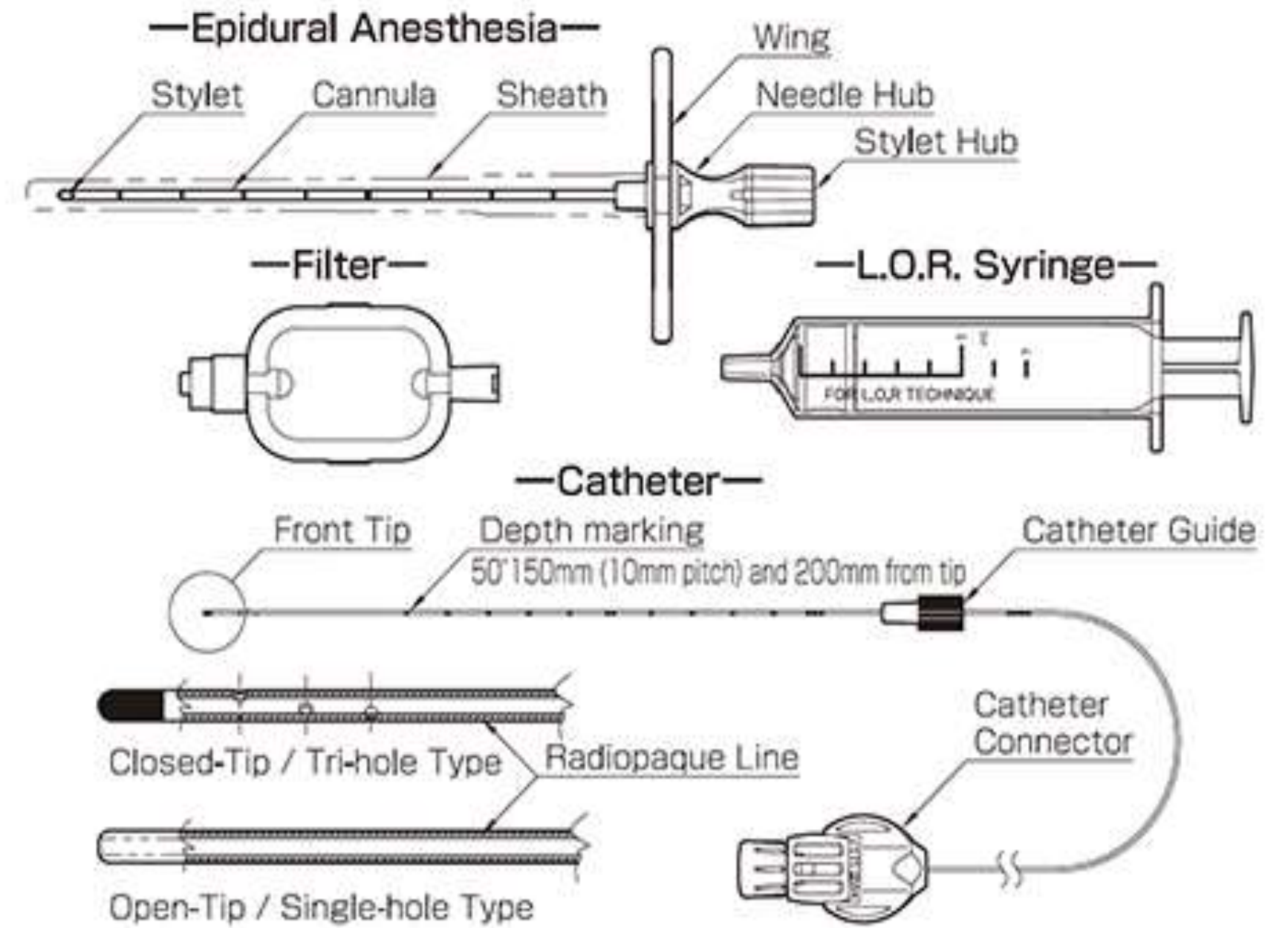
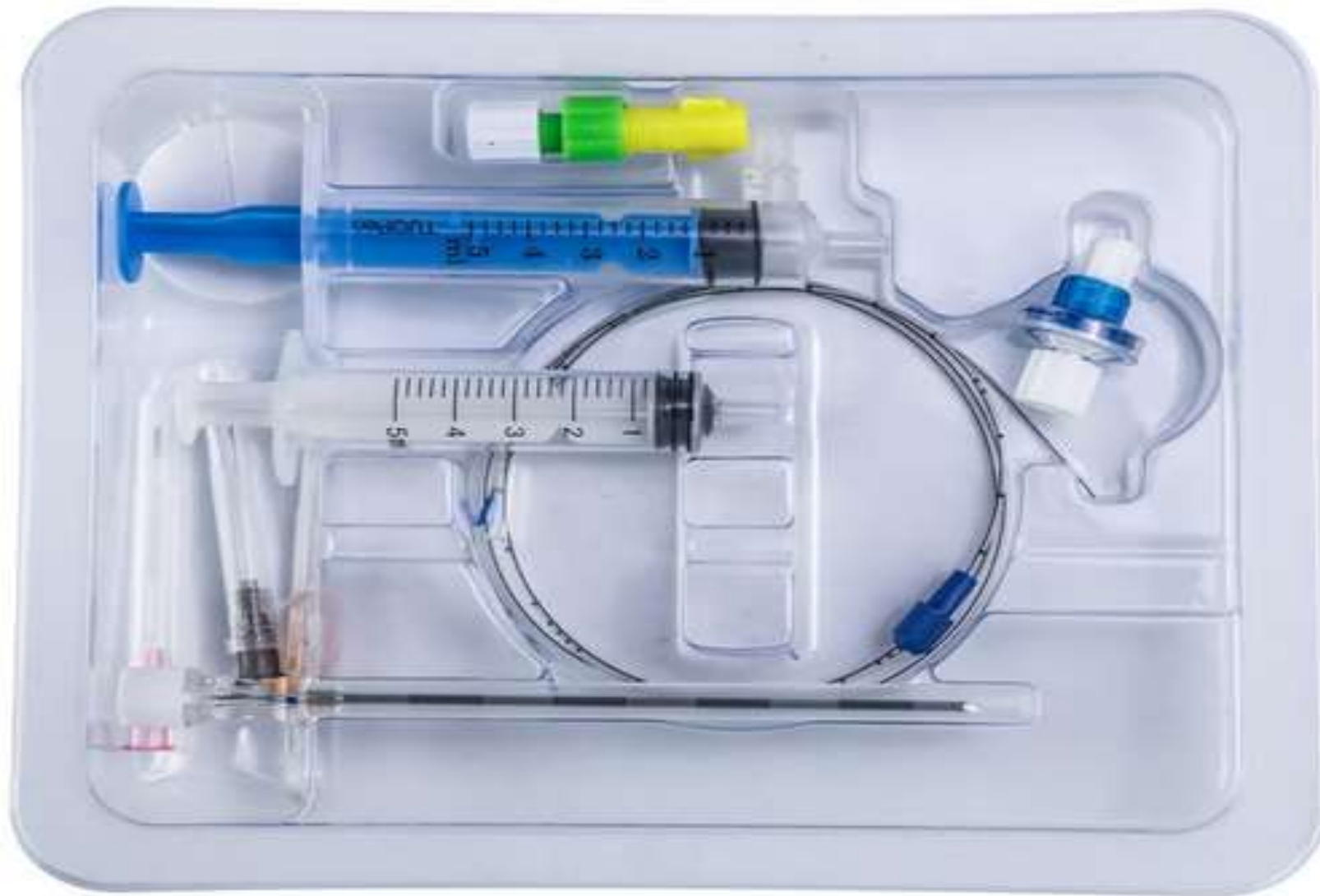
HUB&STYLET -1CM

THICKNESS -16G,17G,18G

- THERE WILL BE 1CM MARKINGS FROM TIP WITH ALTERNATING COLOUR TO ASSESS THE DEPTH OF EPIDURAL SPACE
- THE TIP IS HAVING STYLET CURRVATURE & BEVEL OF THE NEEDLE POINT IS FULLY BLUNT IS CALLED (HUBER POINT)



EPIDURAL SET:





TECNIQUE:

- GRADUATED POLYVINYL CATHETER PASSED THROUGH TUOHY NEEDLE INTO EPIDURAL SPACE ,
- AFTER PLACING THE CATHETER IN EPIDURAL SPACE ,THE NEEDLE IS REMOVED &THE CATHETER IS SECURED

DRUGS:

2%XYLOCAINE(L.A)

XYLOCAINE WITH ADRENALINE



ADVANTAGES:

- LONGER DURDATION
- ONSET OF HYPOTENSION IS MINIMAL
- CHRONIC PAIN CONTROL
- OBSTETRIC ANAESTHESIA & ANALGESIA

DISADVANTAGES:

- LARGE VOLUME NECESSARY
- DANGER OF DURAL PUNCTURE
- ACCIDENTAL TOTAL SPINAL



CONTRAINDICATIONS:

- THROMBOCYTOPENIA
- SEVERE HAEMORRHAGE
- COAGULATION DEFECT
- LOCAL INFLAMMATION



THANK YOU