



SNS COLLEGE OF ALLIED HEALTH SCIENCES

SNS Kalvi Nagar, Coimbatore - 35

Affiliated to Dr MGR Medical University, Chennai



**DEPARTMENT OF CARDIO PULMONARY PERFUSION CARE
TECHNOLOGY & OPERATION THEATRE AND ANAESTHESIA
TECHNOLOGY**

COURSE NAME : GENERAL PATHOLOGY

I YEAR

TOPIC : CELL INJURY

SUB TOPIC : REVERSIBLE & IRREVERSIBLE INJURY



Cellular Injury



Contents

- Definition
- Causes of Cell Injury
- Pathogenesis and Morphology of Cell Injury
- Types of Cell Injury
 - Reversible - Cell Swelling & Fatty Change
 - Irreversible - Apoptosis and Necrosis



Homeostasis of Cell



- A condition in which the **internal environment of the body remains relatively constant** despite changes in the external environment.
- Homeostasis is essential for survival and functions of cell
- Maintenance of body temperature and levels of glucose in the blood

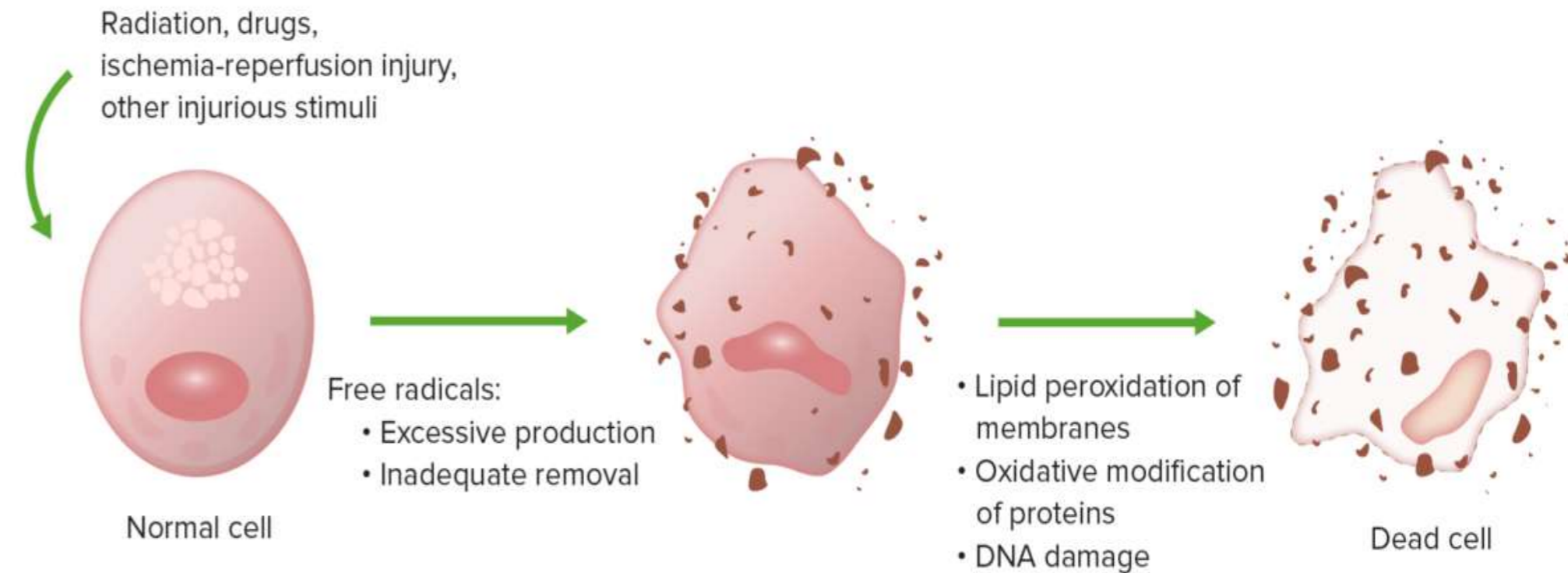
Cell Part	Function
Cell membrane	Controls what enters and leaves the cell
Nuclear membrane	Controls what enters and leaves the nucleus
Nucleus	Control center of the cell
Chromosomes	Genetic information in the nucleus
Endoplasmic Reticulum	Transport system in cell
Ribosome	Organelle makes proteins
Golgi Body	Organelle packages proteins
Vacuole	Stores water and/or waste
Lysosome	Breaks down old cell parts
Mitochondria	Organelle for cellular respiration – provides energy



Definition



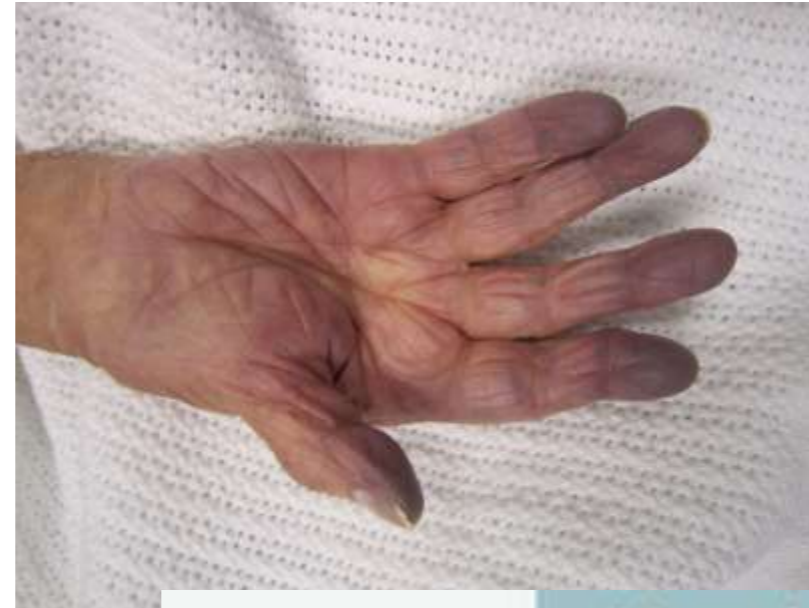- Defined as a variety of stress a cell encounters as a result of internal or external environmental changes.
- Cell Injury is common to all pathologic processes
- Cell Injury results from a disruption of one or more of the cellular components that maintain cell viability



Causes of Cell Injury

Oxygen Deprivation

- Hypoxia
- Ischemia
- Infarction



Physical Agents

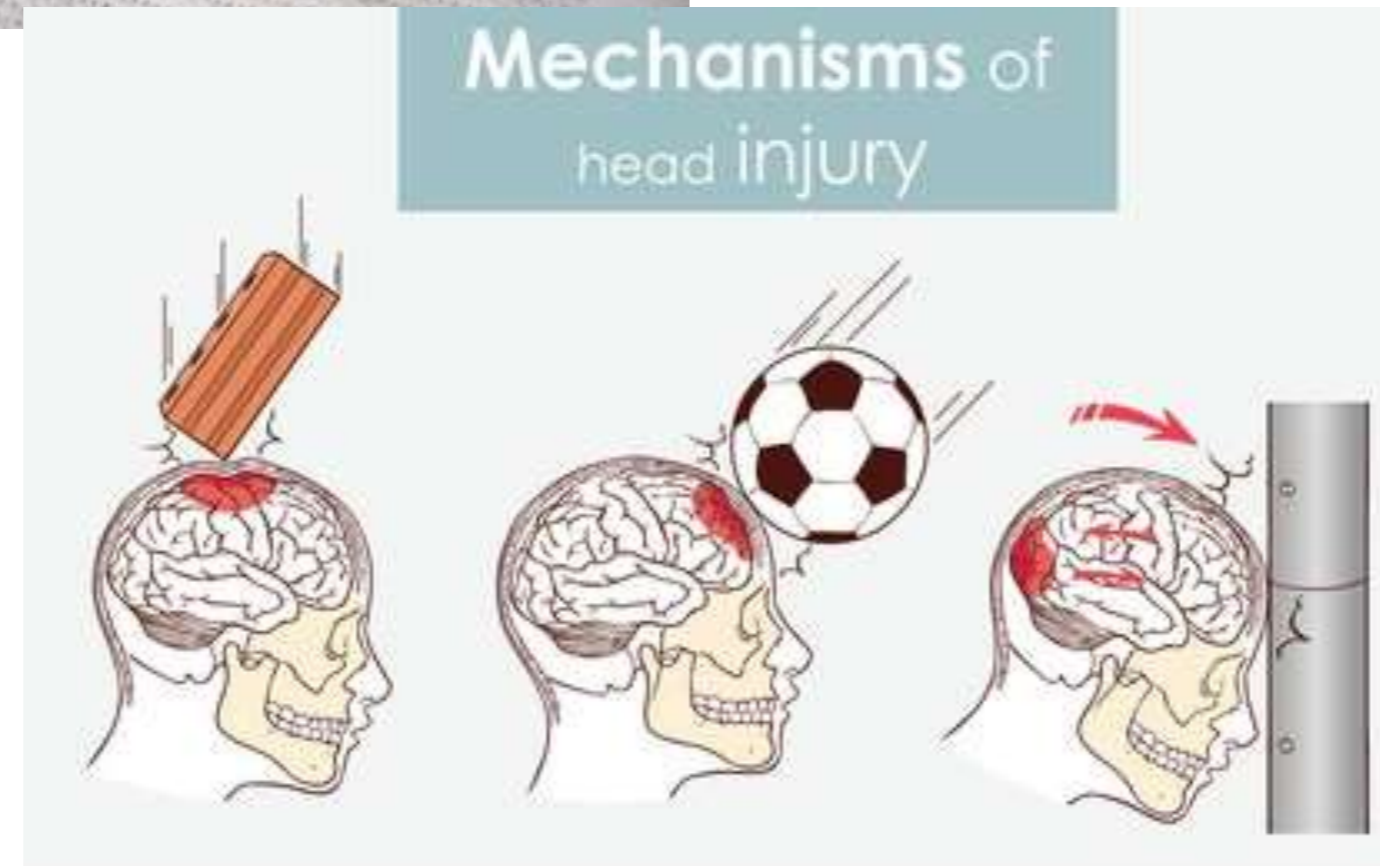
Mechanical Trauma

Extremes of Temperatures

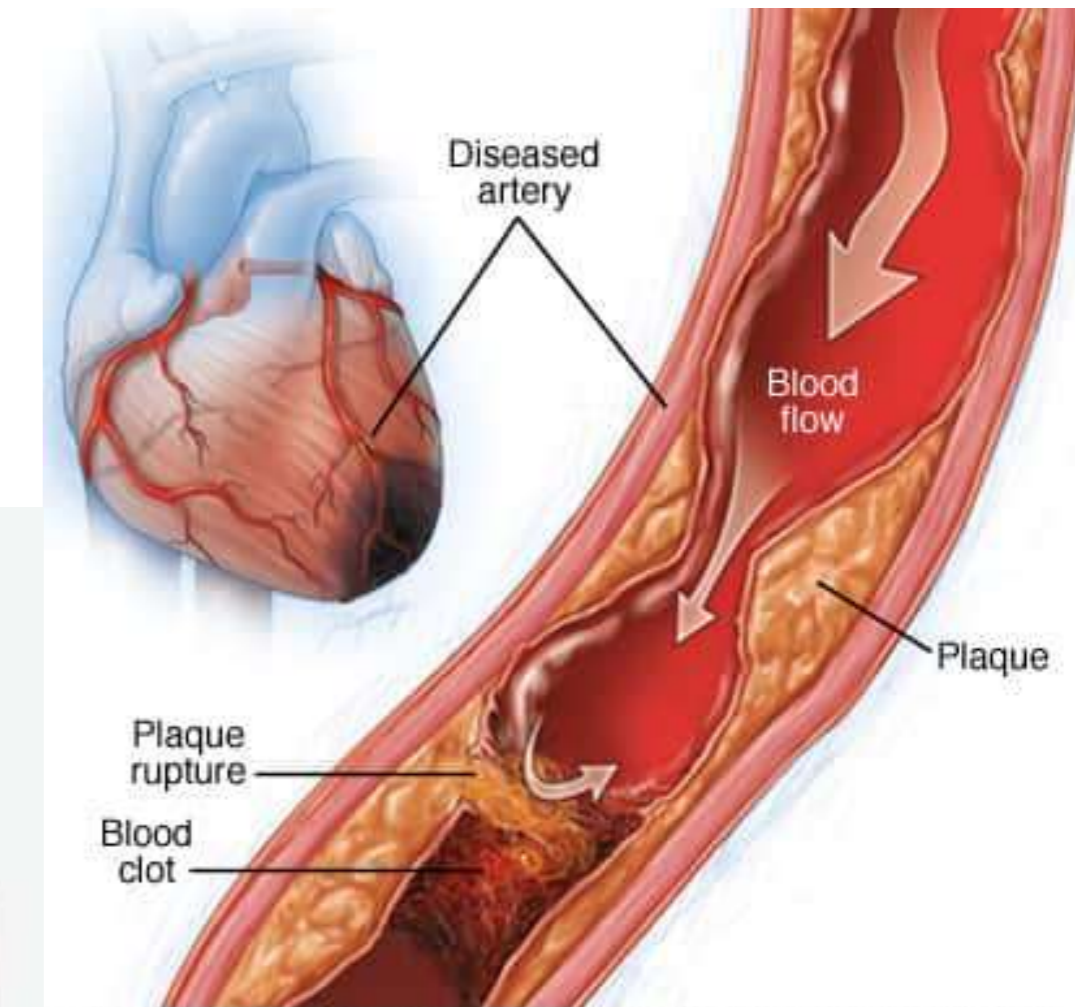
Radiation

Electric Shock

Thermal Injury



shutterstock.com · 1847158267



© MAYO FOUNDATION FOR MEDICAL EDUCATION AND RESEARCH. ALL RIGHTS RESERVED.



Causes of Cell Injury



Chemical Agents

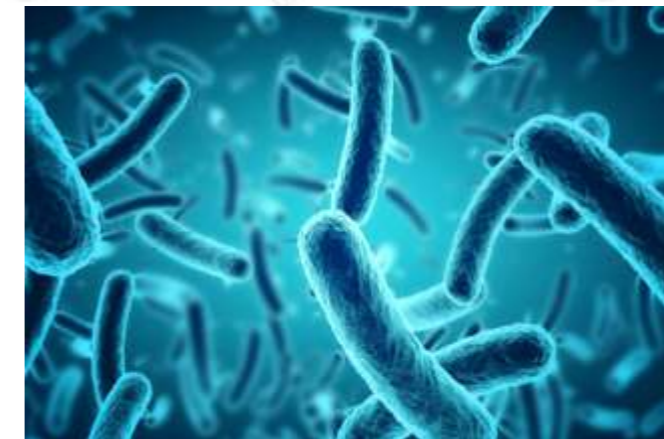- Free Radicals
- Poisons
- Therapeutic Drugs
- Pollutants, Industrial and Occupational Hazards
- Alcohol and Cigarette smoking
- Iatrogenic



shutterstock.com · 206390296

Infectious Agents

- Viruses
- Bacteria
- Fungi and Parasites





Causes of Cell Injury

Immunological Reactions

Allergic reactions

Autoimmune Diseases

Genetic disorders

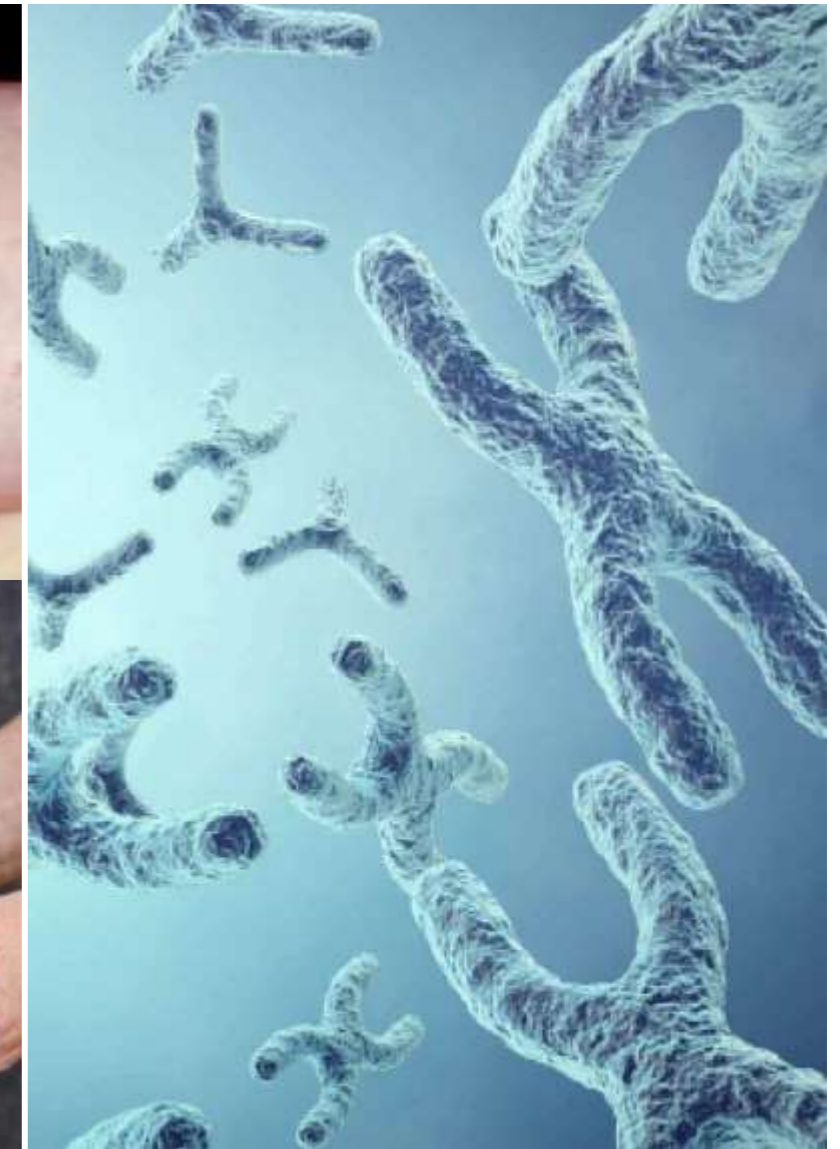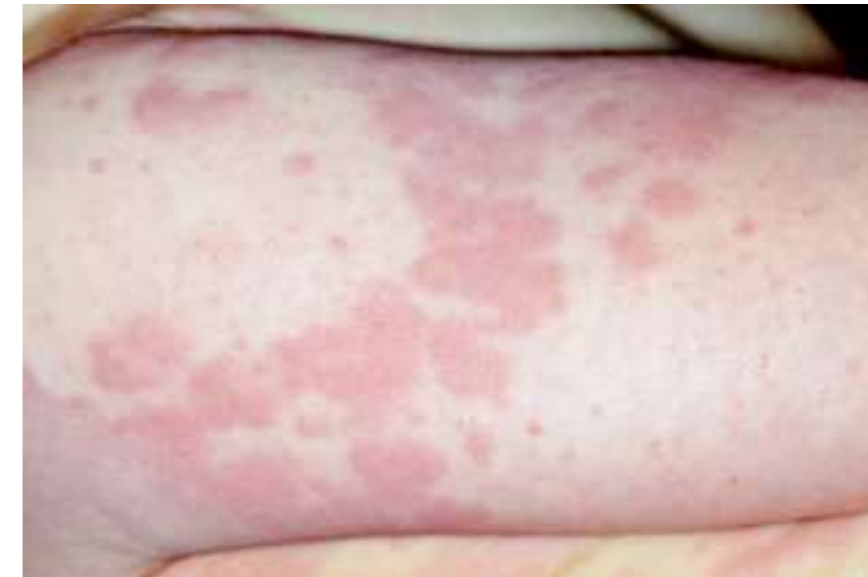
Chromosomal Abnormality

Genetic Mutations

Nutritional Imbalances

Protein Calorie Malnutrition

Nutritional excess (obesity)



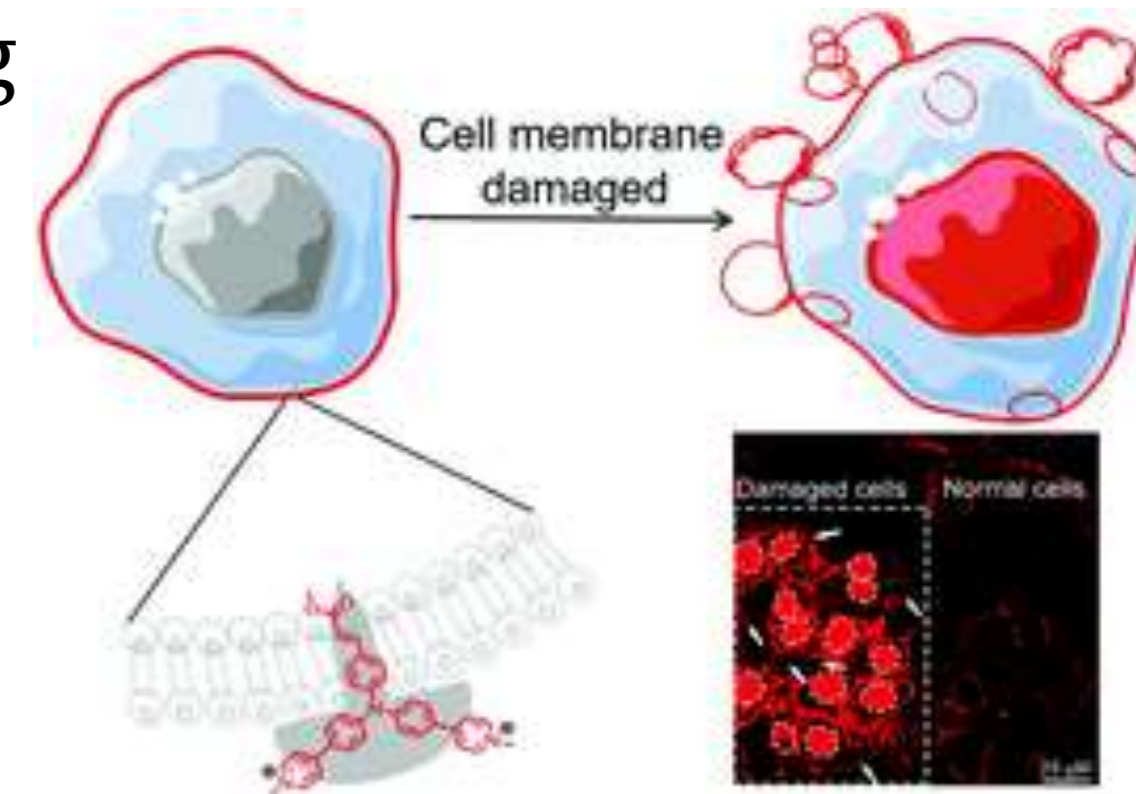
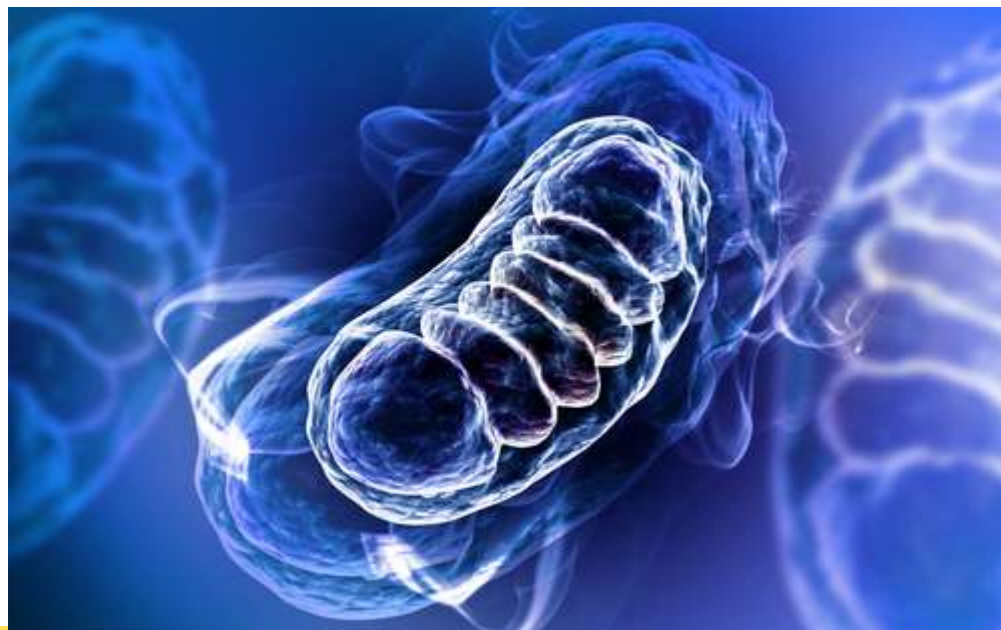

Pathogenesis of Cell Injury



General Principles of Pathogenesis

- Type, duration and severity of injurious agents
- Type, status and adaptability of target cells
- Underlying intracellular phenomena – mitochondrial damage, cell wall damage, free radicals
- Morphological consequences – structural changes, swelling



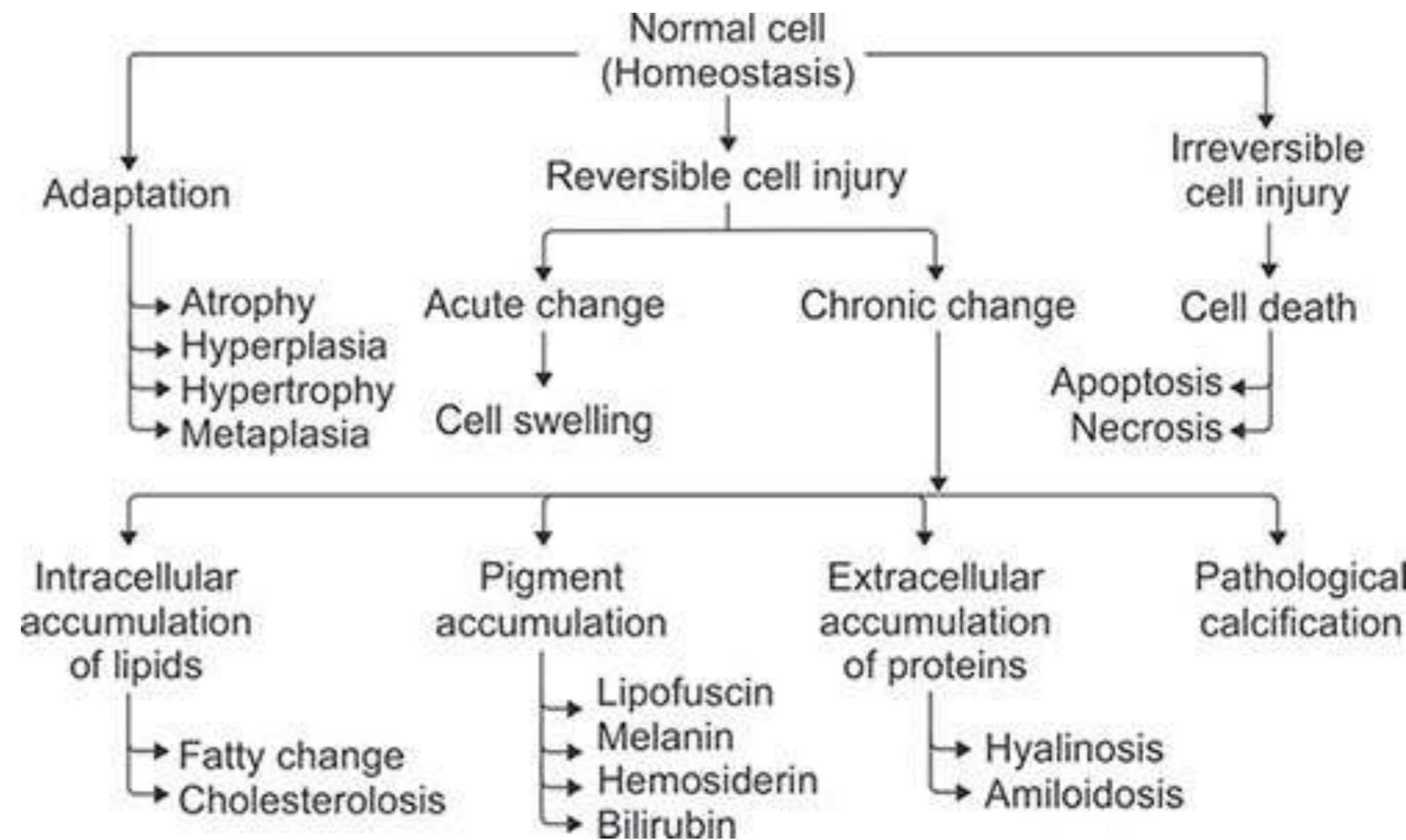


Types of Cell Injury



Injury at one point induces a cascade of effects

- Cellular Adaptation
- Reversible Cell Injury
- Irreversible Cell Injury
- Subcellular changes and Intracellular Changes





Reversible Cell Injury



Reversible cell Injury:

- Cell injury produces changes in the cells which are reversible up to a certain point
- This injury occurs, when the stimulus is acute or mild

Microscopic features of reversible cell injury – **cell swelling and fatty change**

Cell swelling – it is due to changes in ion concentration and fluid homeostasis ---->fluid filling into cell

Cloud Swelling Gross appearance of organ

Causes : Bacterial toxins , Chemical poisons and mal nutrition

Organs involved: Kidney, Liver, Heart and muscle



Steatosis (Fatty Change)



- Abnormal accumulation of triglycerides within parenchymal cells
- **Organs involved:** Liver, Muscle, Heart and Kidney

Fatty Liver

- **Disorders of Hepatocyte cell** - Alcohol abuse, protein mal nutrition, starvation, hypoxia (anaemia, cardiac failure), toxins.
- **Disorders with hyperlipidaemia** – Obesity, diabetes mellitus or congenital hyperlipidaemia
- Gross appearance – Liver enlarged, yellow, soft and greasy to touch
- Microscopy – small vacuoles in the cytoplasm around the nucleus

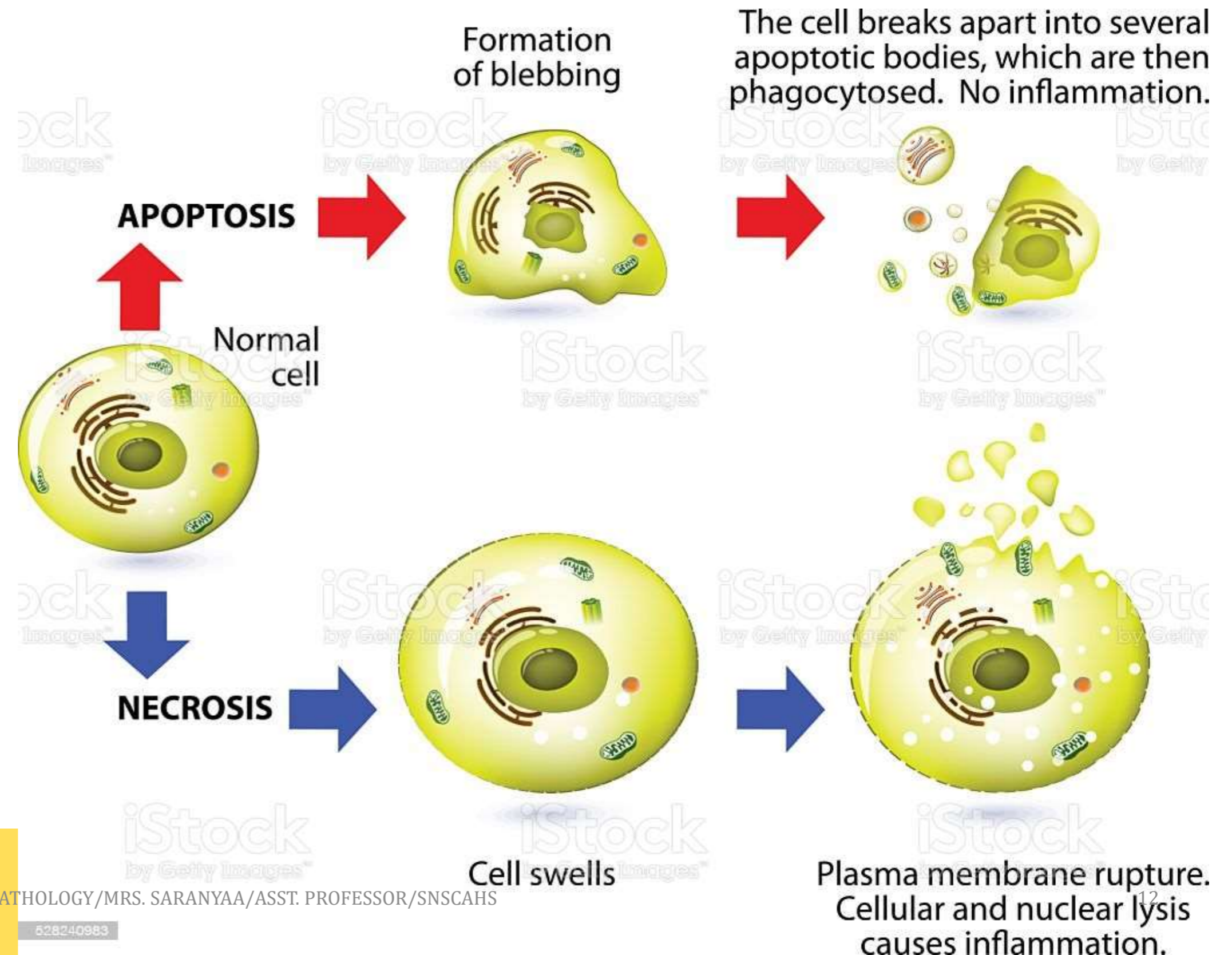
Heart – Atherosclerosis formation because of fat deposition in the coronary arteries, that appears like a yellow myocardium

Irreversible Cell Injury

If the cell is exposed to continuous injurious stimulus or if the injury is severe, the cells undergo cell death.

Necrosis – A cell death which is of pathologic process

Apoptosis – A Cell death which is of physiological or called as programmed cell death





Necrosis



- Necrosis is a **morphological changes indicative of cell death in a living tissue.**
- It occurs in case of extremely harmful injury

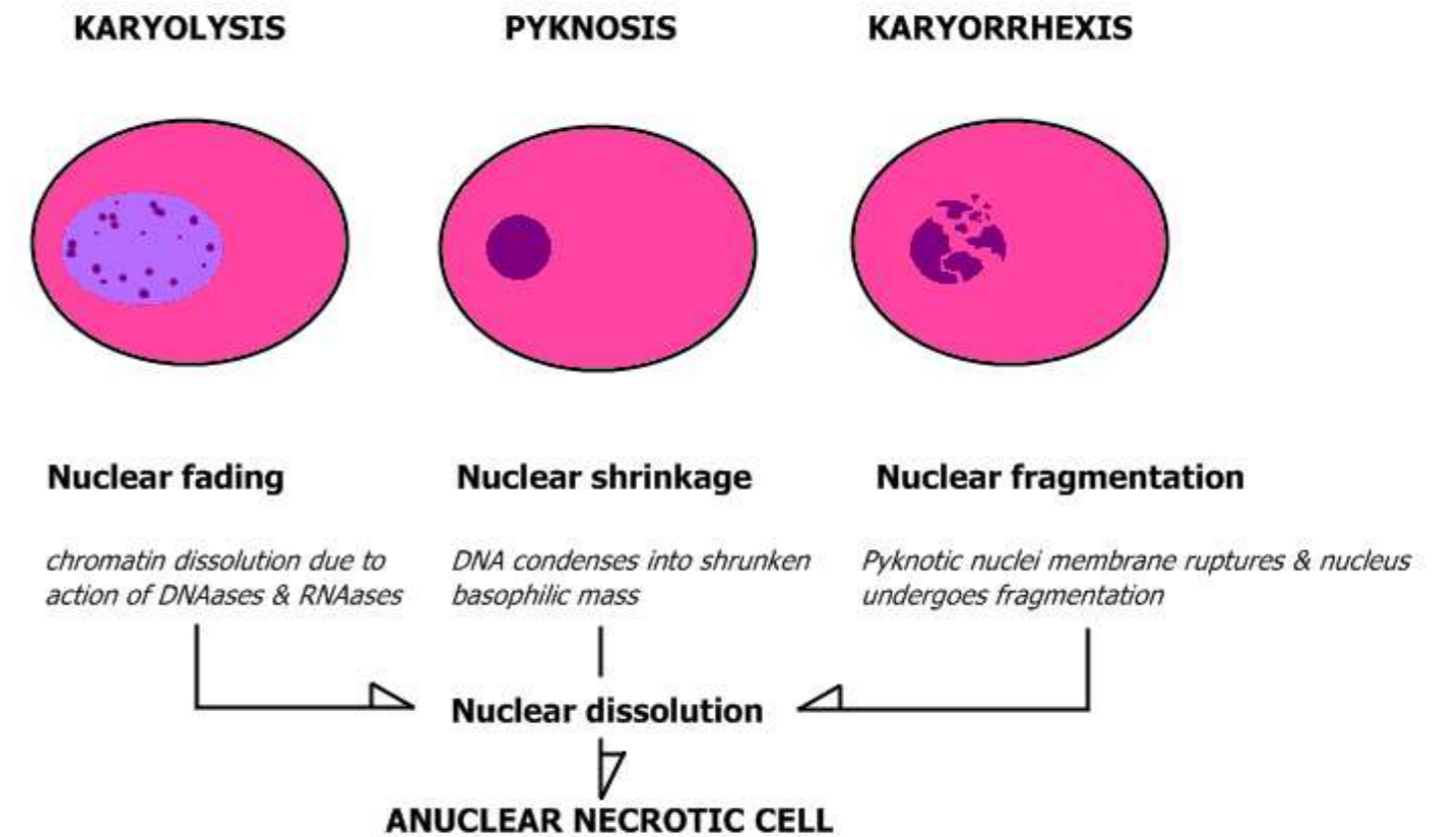
Structure:

- Cytoplasmic changes – Increased Eosinophilia
- Nuclear changes

→ **Pyknosis** (shrinkage of nucleus)

→ **Karyolysis** (progressive fading of basophilic staining of nuclei) that leads to ghost nuclei

→ **Karyorrhexis** (pyknotic nuclei breaks up into many smaller fragments)





Types of Necrosis



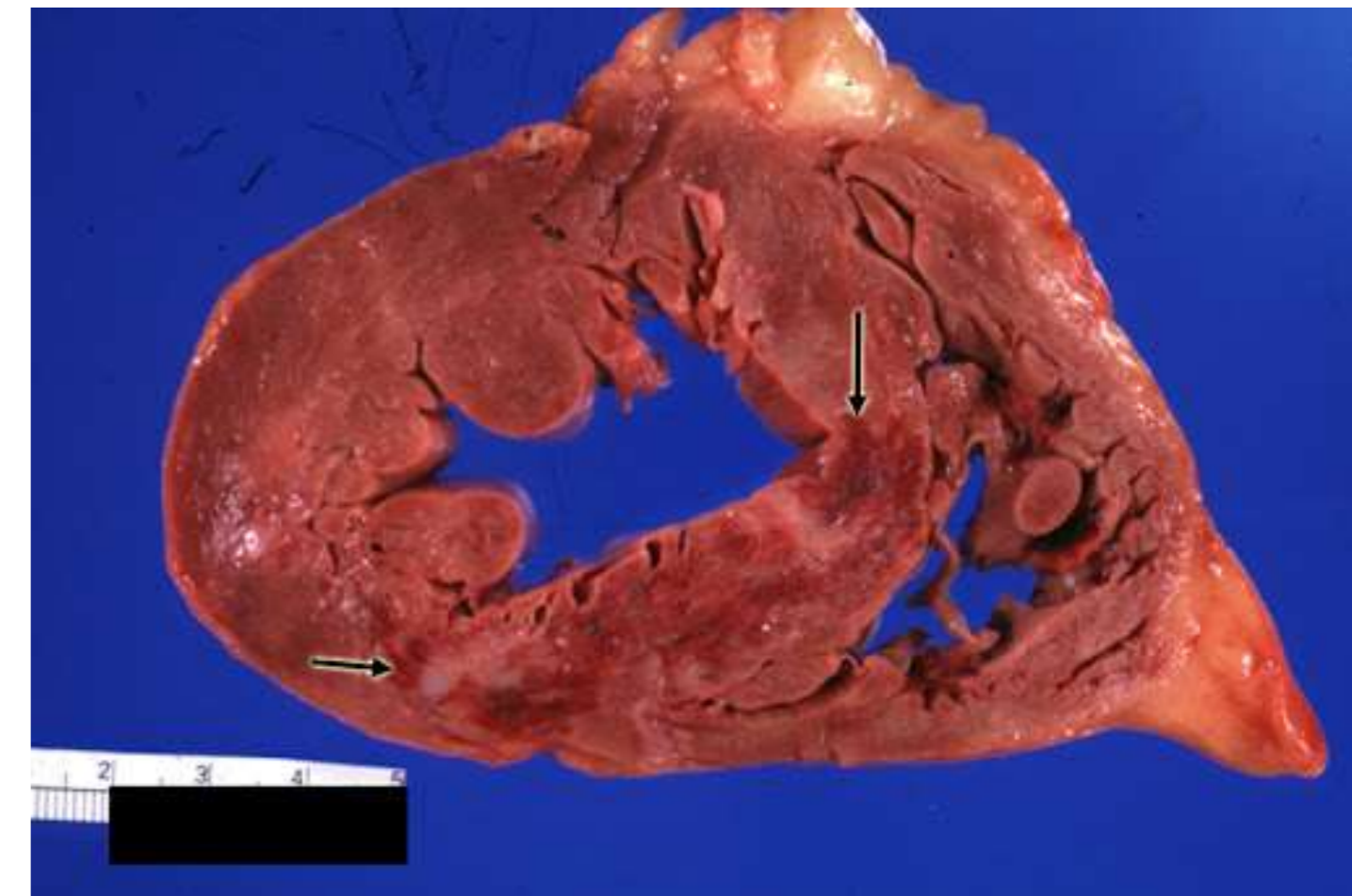
- Coagulative Necrosis
- Liquifactive Necrosis (Colliquative Necrosis)
- Caseous Necrosis
- Fat Necrosis
- Fibrinoid Necrosis
- Gangrenous Necrosis



Coagulative Necrosis

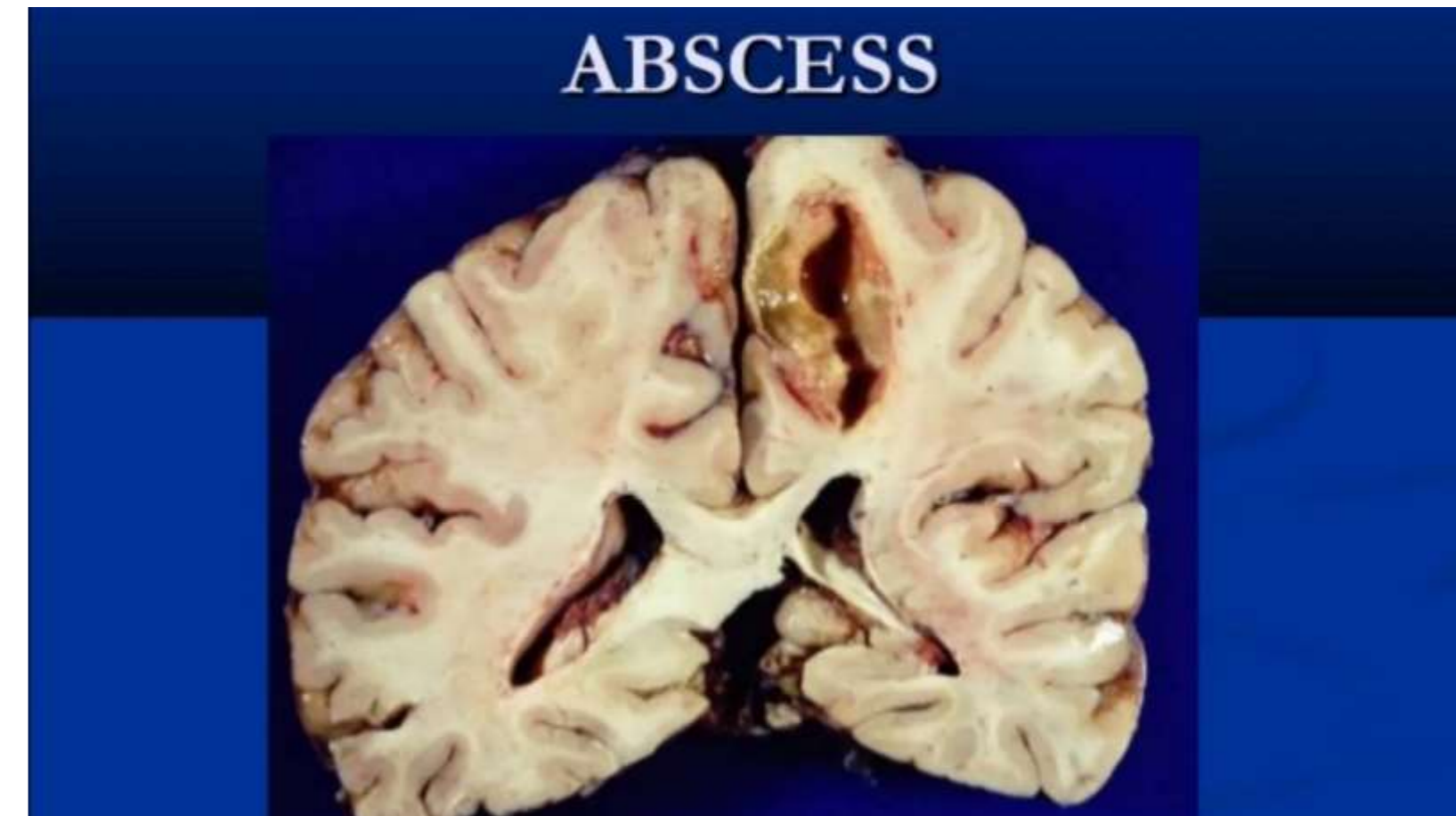


- It is a type of necrosis, where the outline or **cytoskeletal of dead tissue is preserved** for few days.
- A localized area of coagulative necrosis is known as **infarct**
- **Causes** – Ischemia (bacterial toxins, obstruction of vessels)
- **Gross Appearance** – dry, pale, yellow and soft
- **Organs Involved** - Heart, Kidney and Spleen



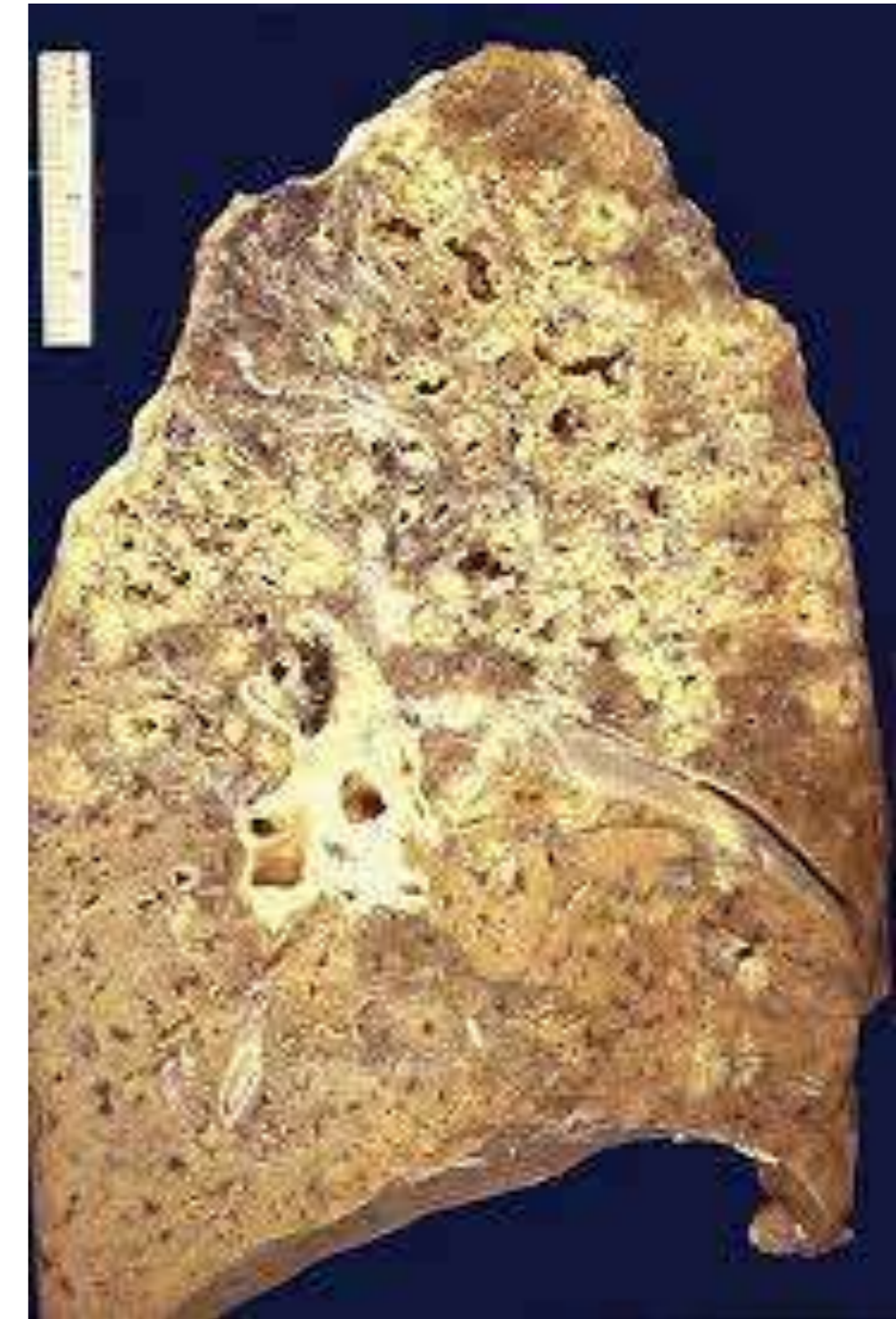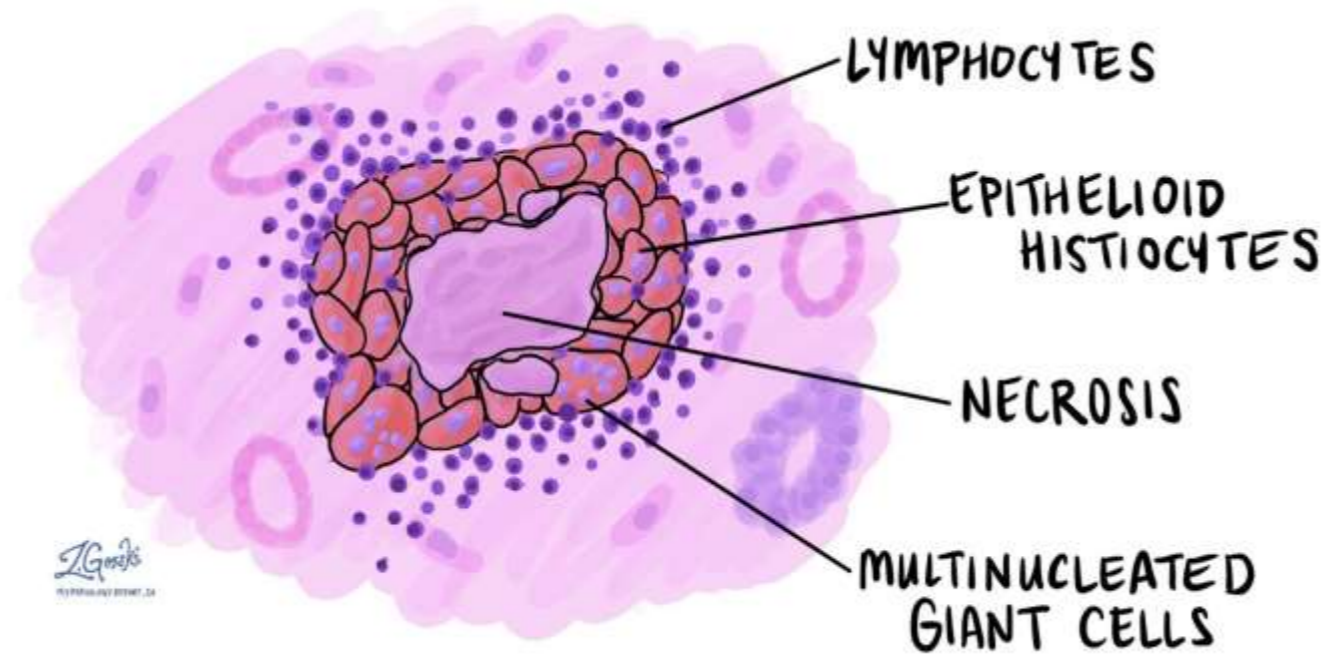
Liquefactive Necrosis

- Dead tissue rapidly undergoes **softening and transformed into liquid viscous mass**
- **Cause** – Ischemic injury to CNS, Suppurative Infections by bacteria
- **Organs affected** - Brain Abscess
- **Microscopic** – Pus consists of liquefied necrotic cell debris, dead leukocytes and macrophages.



Caseous Necrosis

- **Combination of both coagulative and liquefactive necrosis**
- **Cause** – tuberculosis and hypersensitivity reactions
- **Organs affected** – Lung and Lymph nodes
- **Appearance** – yellowish, white soft granular, friable, clumpy cheese
- **Microscopy** – granuloma





Fat Necrosis



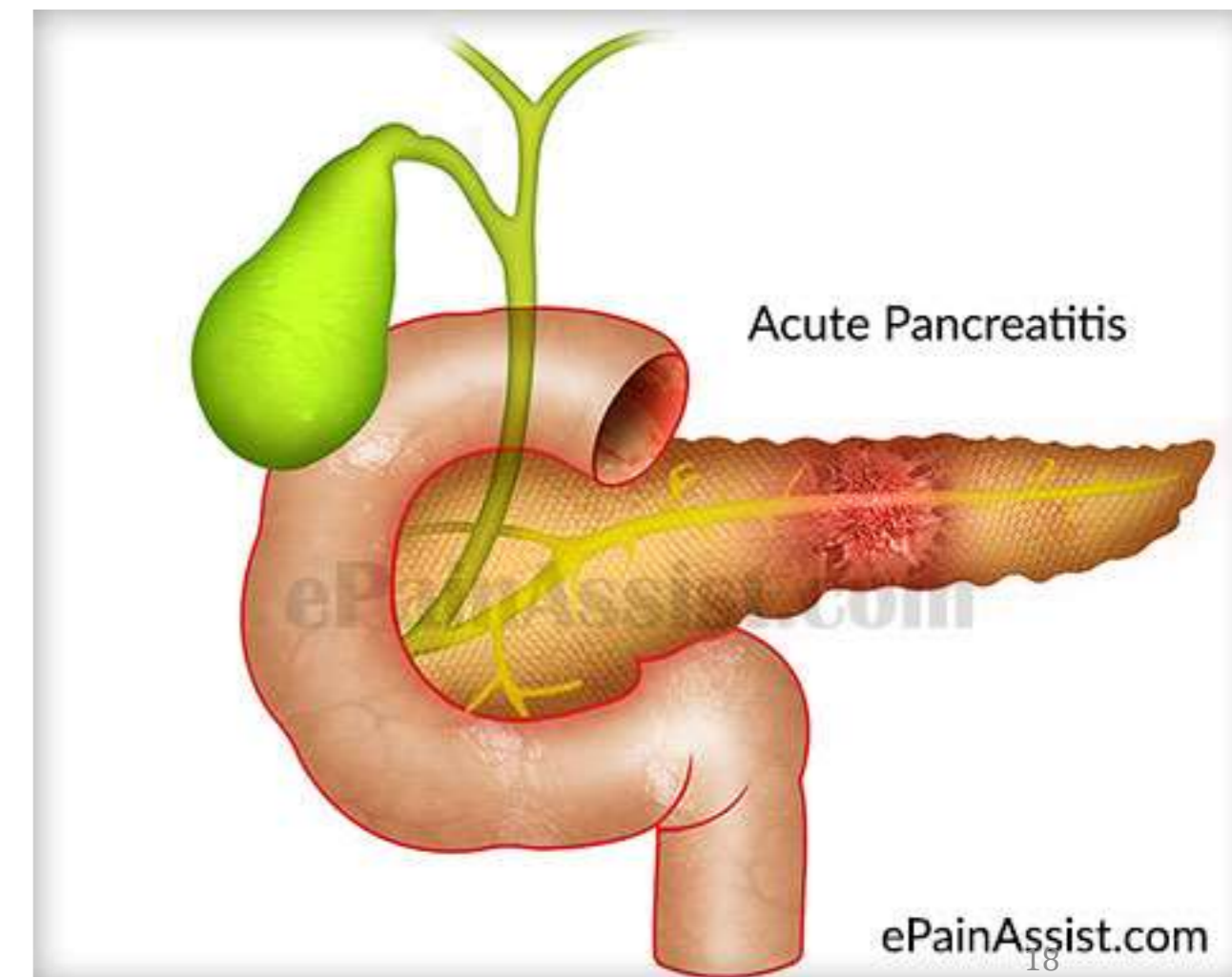
- It refers to a **focal areas of fat destruction**, which affect adipose tissue.
- Types – enzymatic and traumatic

Enzymatic fat necrosis

- Peculiar to adipose tissue around inflamed pancreas (acute pancreatitis)
- Enzyme leak from injured pancreas, causes tissue damage
- Appearance – chalky white areas

Traumatic Fat Necrosis

- It occurs in tissues with high fat content
- Occurred in breast and thigh, with severe trauma

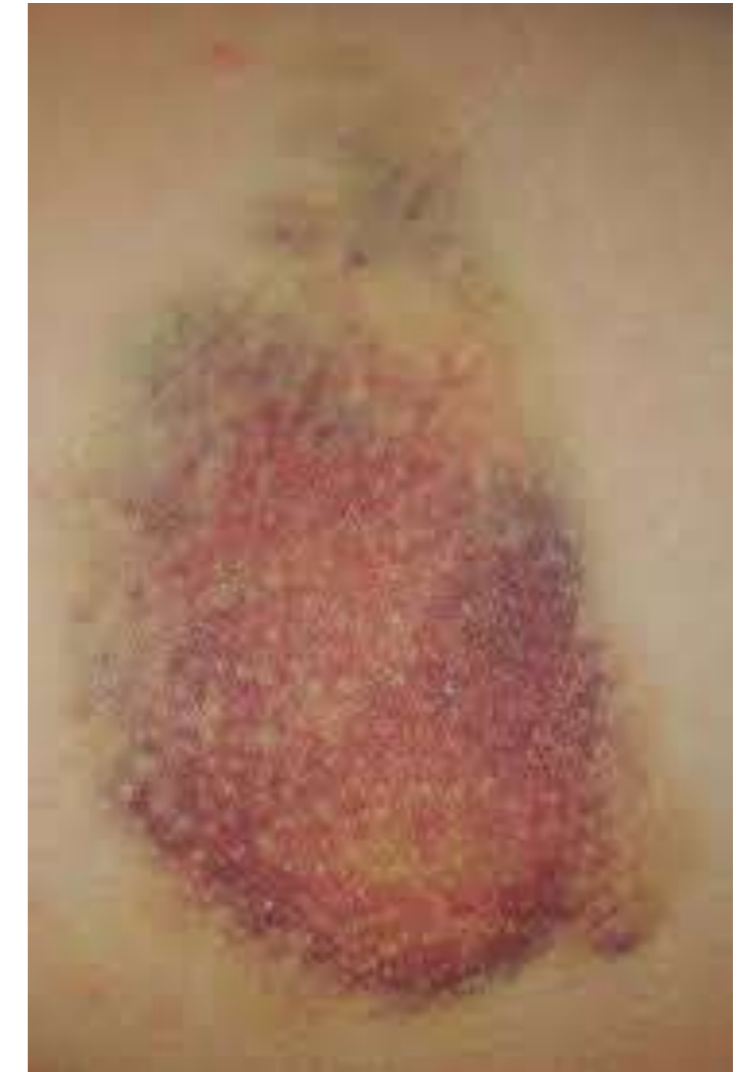



Fibrinoid Necrosis



- Deposition of pink – staining (fibrin like) proteinaceous material
- It involves arteries and walls of arterioles and glomeruli of kidney





Gangrene (Gangrenous Necrosis)



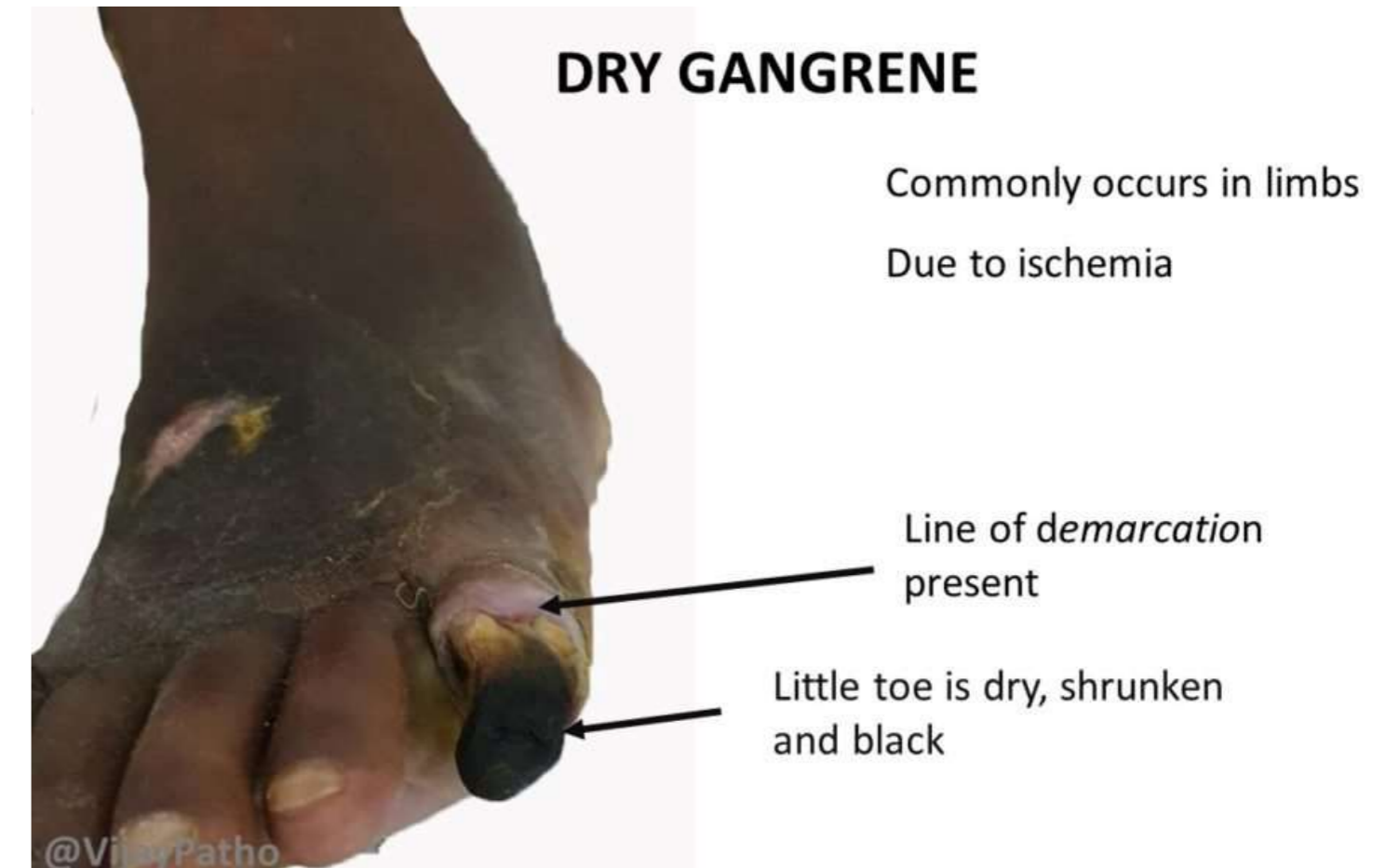
- Gangrene is defines as **massive necrosis with superadded putrefaction**
- Putrefaction is the decomposition of microorganisms ----->> with **foul smelling substance and gas**

Types of gangrene

- Dry gangrene
- Wet gangrene
- Gas gangrene

Dry Gangrene

- **Cause:** Arterial occlusion (atherosclerosis)
- **Site:** Limb
- **Gross appearance :** dry, shrunken, dark brown or black in color
- Black color is due to **iron sulfide**
- A line demarcation is usually seen between gangrenous and adjacent area

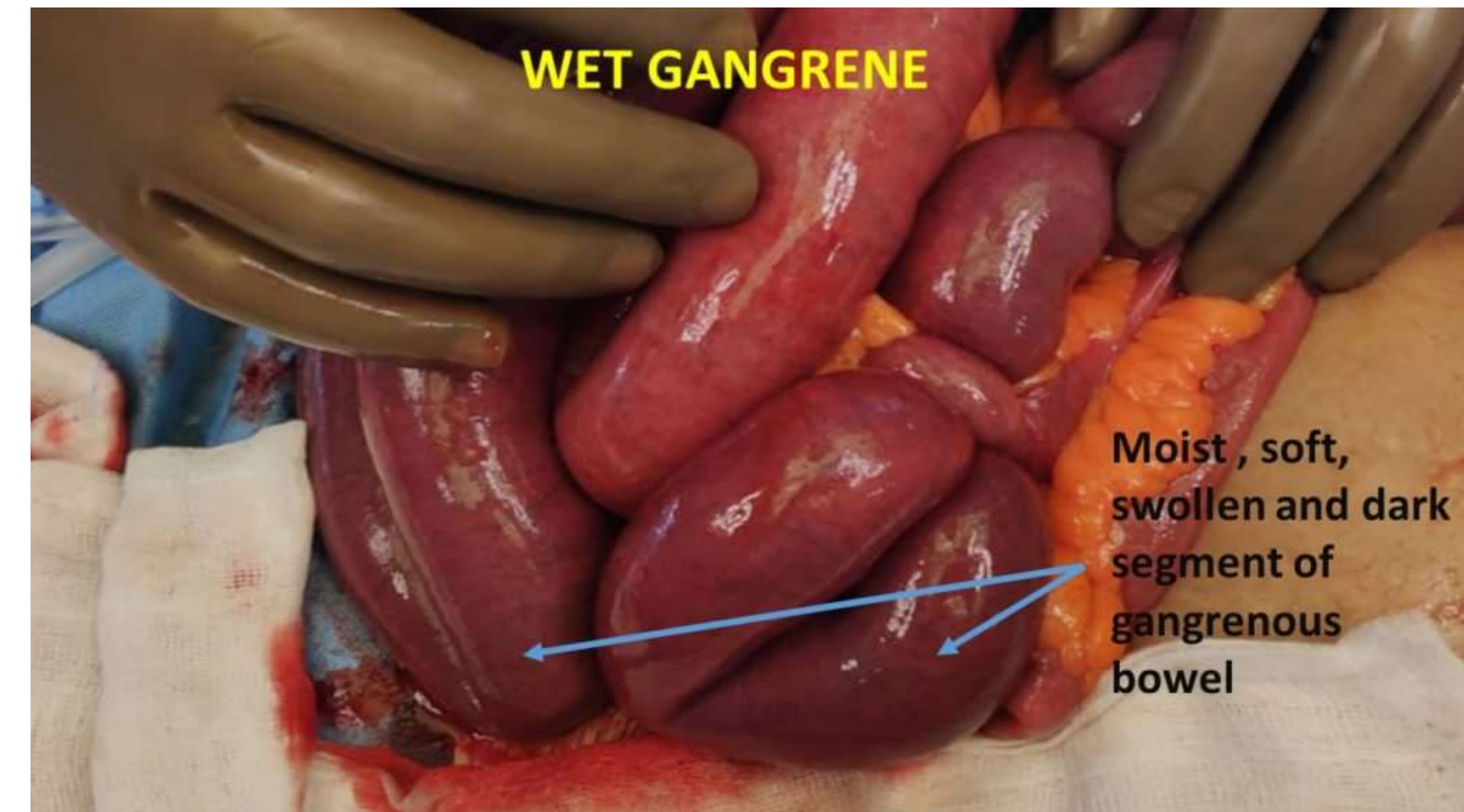




Wet Gangrene



- Occurs in moist tissue or organs (bowel, lung and mouth)
- It occurs due to **venous blockage**
- In diabetes, the gangrene foot is of wet type because of the **higher sugar content in the necrotic tissue which favors growth of bacteria**
- **Appearance** – soft, swollen, rotten and dark
- No clear line of demarcation between the gangrenous part and viable part

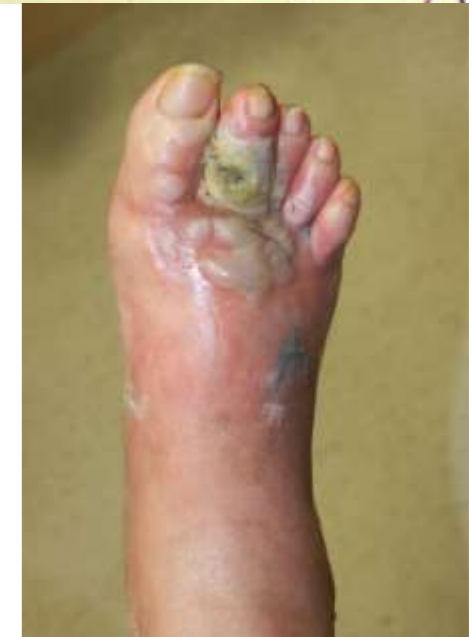
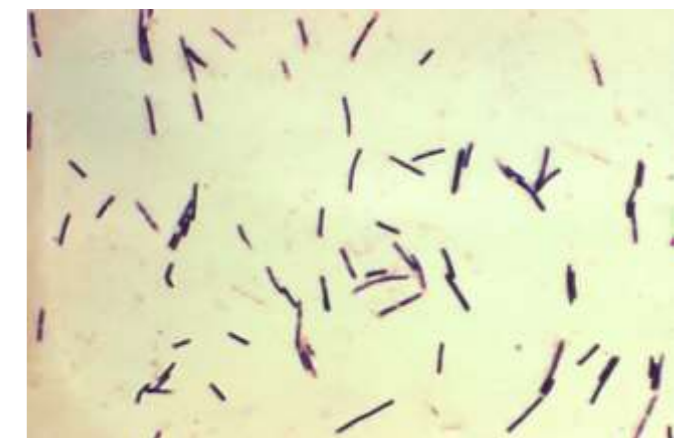


Gas Gangrene



- A very deadly form of gangrene
- Usually caused by Clostridium perfringens bacteria
- Infection spreads quickly due to the gas production by the bacteria, rapidly contaminate the tissues nearby
- Rapidly spreads through the body
- Toxins will cause tissue death and sepsis very quickly
- It is a deep wound infection
- Pale skin evolving with **purplish-red or grey in color**





Treatment for Gangrene



- Treat for Septic Shock
- Oxygen
- IV fluids
- Consider dopamine to correct hypotension
- Consider pain meds
- Antibiotics

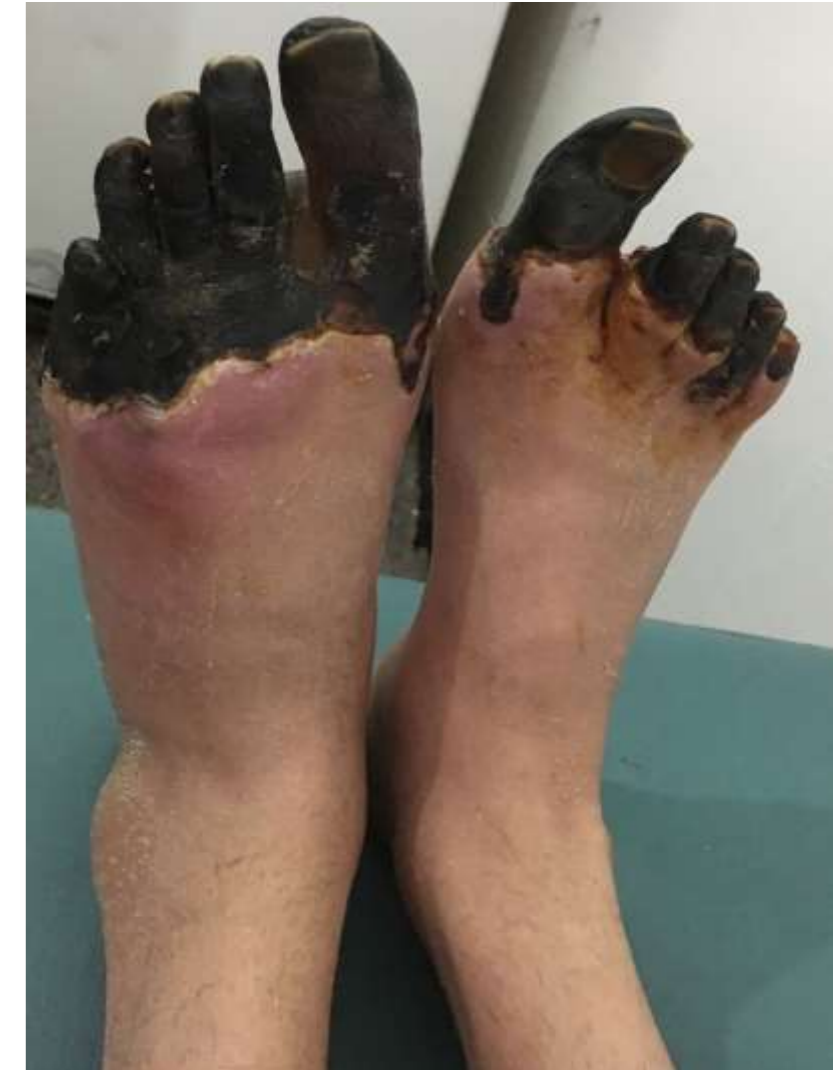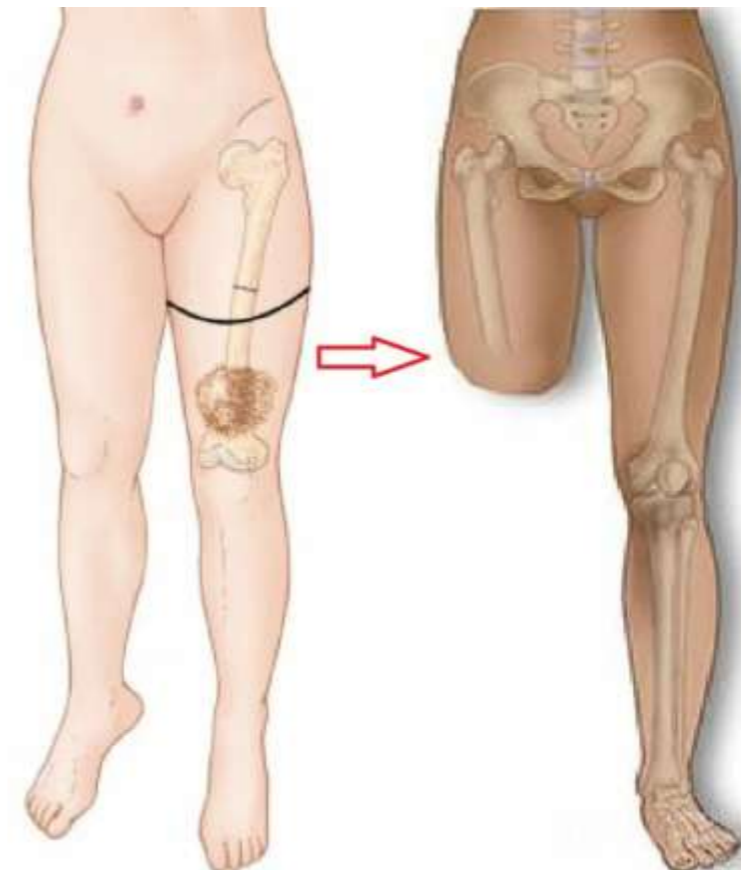
Treat for,

- Fever or low temp (hypothermic)
- Increased cardiac output
- Low BP
- Shortness of breath
- Possible altered mental status



Treatment for Gangrene

- Complete amputation
- Hyperbaric oxygen therapy
- Forcing oxygen rich blood into the dying tissue
- Kills off the bacteria that thrive only in an oxygen free area.
- Diabetics should be controlled

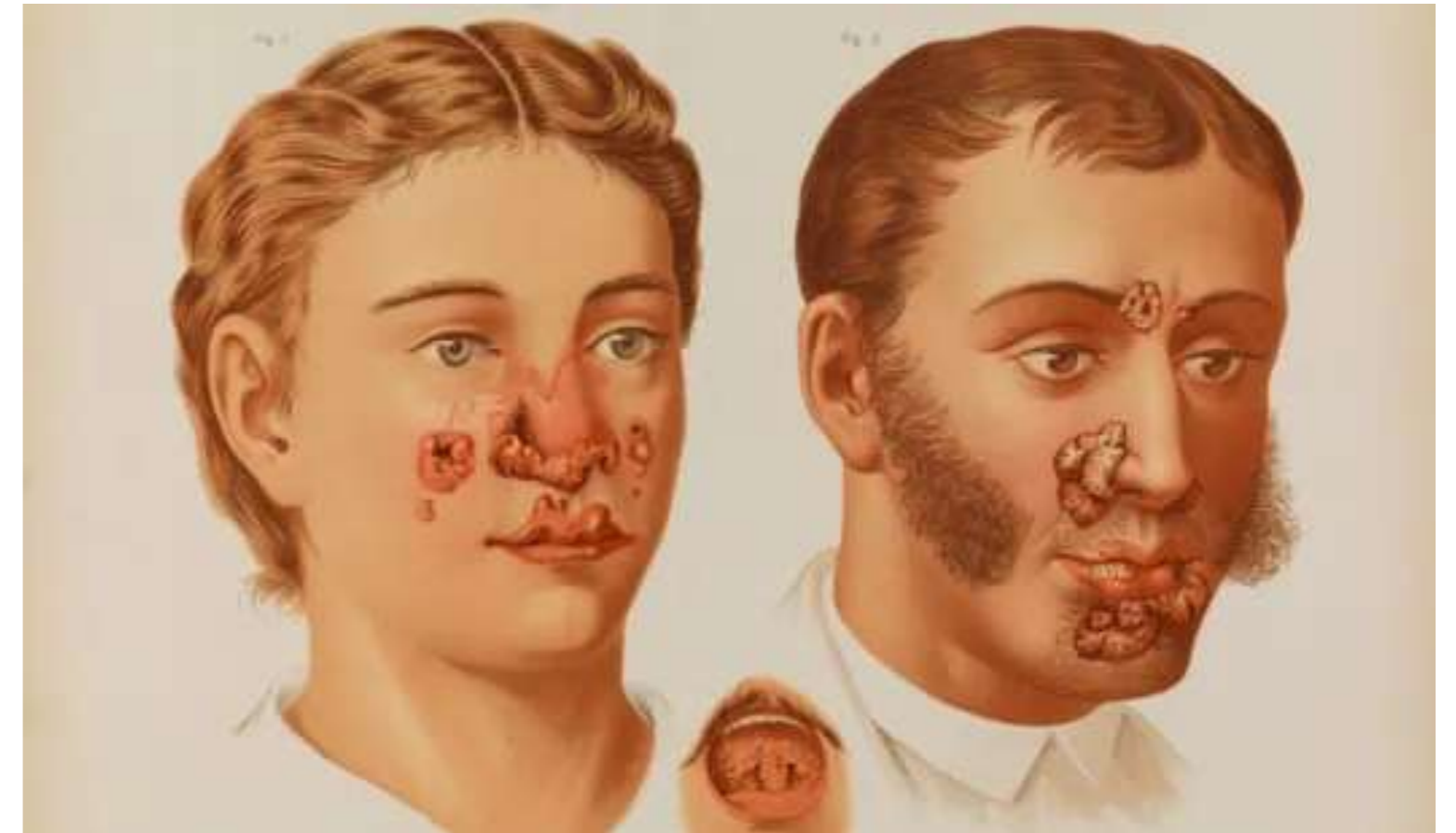




Granulomatous Necrosis

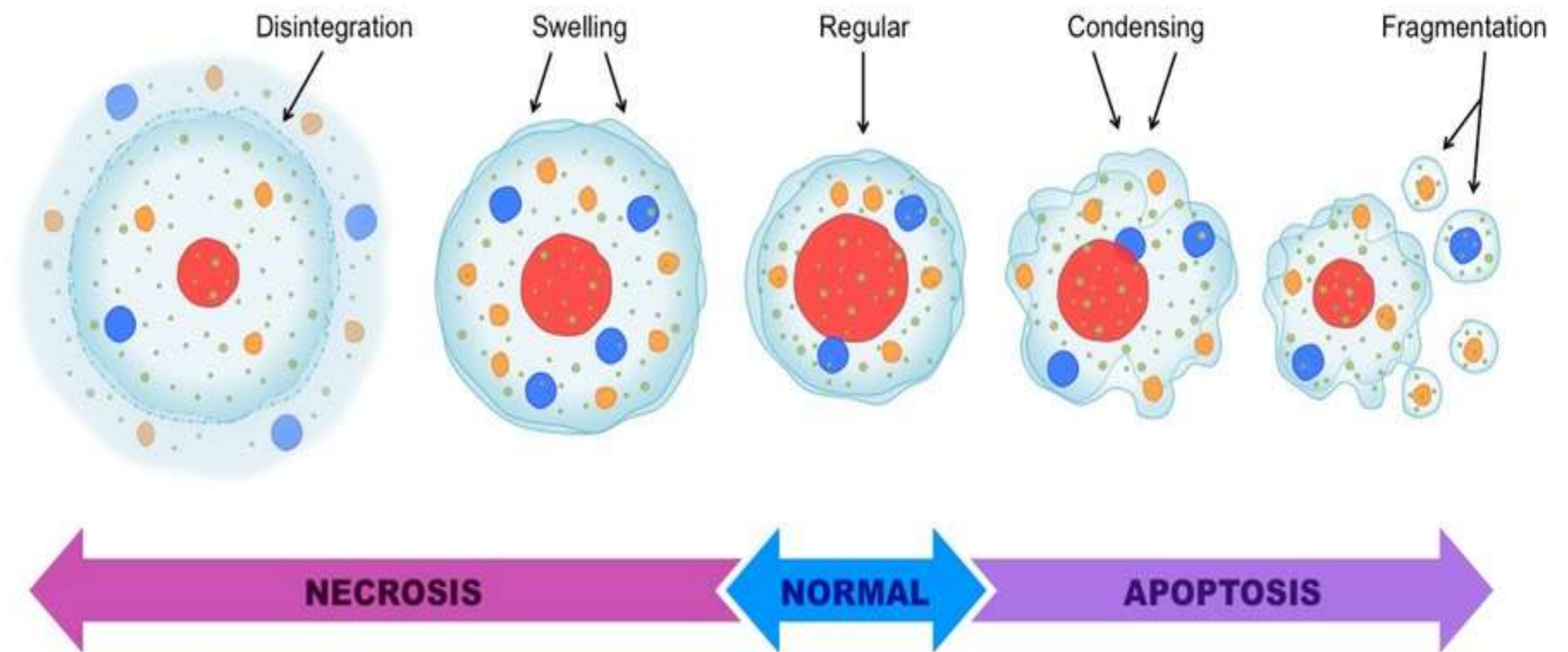


- The necrotic tissue is firm and rubbery and the original architecture can be seen on histological examination.
- It is usually found in syphilis



Apoptosis

Apoptosis is a type of cell death in which cells **activate enzymes** that degrade the cell's own nuclear DNA and nuclear and cytoplasmic proteins





Activation of Apoptosis

- Apoptosis is activated by either withdrawal of positive signals or arrival of negative signals.
- Positive signals → survival of cells
- Negative signals →
 - damage of DNA
 - Viral infection
 - Cellular stress
 - Exposure of UV rays, X - rays




Types of Apoptosis



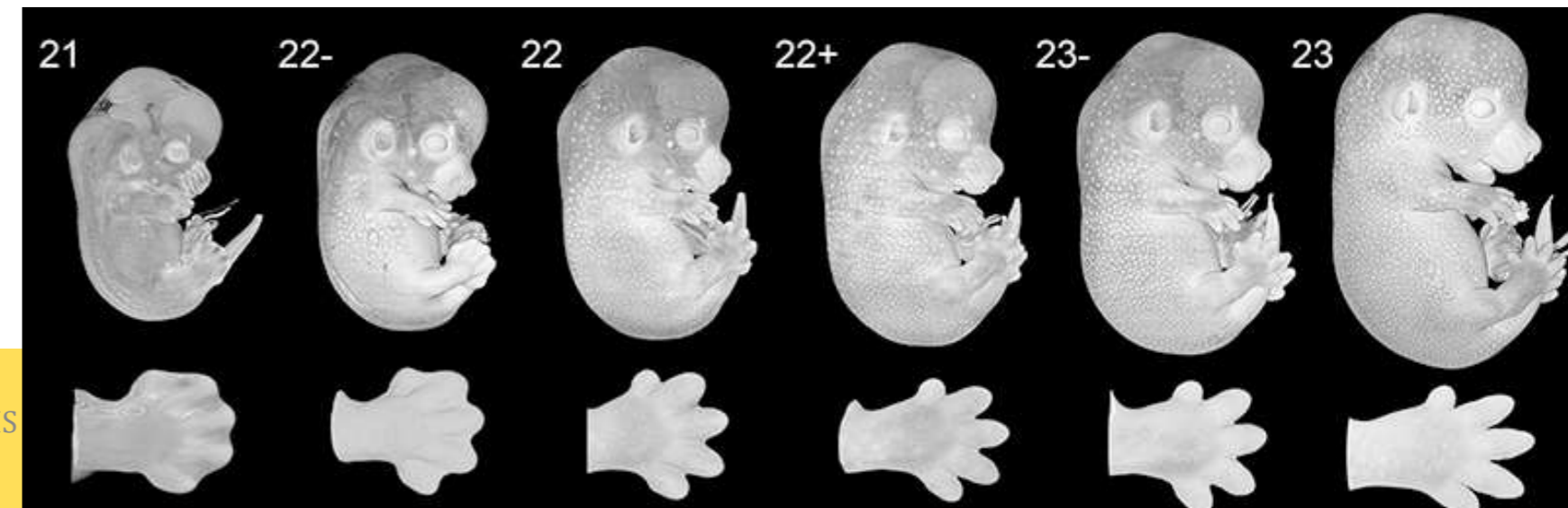
Physiological Situation:

- Apoptosis is a physical process during **embryogenesis**, development and throughout childhood
- Removal of excess cells during embryogenesis and helps in developmental process (eg) **web tissues into fingers and toes**
- Elimination of cells after withdrawal of hormonal stimuli – endometrial cell breakdown during **menstrual cycle**
- Elimination of potential harmful cells – **self reactive lymphocytes**
- Elimination of cells after its life span – **RBC Destruction** after 120 days



shutterstock.com • 633717578

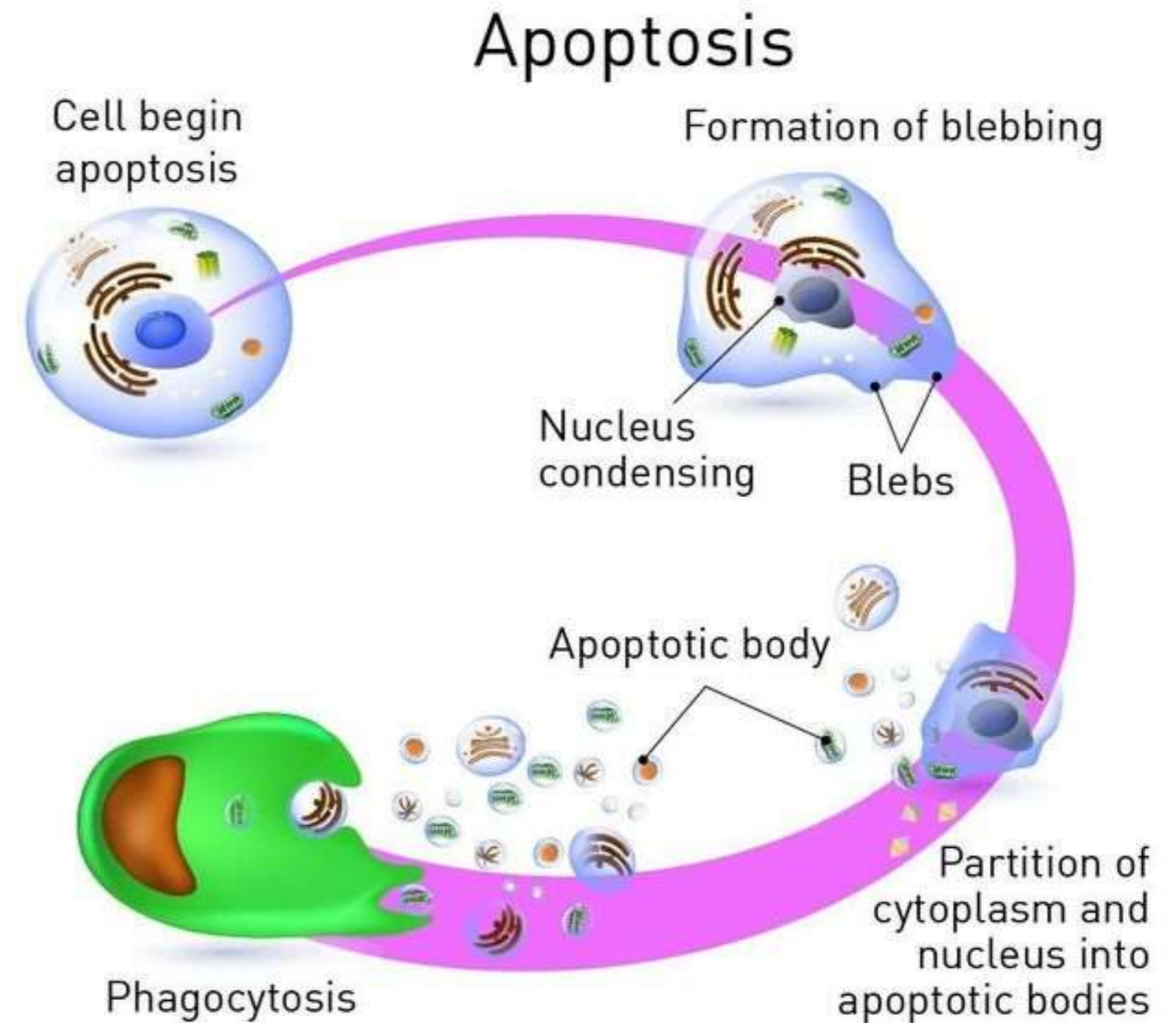
CELL INJURY/PATHOLOGY/MRS. SARANYAA/ASST. PROFESSOR/SNSCAHS



Types of Apoptosis

Pathological Situations:

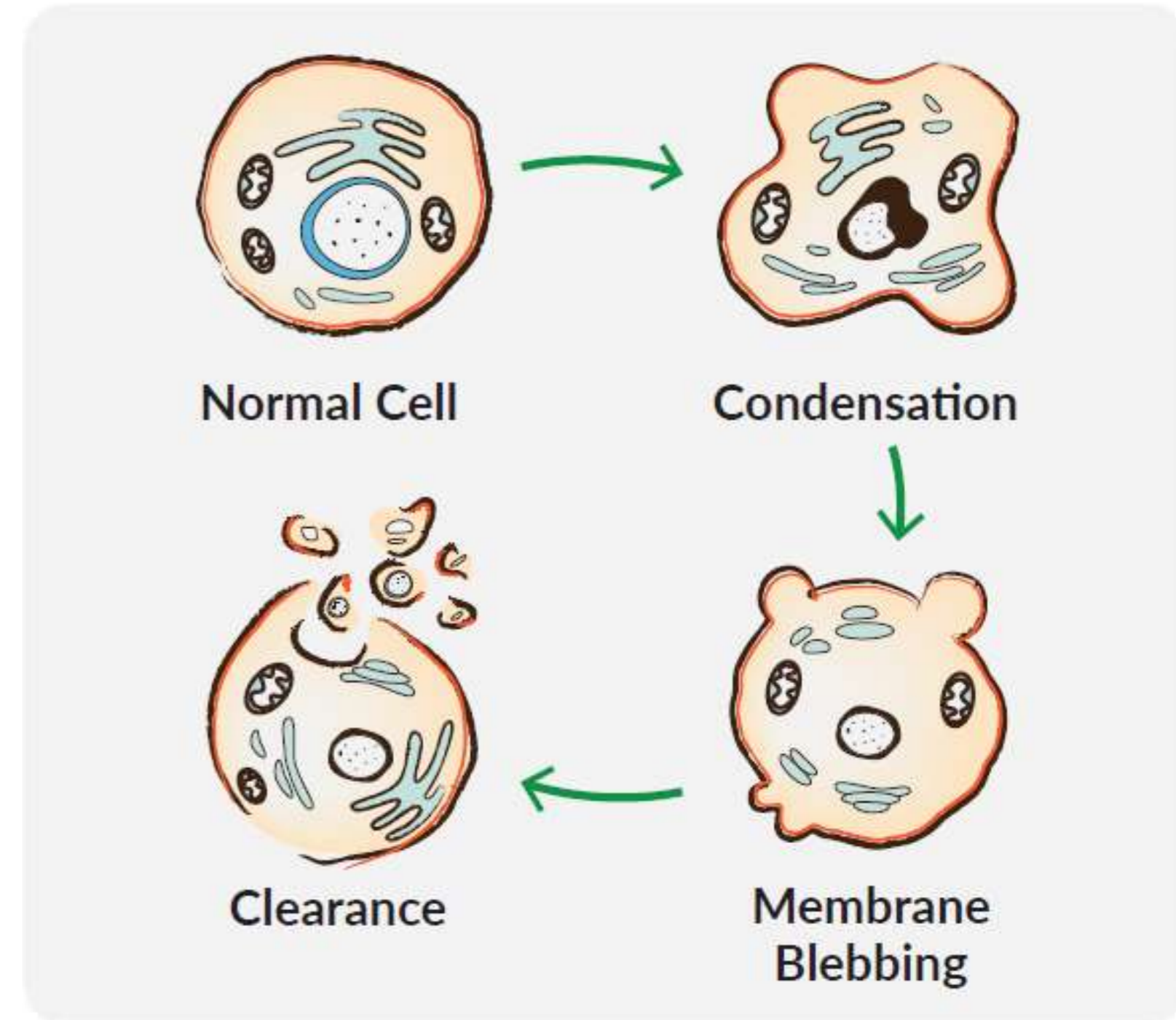
- Elimination of cells with damaged DNA
- Killing of Infected Cells
- Elimination of Neoplastic cells



Morphology of Apoptosis

On Electron Microscope:

- **Cell shrinkage** – cells shrink and cytoplasm become dense
- **Nuclear Condensation and Fragmentation** – chromatin aggregates peripherally, under the nuclear membrane
- Nucleus breaks down into more fragments
- **Formation of cytoplasmic blebs and apoptotic bodies** – extensive surface blebbing followed by formation of apoptotic bodies





Morphology of Apoptosis

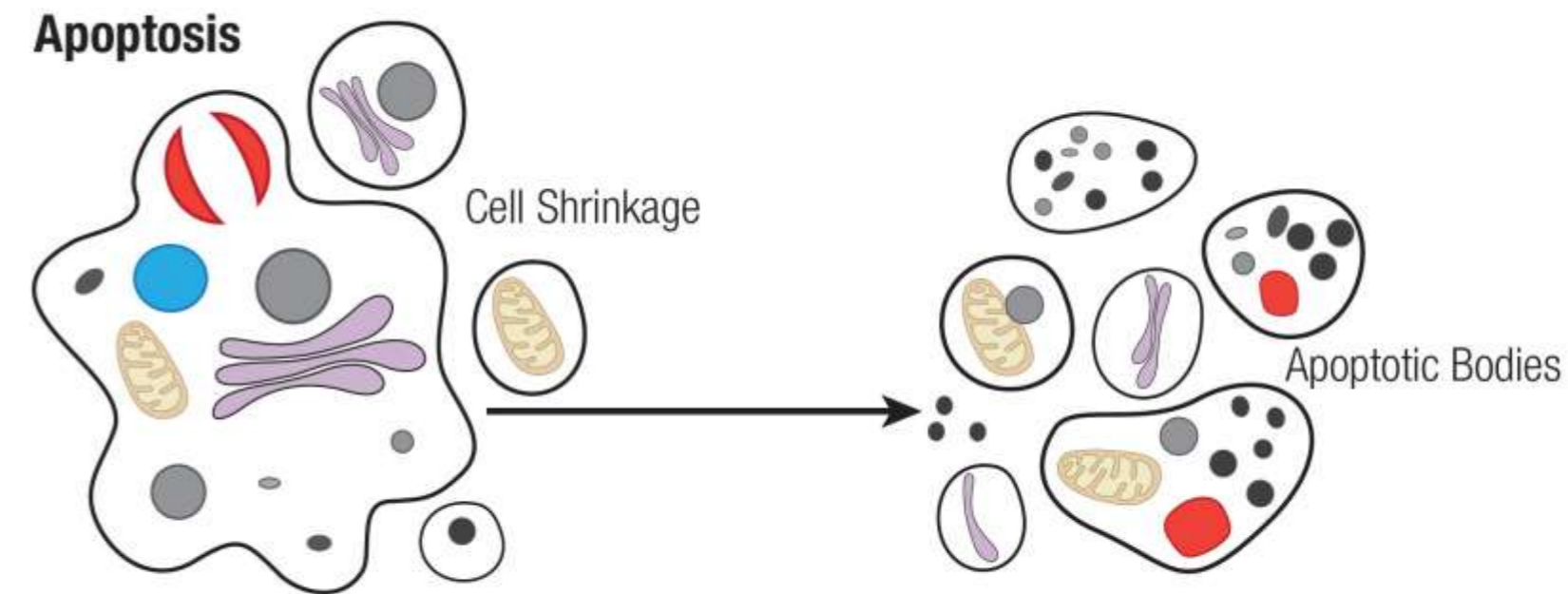


- The Apoptotic body contains cytoplasm and tightly packed organelles
- **Phagocytosis of apoptotic body** – Cell engulfing occurs by lysosomal enzymes

Light Microscopy:

The apoptotic cells appear as a round or oval mass having intensely **eosinophilic cytoplasm**.

The nucleus appear as fragments of dense nuclear chromatin and pyknotic.





Difference between Apoptosis and Necrosis



FEATURES	APOPTOSIS	NECROSIS
Cause	Physiological or Pathological	Invariably Pathological
Extent	Single or small cluster of cells	Involves group of cells
Nucleus	Undergoes fragmentation	Pyknosis, Karyorrhexis and Karyolysis
Cellular Contents	Intact may be released in apoptotic bodies	Enzymatic digestion, may leak out of cell
Inflammatory Response	Absent	Usual in the adjacent tissue
Fate of dead cells	Ingested (phagocytised) by neighbouring cells	Ingested by neutrophils and macrophages