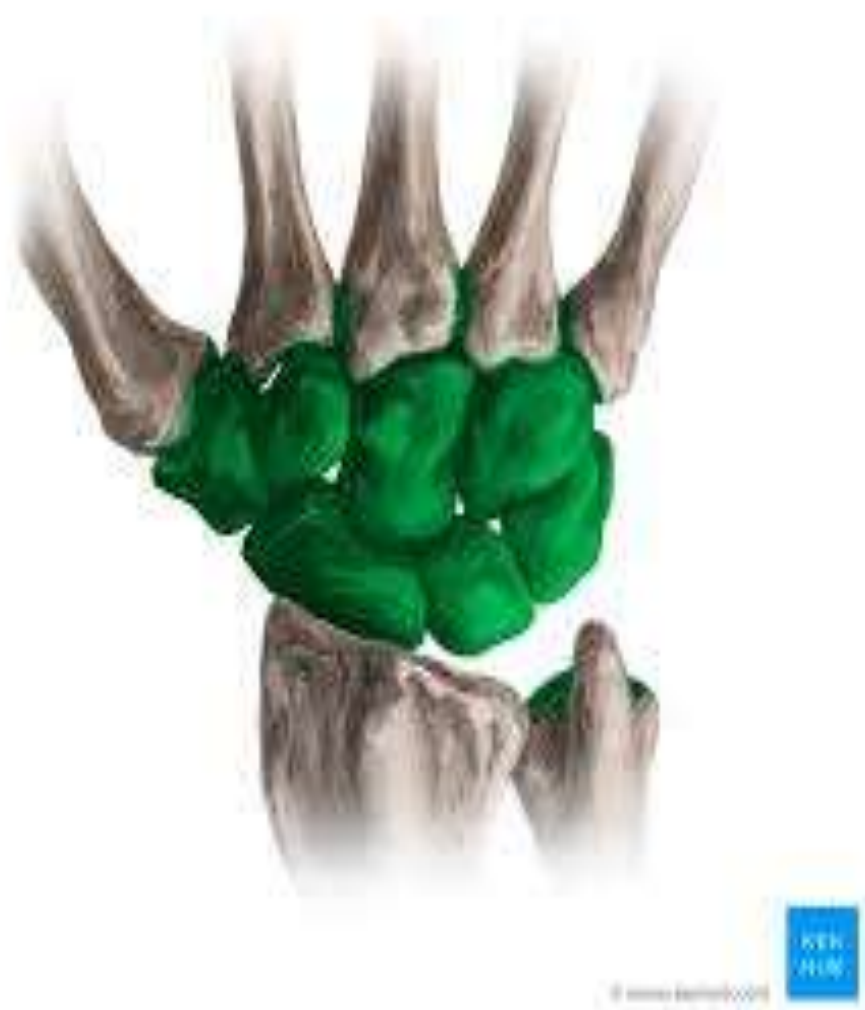



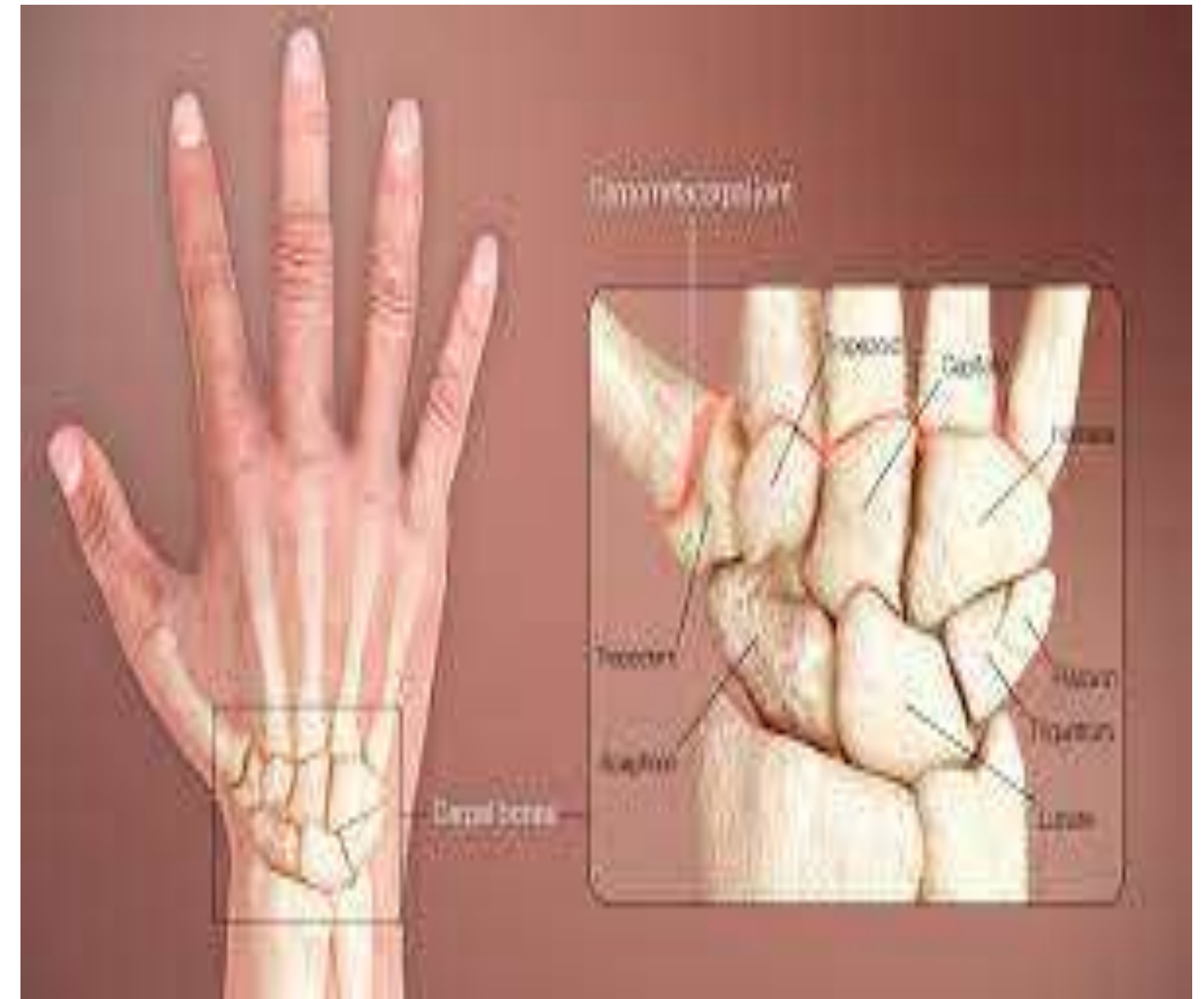# CARPAL BONES

## HOW IS OUR WRIST SO FLEXIBLE!



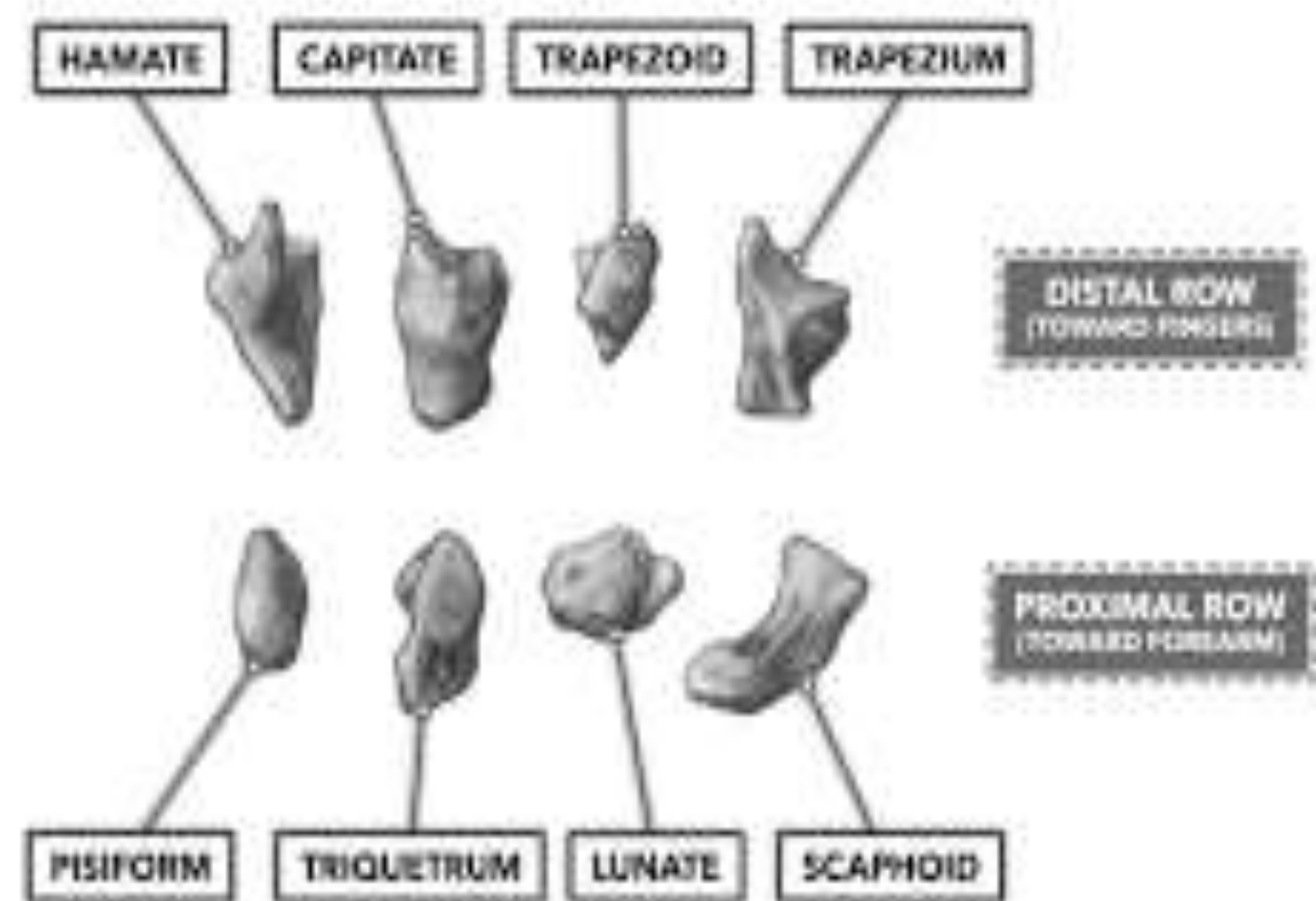
# Introduction

- Carpus (Greek: Corpus/ Karpos = wrist)
- Consists of **8** carpal bones
- They are arranged in two rows:
  - ❑ Proximal
  - ❑ Distal.
- Each row consists of four bones.



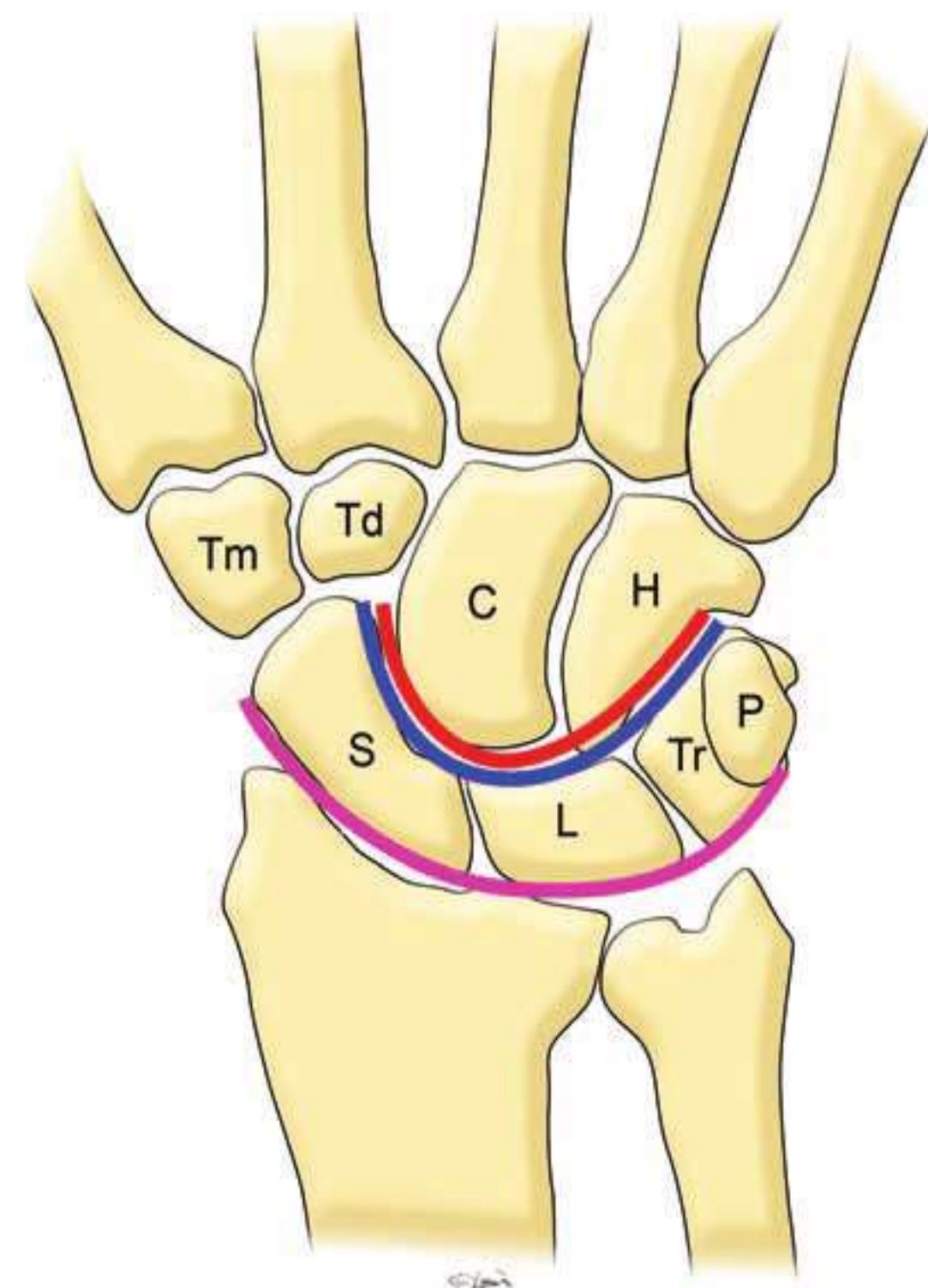
## Proximal row (from lateral to medial side):

- i. The scaphoid (Greek : boat)
- ii. The **lunate** (Latin : moon shaped)
- iii. The **triquetral** (Latin : three cornered)
- iv. The **pisiform** (Greek : pea)



## Distal row (lateral to medial)

- i. The **trapezium** (Greek : four sided geometric figure)
- ii. The **trapezoid** (Greek : baby's shoe)
- iii. The **capitate** (Latin : head)
- iv. The **hamate** (Latin : hook)



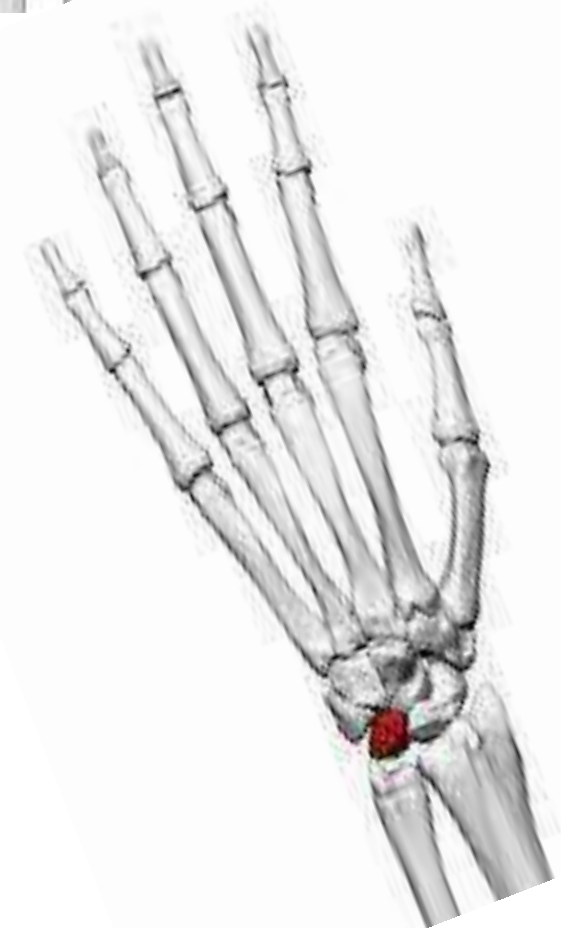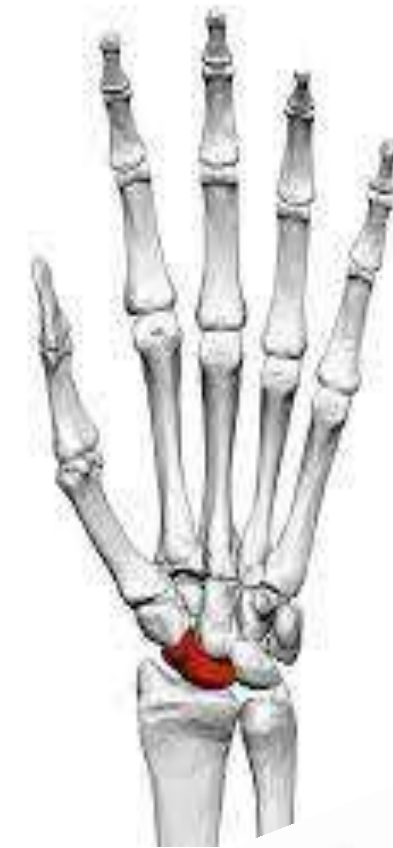## DESCRIPTION - INDIVIDUAL CARPAL BONES

**The scaphoid** is boat-shaped.

- The tubercle is directed laterally, forward and downwards.

**The lunate** is half-moon-shaped or crescentic.

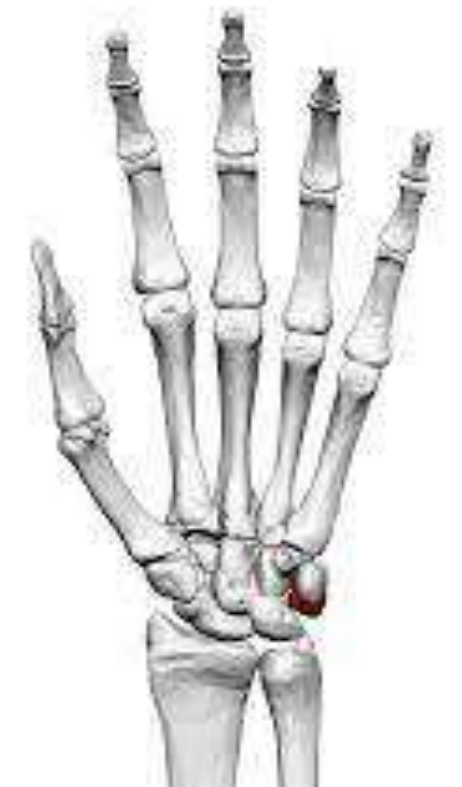- A small semilunar articular surface for the scaphoid is on the lateral side.
- A quadrilateral articular surface for the triquetral is on the medial side.





**The triquetral** is pyramidal in shape and has an isolated oval facet on the distal part of the palmar surface.

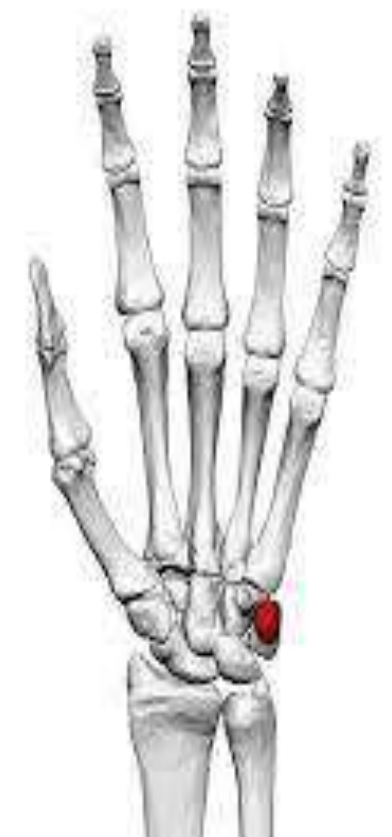- The medial and dorsal surfaces are continuous and nonarticular.



**The pisiform** is pea-shaped and has only one oval facet on the proximal part of its dorsal surface.

- The lateral surface is grooved by the ulnar nerve.

**(Note : sesamoid bone, embedded in the tendon of flexor carpi ulnaris)**

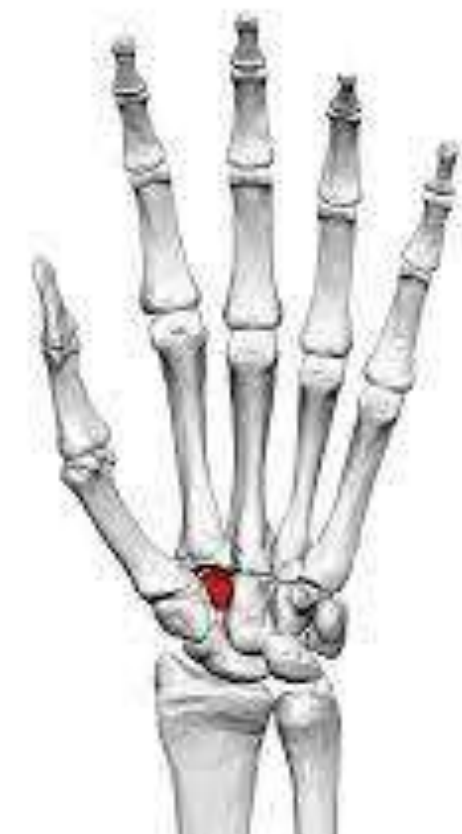
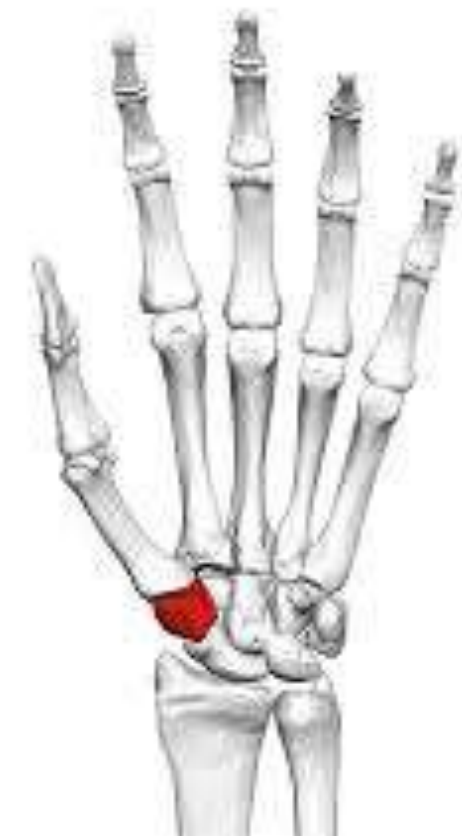
**The trapezium** is quadriangular in shape, and has a crest and a groove anteriorly.

- The distal surface bears a sellar concavo-convex articular surface for the base of the first metacarpal bone

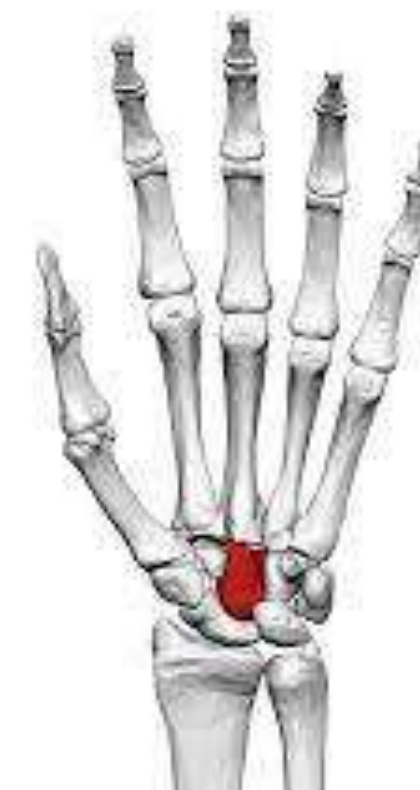**The trapezoid** resembles the shoe of a baby.

- The distal articular surface is bigger than the proximal.
- The palmar nonarticular surface is prolonged laterally



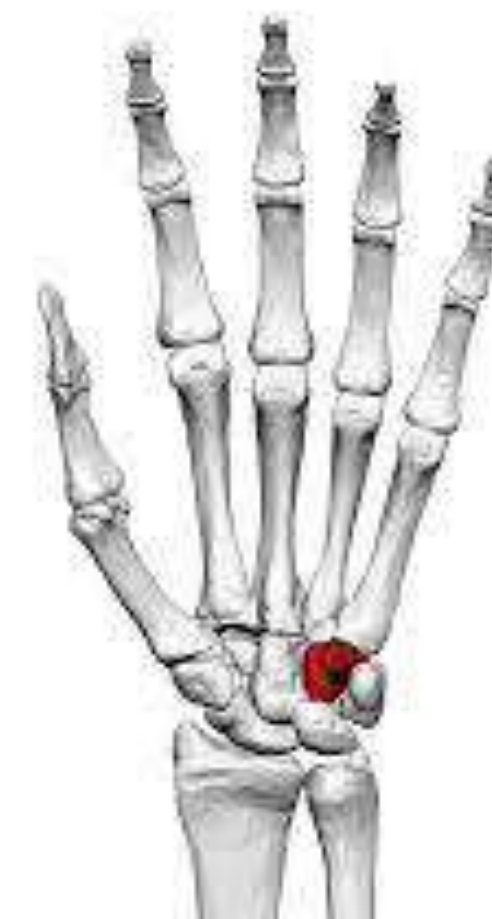**The capitate** is the **largest carpal bone**, with a rounded head.

- The dorsomedial angle is the distal-most projection from the body of the capitate. It bears a small facet for the 4th metacarpal bone.



**The hamate** is wedge-shaped with a hook near its base

- The hook projects from the distal part of the palmar surface, and is directed laterally.



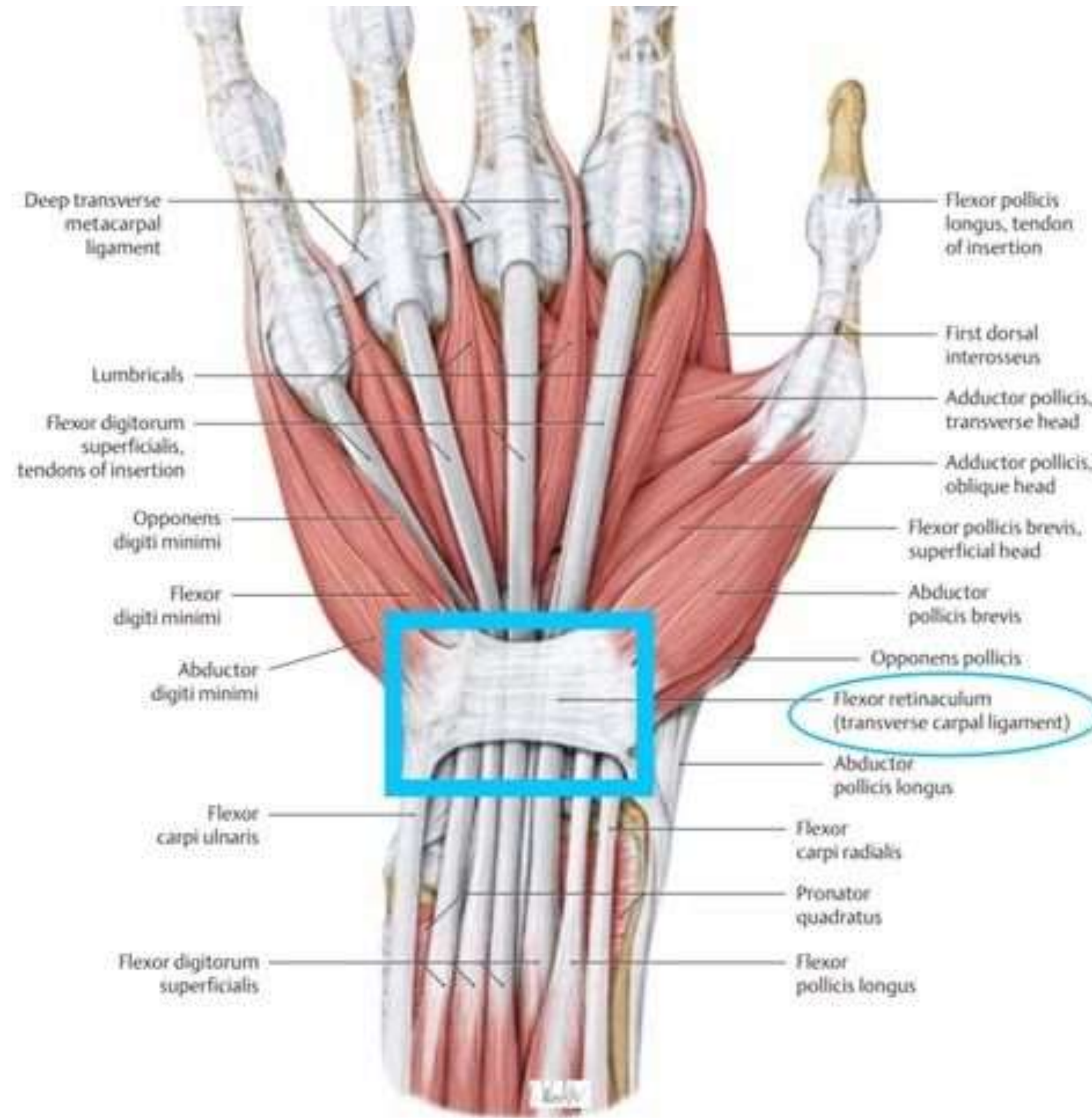
Carpal bone	Identifying features
1. Scaphoid	<ul style="list-style-type: none"> <li>– Boat-shaped</li> <li>– Has constriction (neck)</li> <li>– Has tubercle on distal part of its palmar surface</li> </ul>
2. Lunate	Moon-shaped/crescentic
3. Triquetral	<ul style="list-style-type: none"> <li>– Pyramidal in shape</li> <li>– Oval facet on the distal part of its palmar surface for articulation with pisiform</li> </ul>
4. Pisiform	<ul style="list-style-type: none"> <li>– Pea-shaped/pea-like</li> <li>– Oval facet on the proximal part of its dorsal surface</li> </ul>
5. Trapezium	<ul style="list-style-type: none"> <li>– Quadrilateral in shape</li> <li>– Has groove and crest (tubercle) on its palmar surface</li> </ul>
6. Trapezoid	– Shoe-shaped
7. Capitate	<ul style="list-style-type: none"> <li>– Largest carpal bone</li> <li>– Has rounded head on its proximal surface</li> </ul>
8. Hamate	<ul style="list-style-type: none"> <li>– Wedge-shaped</li> <li>– Hook-like process projects from distal part of its palmar surface</li> </ul>



# Attachments

Four bony pillars at the four corners of the carpus. All attachments are to these four pillars

1. The tubercle of scaphoid
2. Pisiform
3. Trapezium
4. Hamate



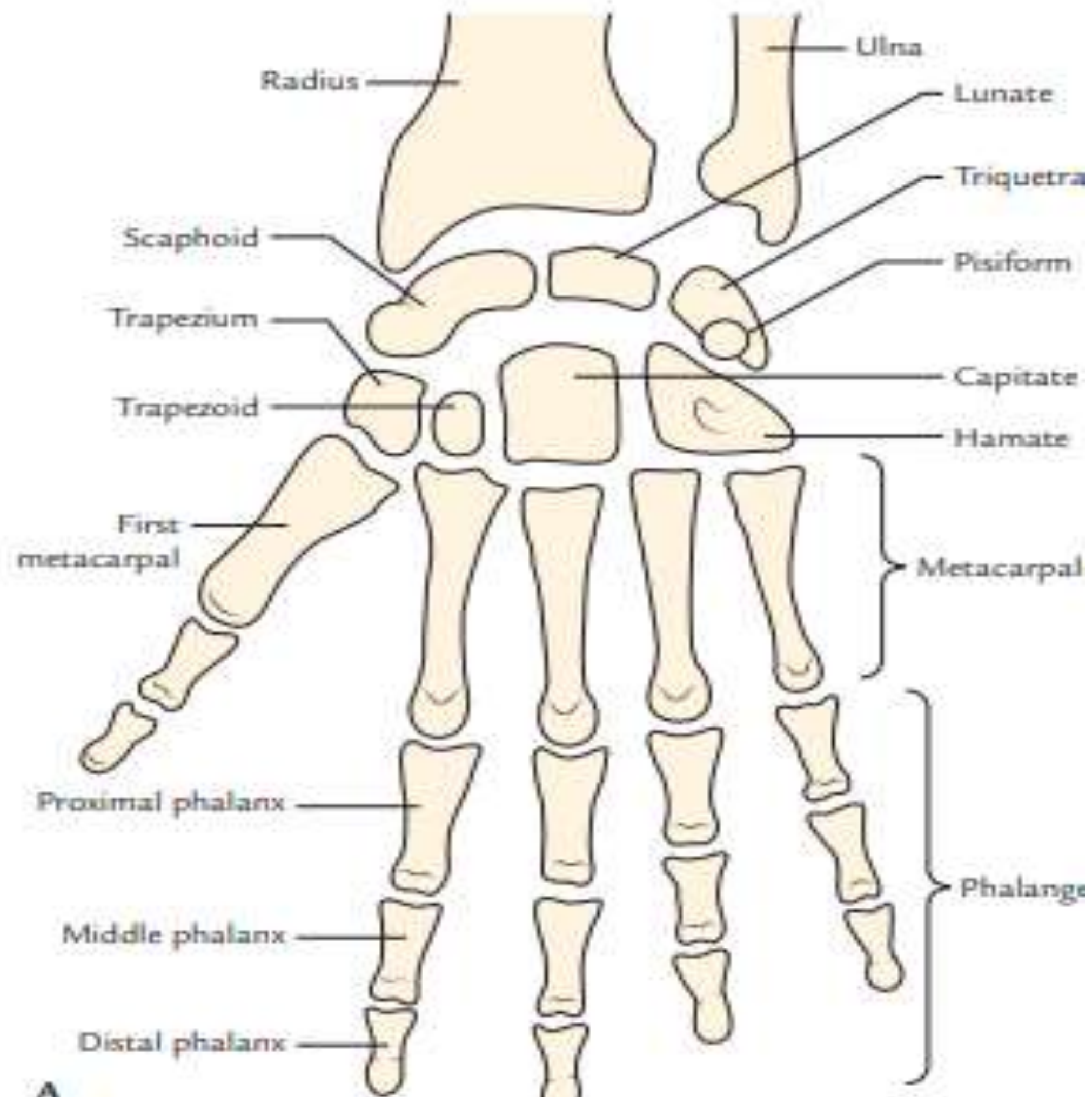


# 1. The tubercle of the scaphoid

- ❖ The flexor retinaculum
- ❖ A few fibres of the abductor pollicis brevis.

## 2. The pisiform:

- ❖ Flexor carpi ulnaris,
- ❖ Flexor retinaculum and its superficial slip
- ❖ Abductor digiti minimi
- ❖ Extensor retinaculum.



### 3 The trapezium:

- ❖ The crest gives **origin** to the abductor **pollicis brevis**, I flexor **pollicis brevis**, and **opponens pollicis**. (muscles of thenar eminence).
- ❖ The edges of the groove - two layers of the flexor retinaculum.
- ❖ The lateral surface - lateral ligament of the wrist joint.
- ❖ The groove lodges the tendon of the flexor carpi radialis.

### 4 The hamate

- ❖ tip of the hook - flexor retinaculum.
- ❖ iThe medial side of the hook - flexor digiti minimi and the opponens digiti minimi.



# Articulations

1. **The scaphoid:** Radius, lunate, trapezium, trapezoid, capitate
2. **The lunate:** Radius, scaphoid, capitate, hamate and triquetral.
3. **The triquetral:** Pisiform, lunate, hamate and articular disc of the inferior radioulnar joint.
4. **The pisiform** articulates only with the triquetral.

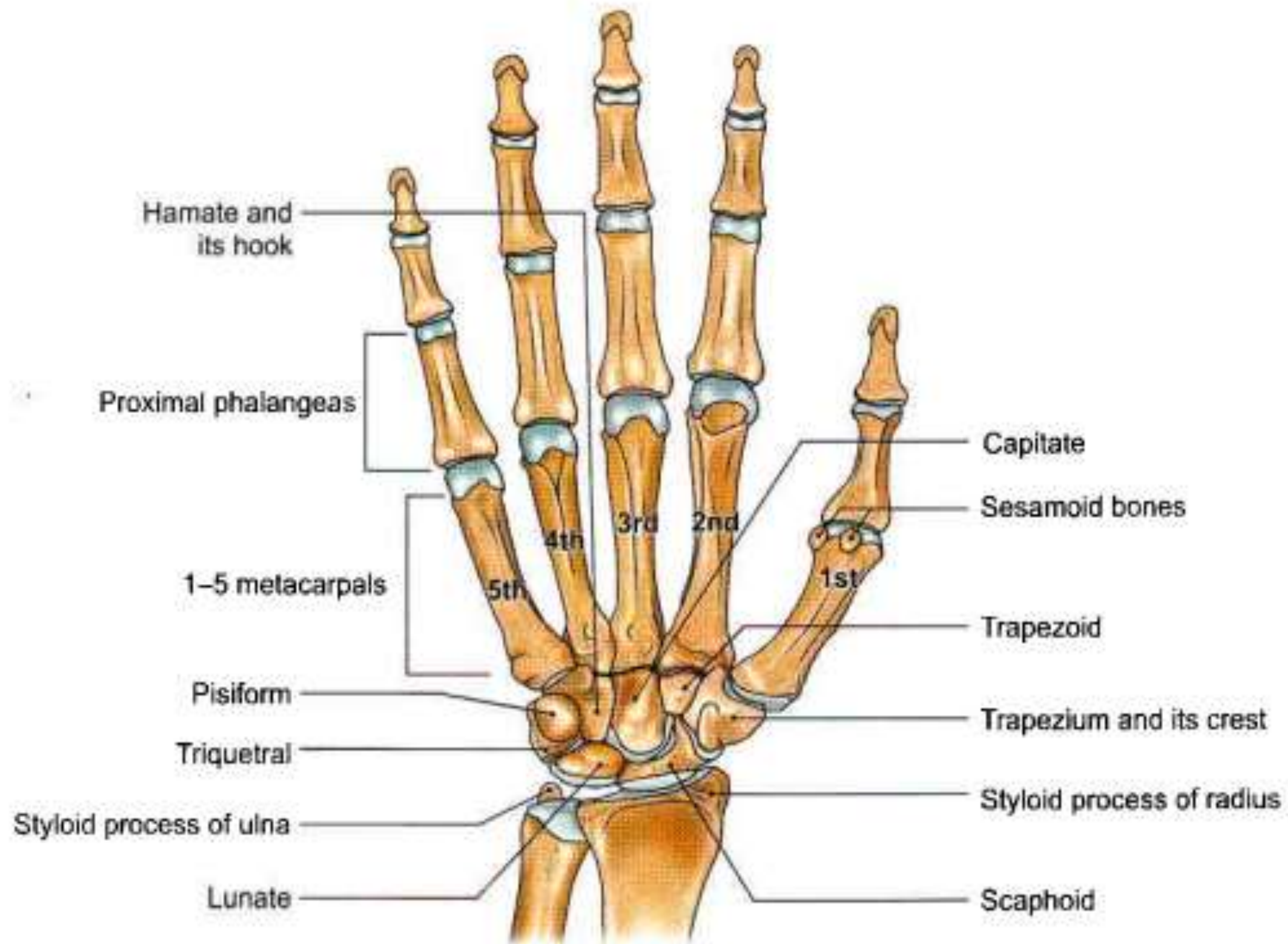


5. **The trapezium:** Scaphoid, 1st and 2nd metacarpals and trapezoid.

6. **The trapezoid:** Scaphoid, trapezium, 2nd metacarpal and capitate.

7. **The capitate:** Scaphoid, lunate, hamate, 2nd, 3rd and 4th metacarpals and trapezoid.

8. **The hamate:** Lunate, triquetral, capitate, and 4th and 5th metacarpals





# OSSIFICATION

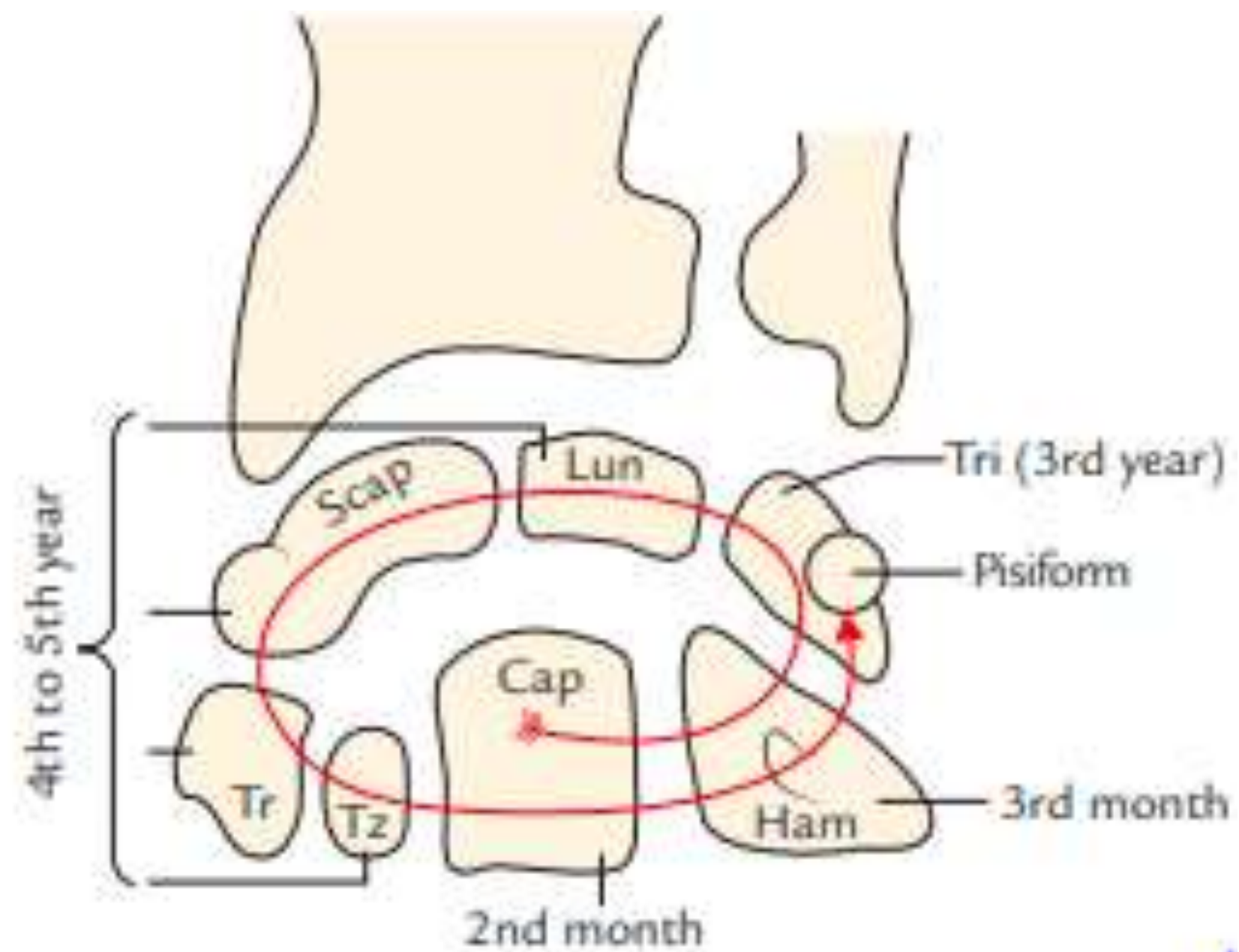
- The carpal bones are cartilaginous at birth.
- Each carpal bone ossifies by one centre and all these centres appear after birth

(Note: The capitate is the first bone to ossify and pisiform is the last bone to ossify)



The centres appear as follows:

- |              |  |
|--------------|--|
| • Capitate   | Second month                                       |
| • Hamate     | End of third month                                 |
| • Triquetral | Third year   |
| • Lunate     |  |
| • Scaphoid   |  |
| • Trapezium  | Fourth year, in females and fifth year in males    |
| • Trapezoid  |  |
| • Pisiform   | Twelfth year in males, 9th to 10th year in females |





# CLINICAL CORRELATON



# Fracture of the scaphoid

Commonest fracture in wrist region.

The bone fractures through the wrist at right angles to its long axis.

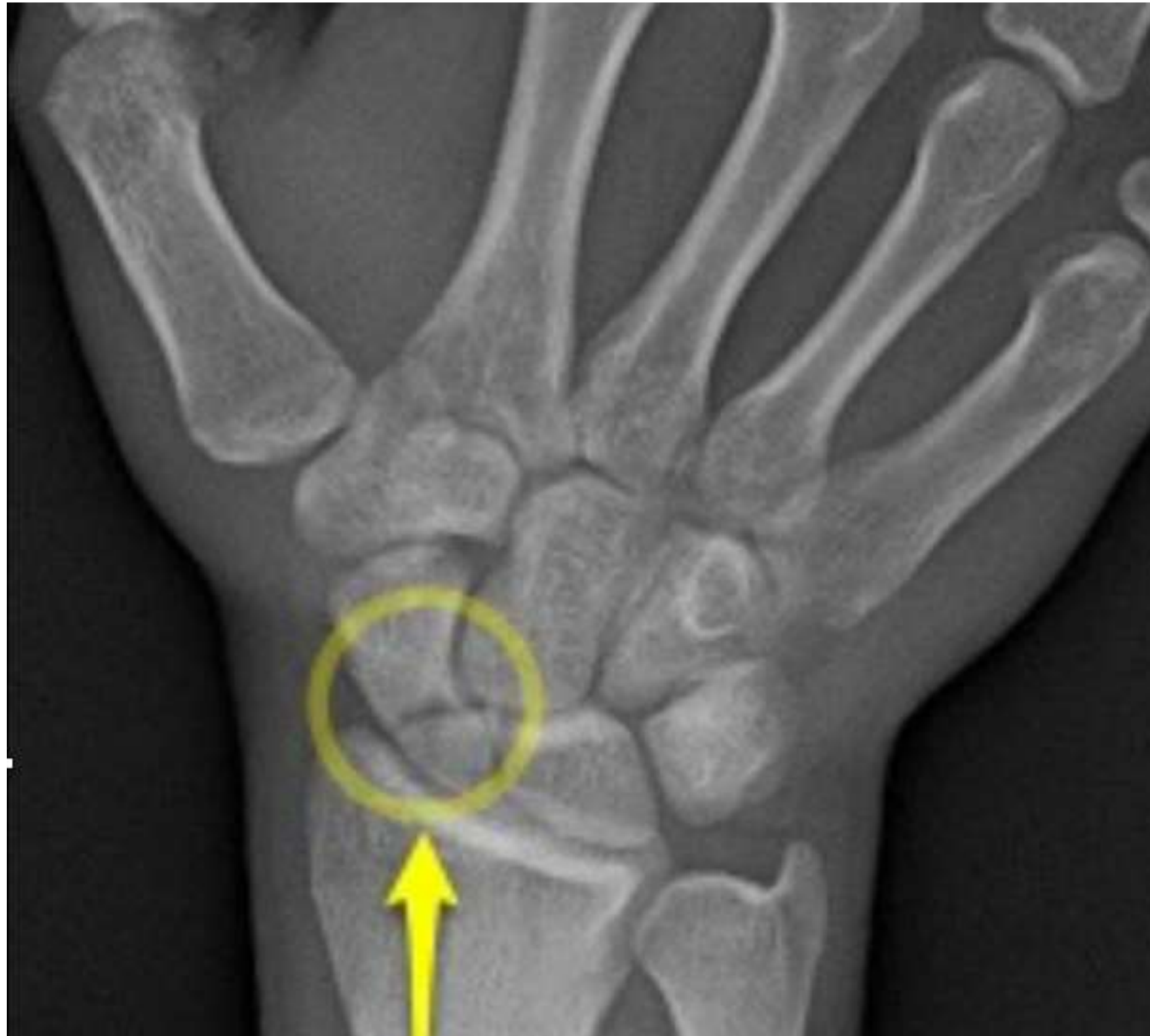Mechanism : fall on the out stretched hand, or on the tips of the fingers.

Signs and Symptoms :

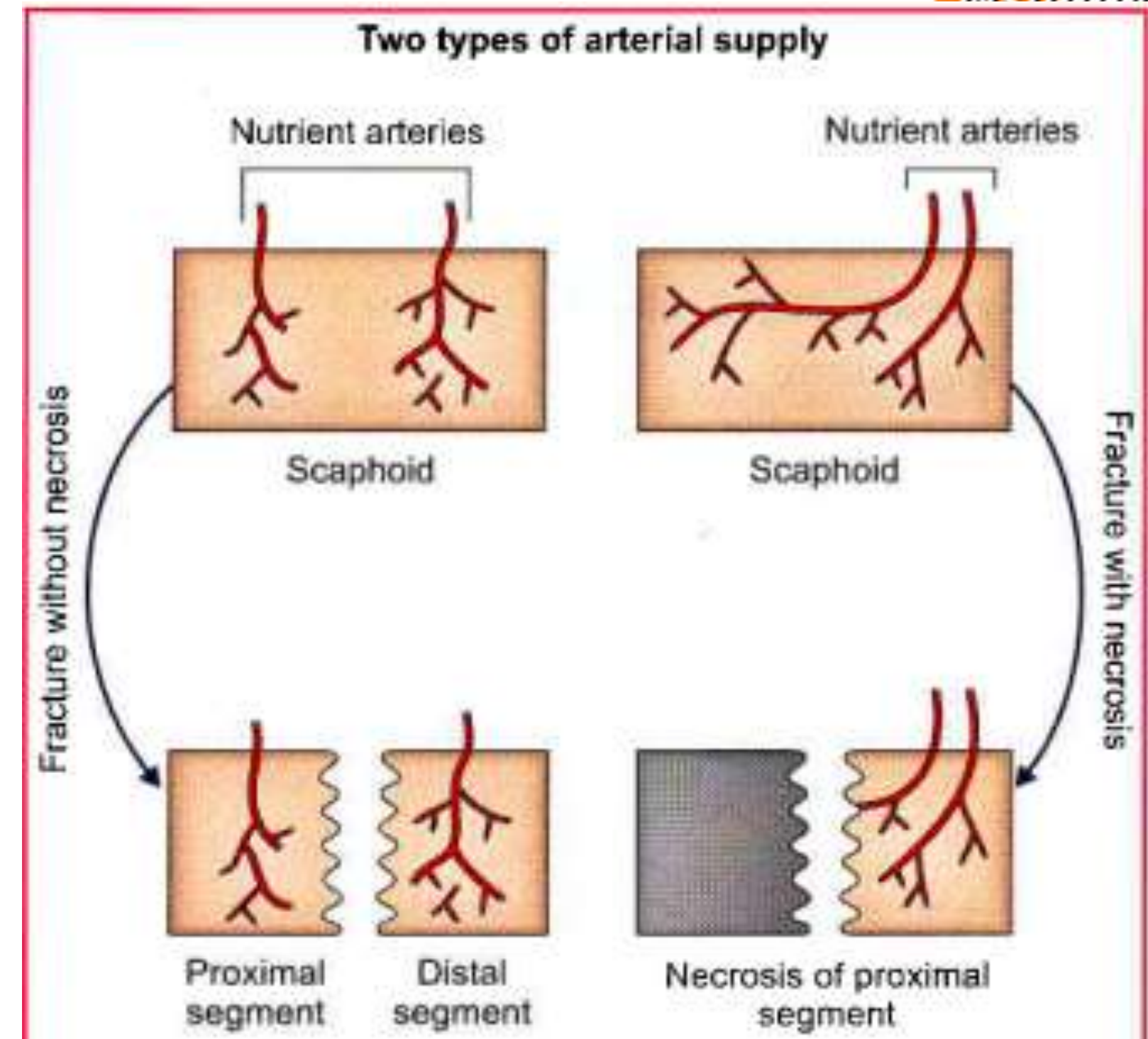
- Tenderness and swelling in the anatomical snuff box
- Pain on longitudinal percussion of the thumb and index finger

The residual disability is more marked in the midcarpal joint than in the wrist joint.

The importance of the fracture lies in its liability to nonunion and avascular necrosis of the body of the bone.



- The scaphoid has two nutrient arteries
  - (i) One entering the palmar surface of the tubercle
  - (ii) Other the dorsal surface of the body.
- Both vessels enter through the tubercle or through the distal half of the bone.
- In such cases, fracture may decrease the proximal half of the bone of its blood supply leading to **avascular necrosis**

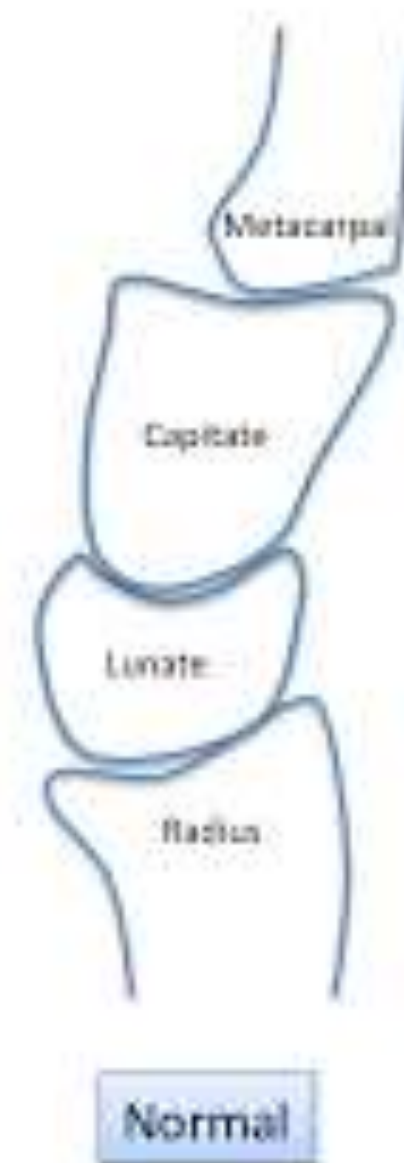


# Dislocation of the lunate

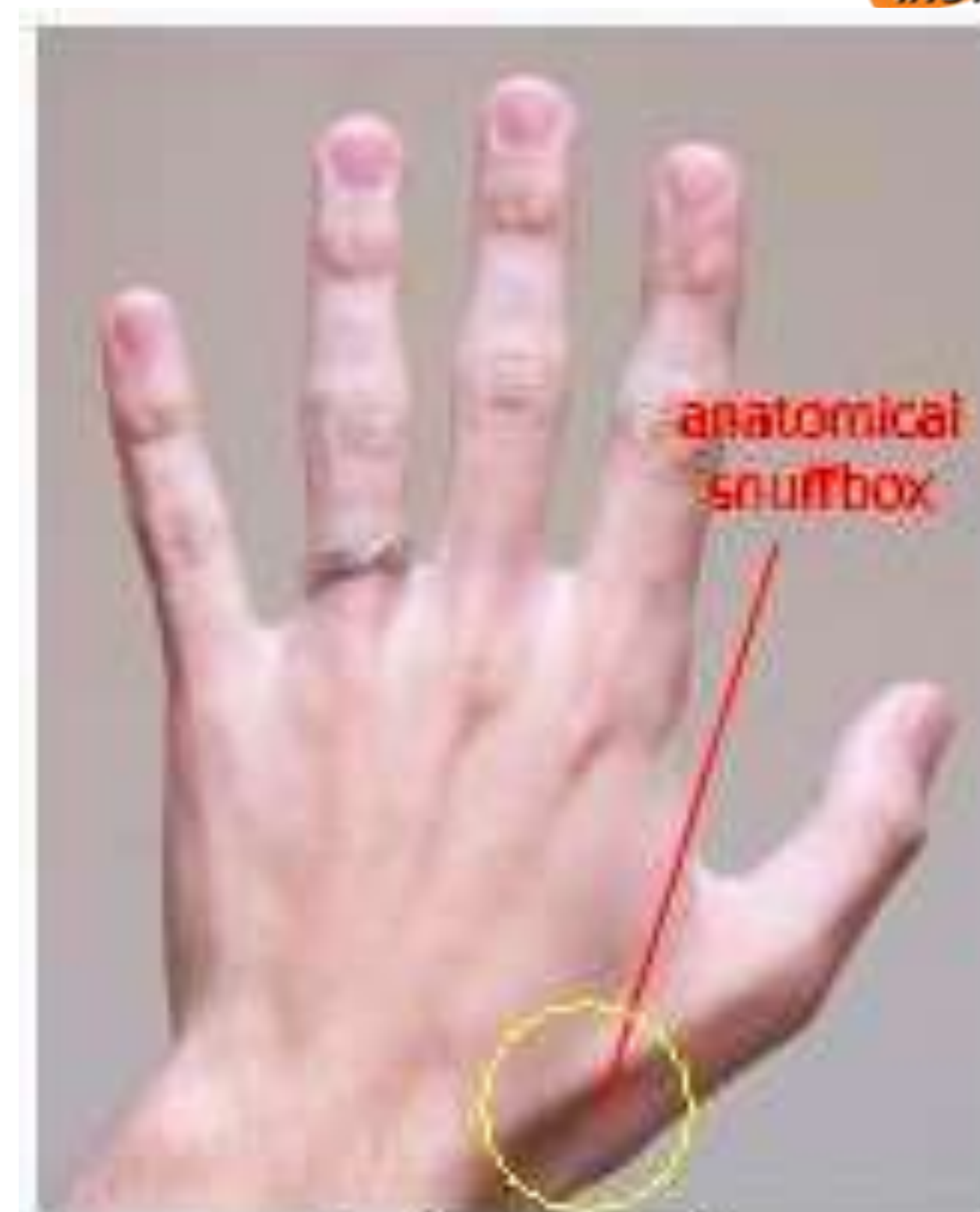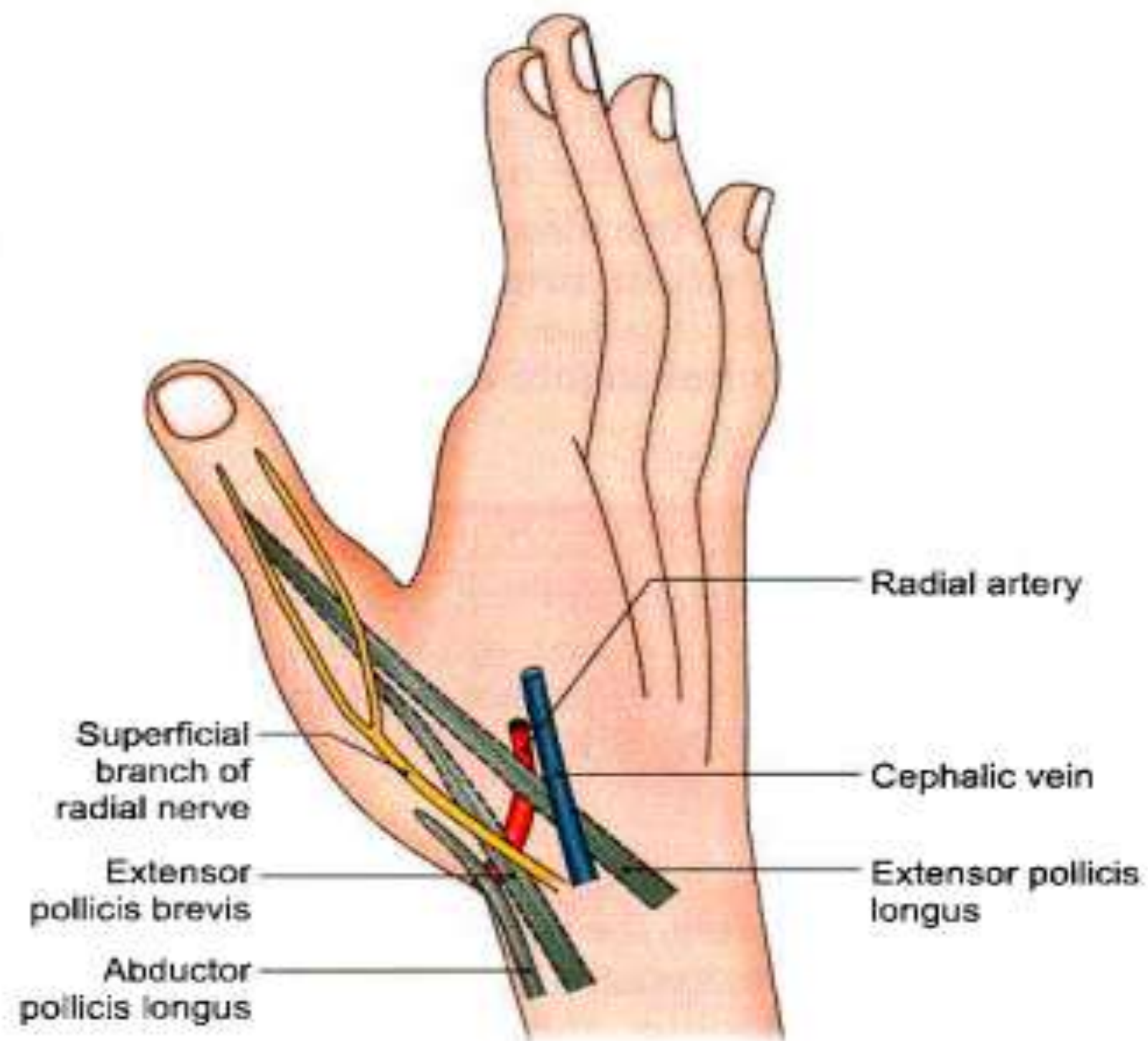
Mechanism : Fall on the acutely dorsiflexed hand with the elbow joint flexed.

This displaces the lunate anteriorly,

May also leading to carpal tunnel syndrome like features



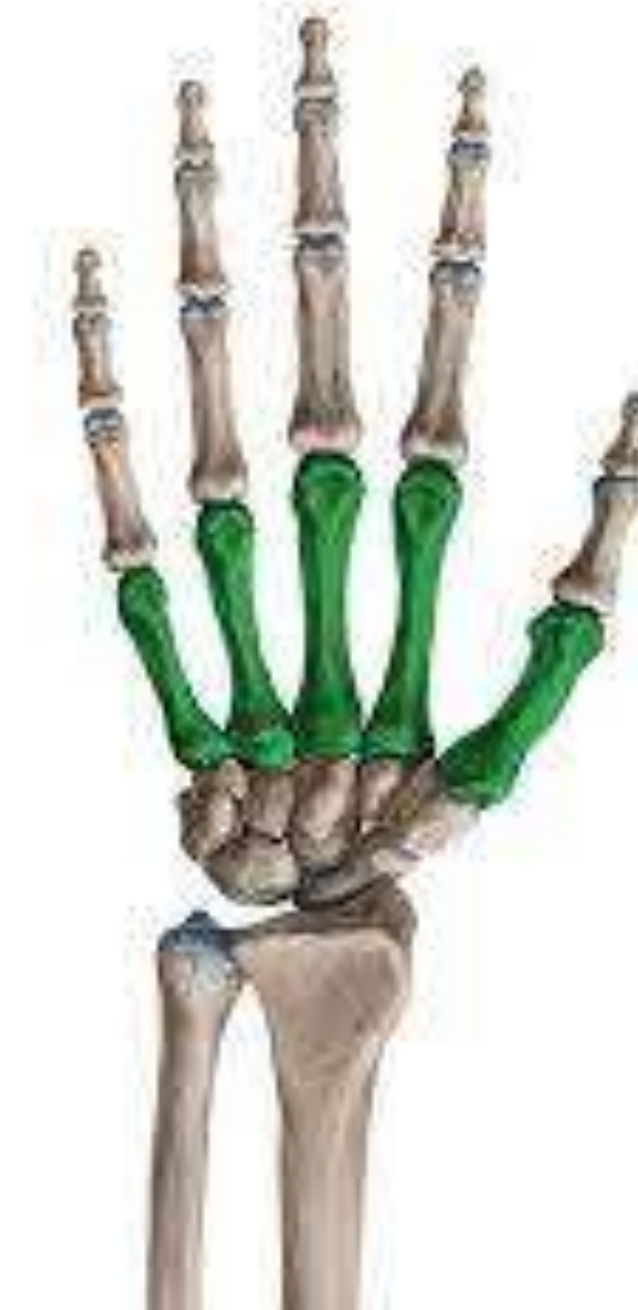# ANATOMICAL SNUFF BOX



anatomical snuffbox

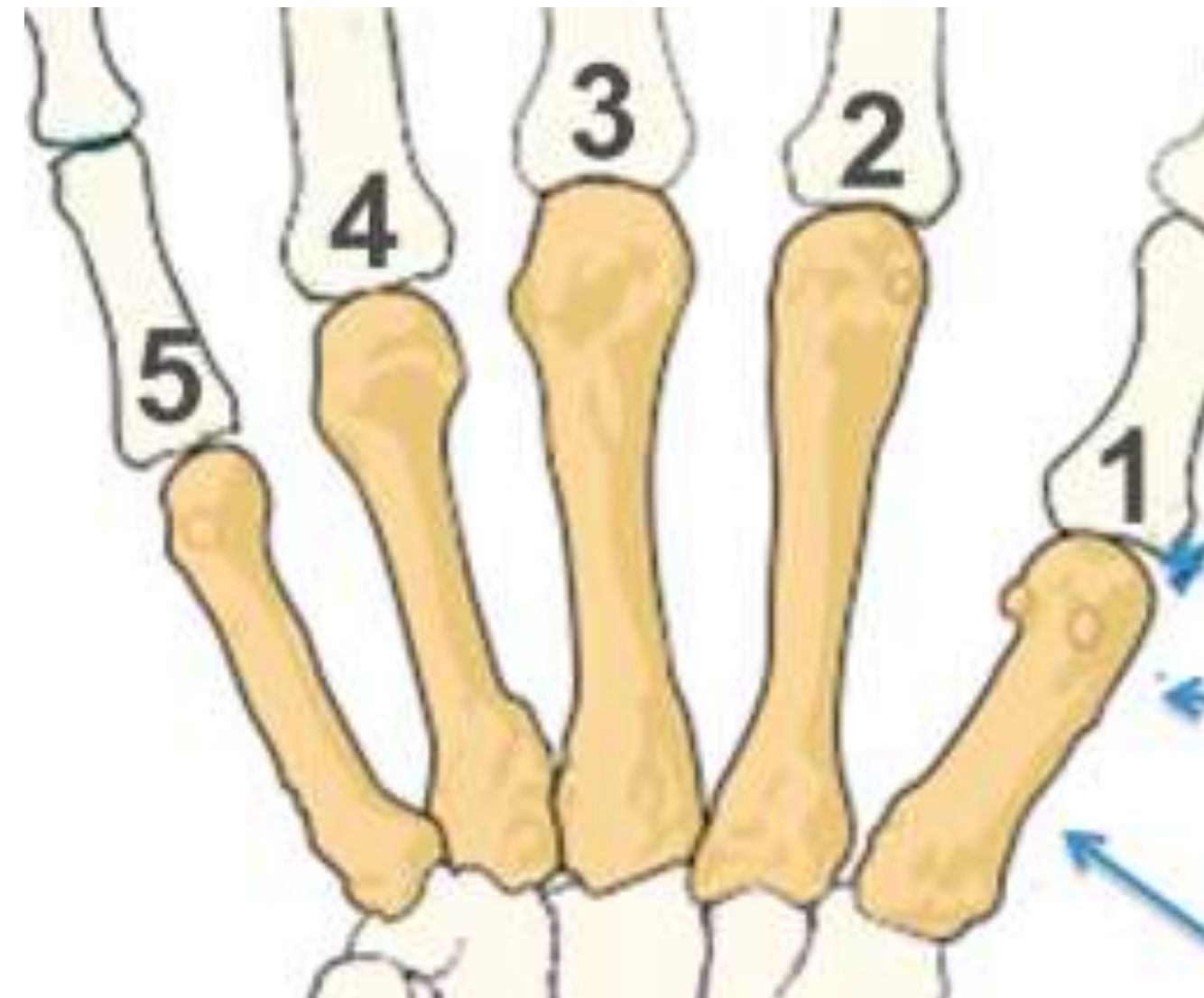# METACARPAL BONES

- These are short / miniature long bones
- 5 in each hand
- They are name 1 to 5 (lateral to medial)



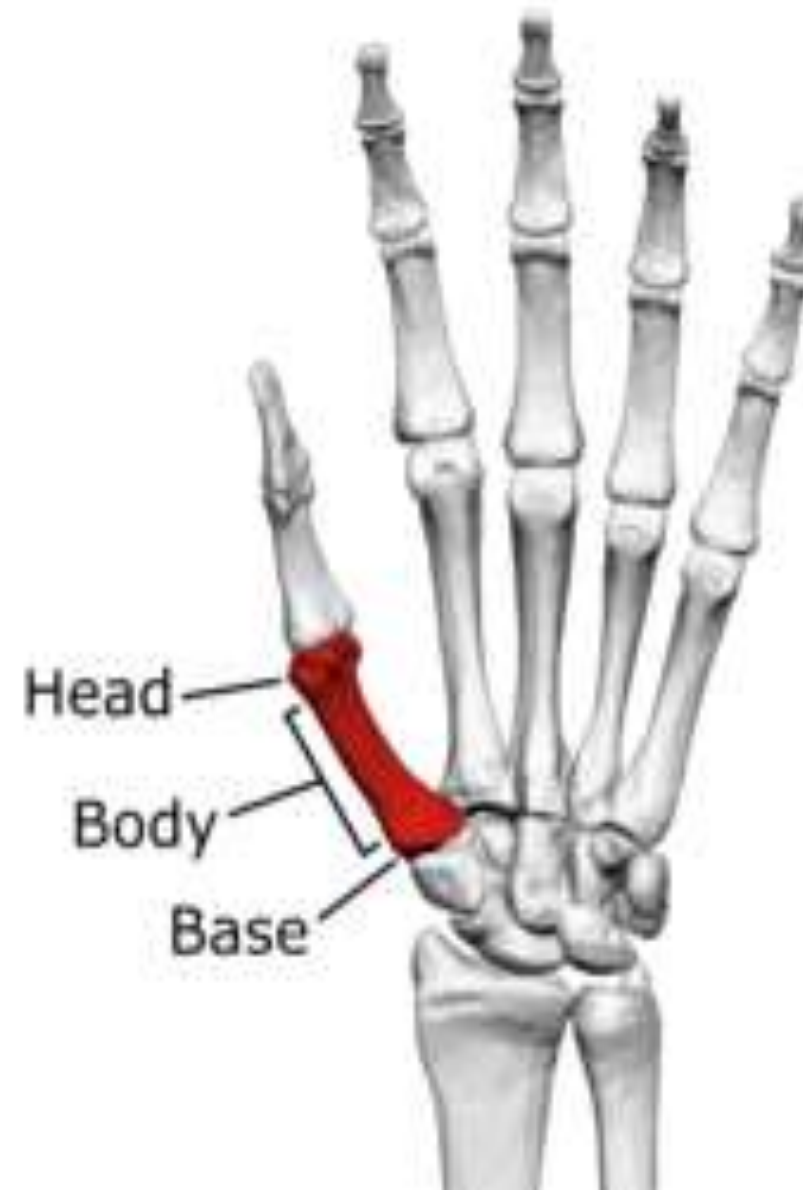# METACARPAL BONES

- i.e., 1<sup>st</sup> metacarpal → thumb  
2<sup>nd</sup> metacarpal → index finger  
3<sup>rd</sup> metacarpal → middle finger  
4<sup>th</sup> metacarpal → ring finger  
5<sup>th</sup> metacarpal → little finger



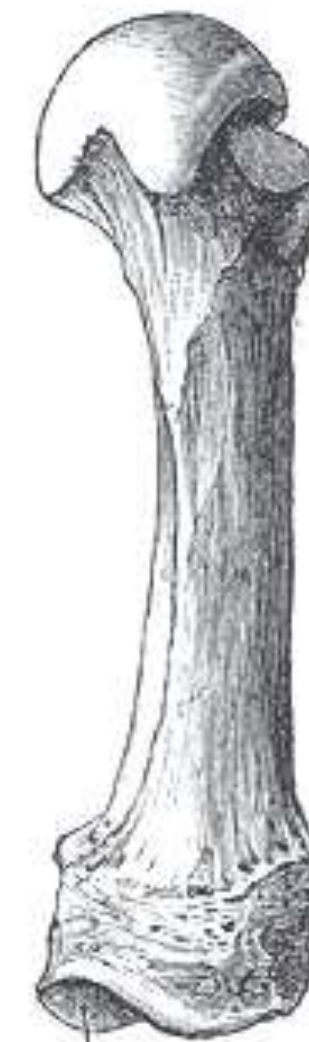# PARTS - METACARPAL BONES

- Each bone has a **head** placed distally, a **shaft** and a **base** at the proximal end.



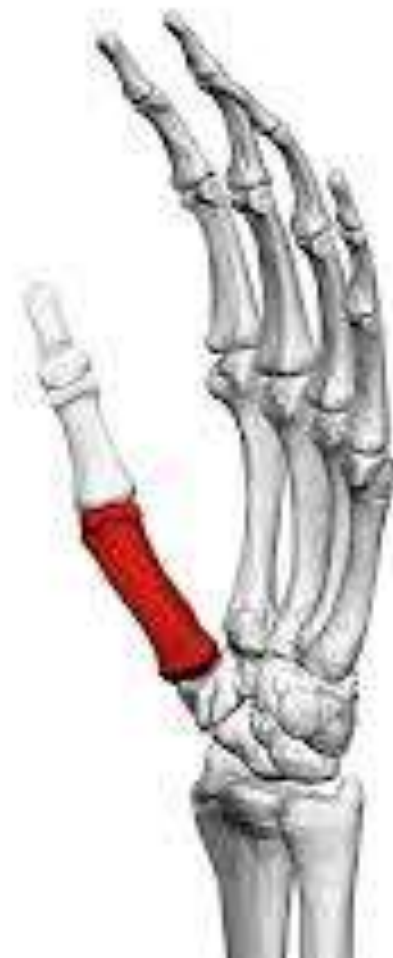# HEAD - METACARPAL

- Rounded
- Articular surface - extends more anteroposteriorly than laterally.
- Extends more on the palmar surface than on the dorsal surface.
- The heads of the metacarpal bones form the knuckles



# SHAFT - METACARPAL BONES

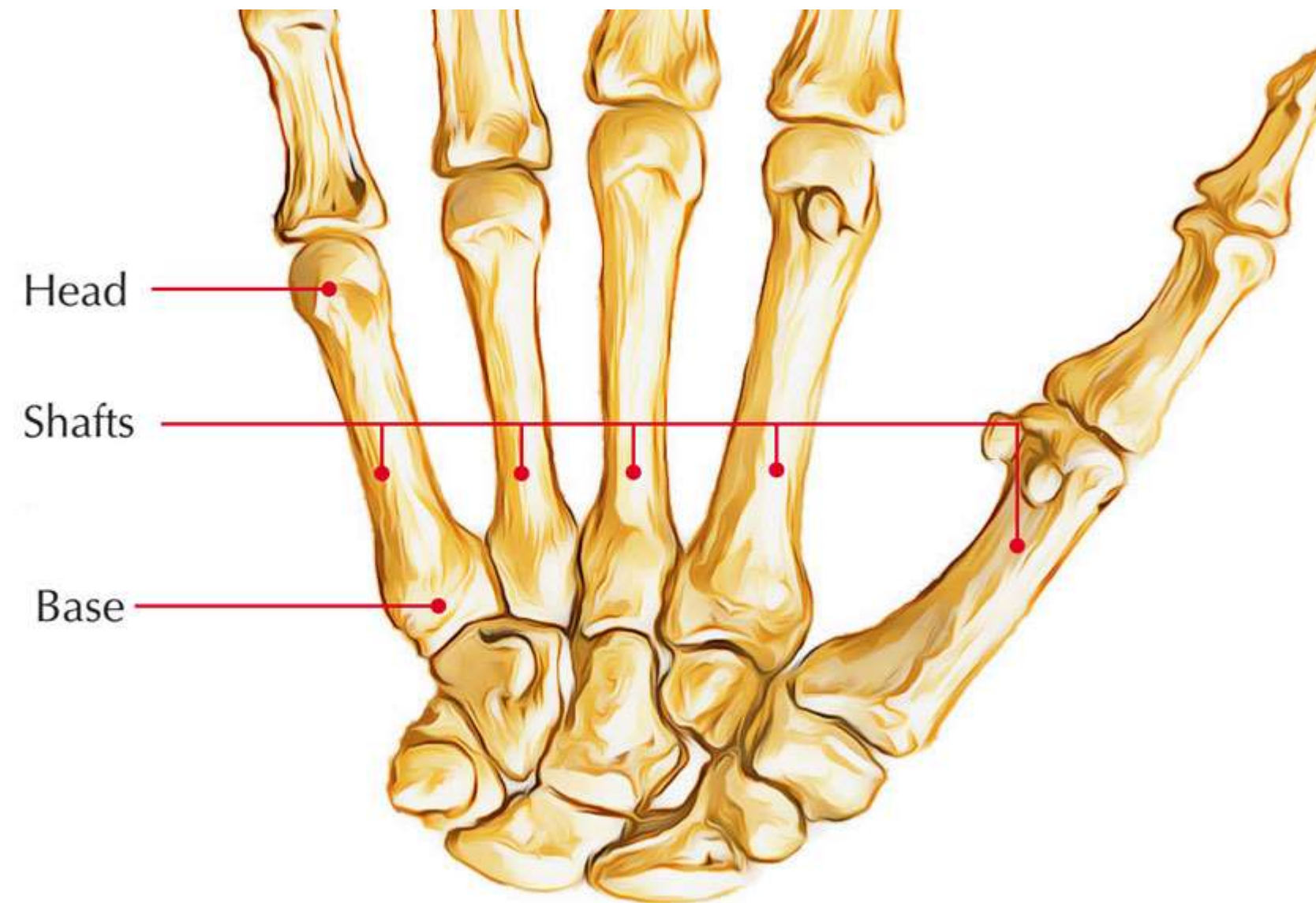
- The shaft extends between head and base
- The shaft is concave on the palmar surface.
- Its dorsal surface bears a flat triangular area in its distal part.



# BASE - METACARPAL

- The base is proximal end
- Irregularly expanded.

Metacarpal bones





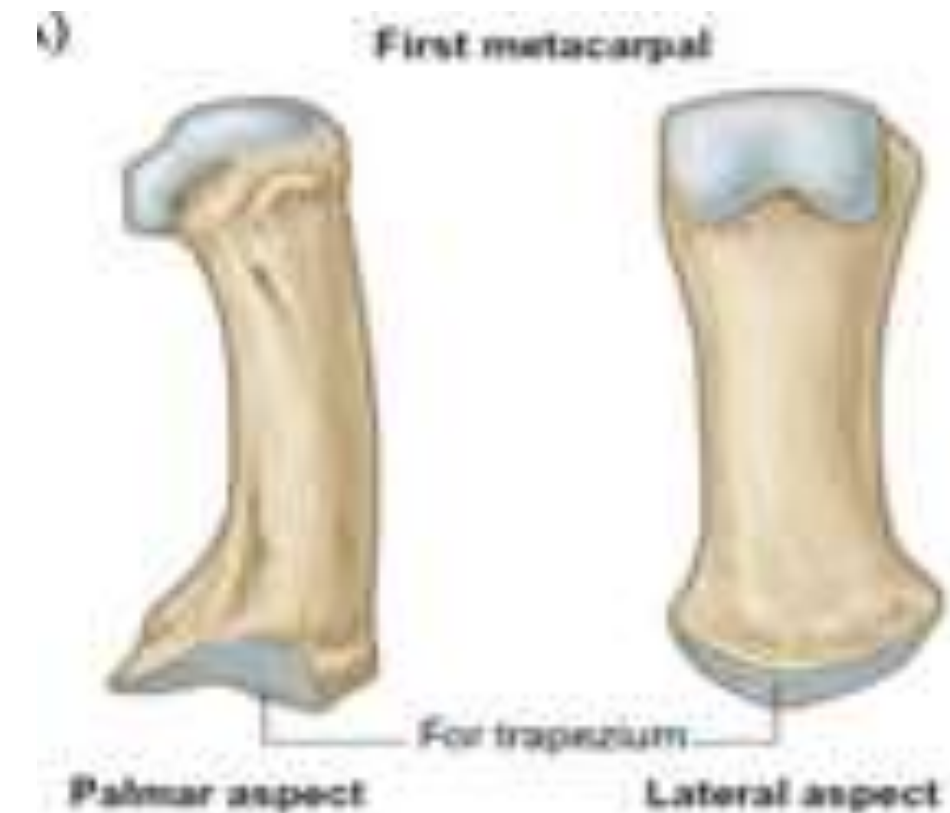# **CHARACTERISTICS OF INDIVIDUAL METACARPAL BONES**

# 1<sup>ST</sup> METACARPAL BONE

Shortest and stoutest of all metacarpal bones.

## Articulations:-

- The base articulates with convexo-concave articular surface for the trapezium.
- Head articulates with base of proximal phalanx of thumb
- **Shaft** → dorsally uniformly convex.
- **Head** →
  - ❖ less convex ;
  - ❖ broader from side to side.
  - ❖ The ulnar and radial corners of palmar surface show impressions for sesamoid bones.



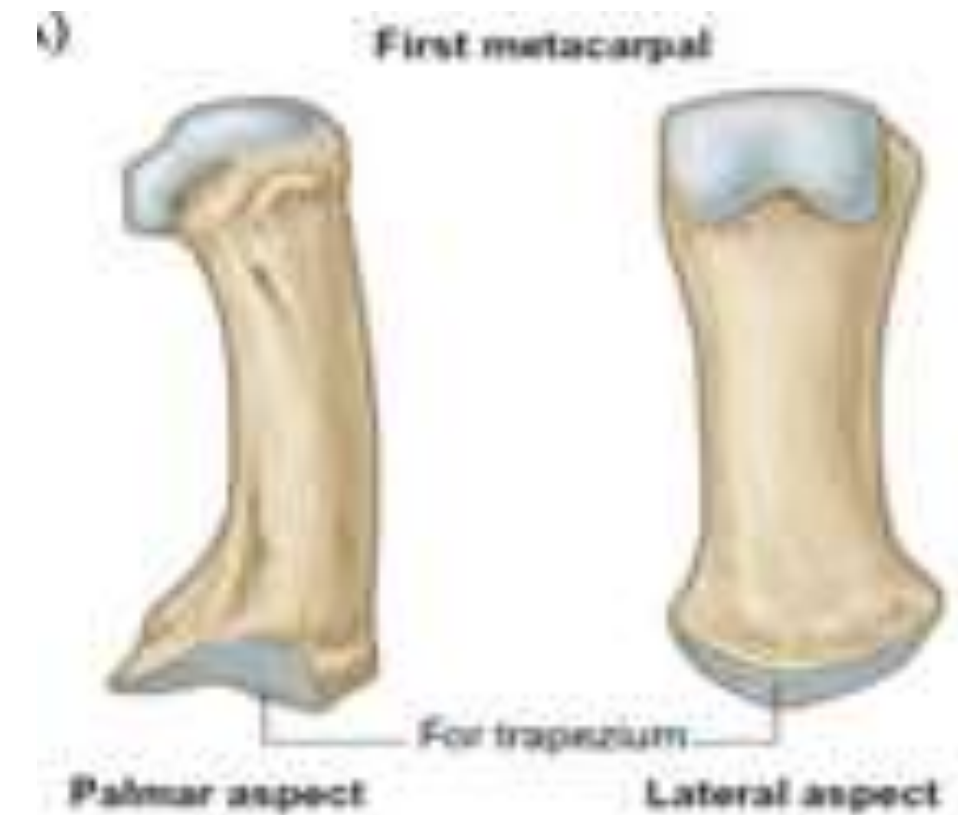
## Orientation:-

- Rotated medially through 90° relative to the other metacarpals.
- the movements of the thumb take place at right angles to those of other digits.



# 1<sup>ST</sup> METACARPAL BONE- Side Determination

The anterolateral surface is larger than the anteromedial





# 1<sup>ST</sup> METACARPAL BONE - ATTACHMENTS



**Origin :** 1<sup>st</sup> first palmar interosseous muscle from the ulnar side of the base

**Insertion :**

- The opponens pollicis → radial border and the anterolateral surface of the shaft
- 
- The abductor pollicis longus → lateral side of the base



## 2<sup>nd</sup> METACARPAL BONE



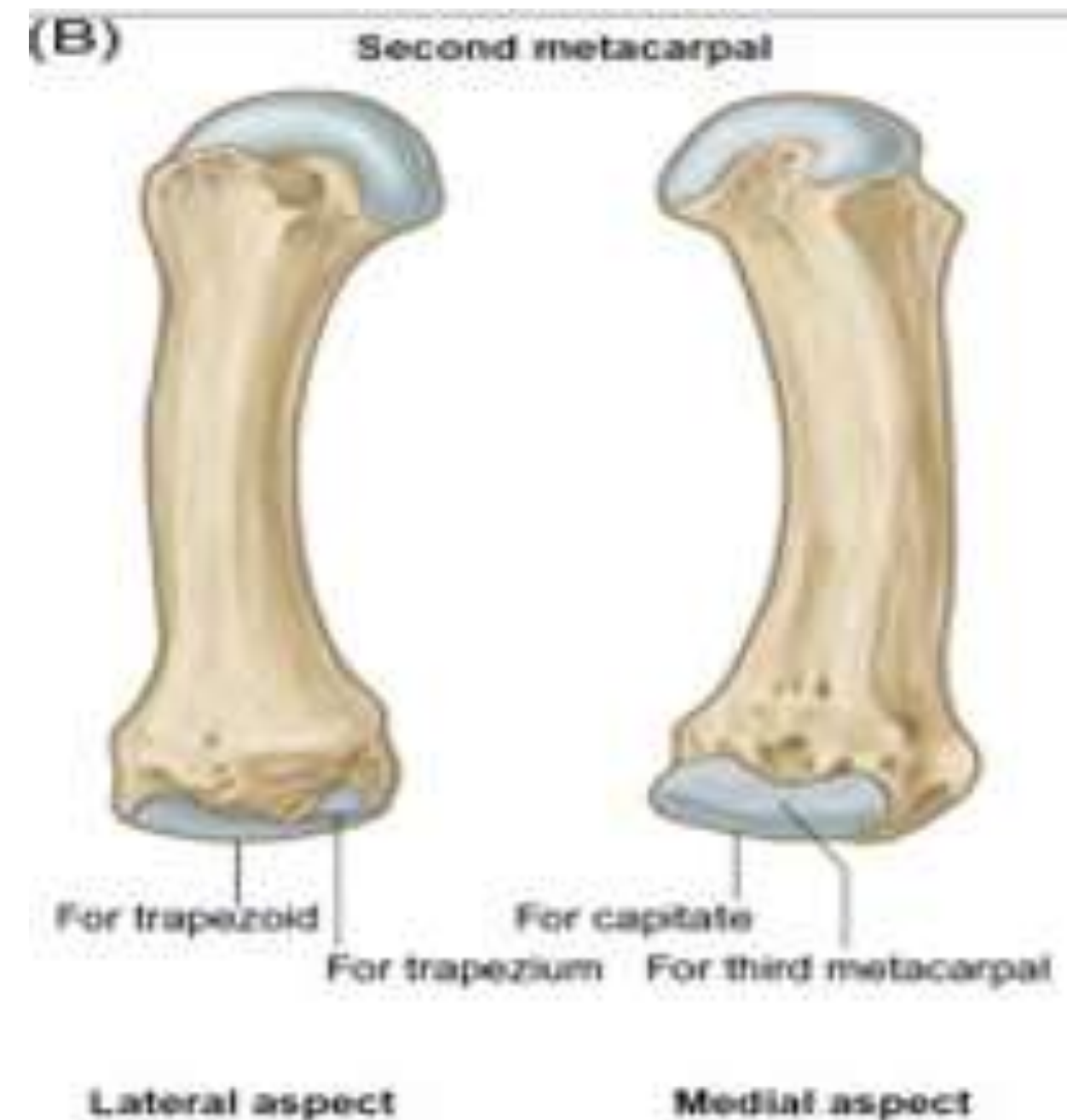
- The base is grooved from before backwards.
- The medial edge of the groove is larger

### Articulation

- **Base :** With the trapezium, the trapezoid, the capitate and the 3rd metacarpal
- **Head :** Articulates with the base of proximal phalanx of index finger (2<sup>nd</sup> digit)

# 2<sup>nd</sup> METACARPAL BONE –Side Determination

- The medial edge of the groove on the base than the lateral edge.
- The medial side of the base bears an articular strip which is constricted in the middle.





## 2<sup>nd</sup> METACARPAL BONE – Muscle Attachment

### ORIGIN:

The oblique head of the adductor pollicis arises from the palmar surface of the base

### INSERTION

- flexor carpi radialis is inserted on a tubercle on the palmar surface of the base.
- The extensor carpi radialis longus is inserted on the dorsal surface of the bas.



## 3<sup>rd</sup> METACARPAL BONE –



The base has a styloid process projecting up from the dorsolateral corner

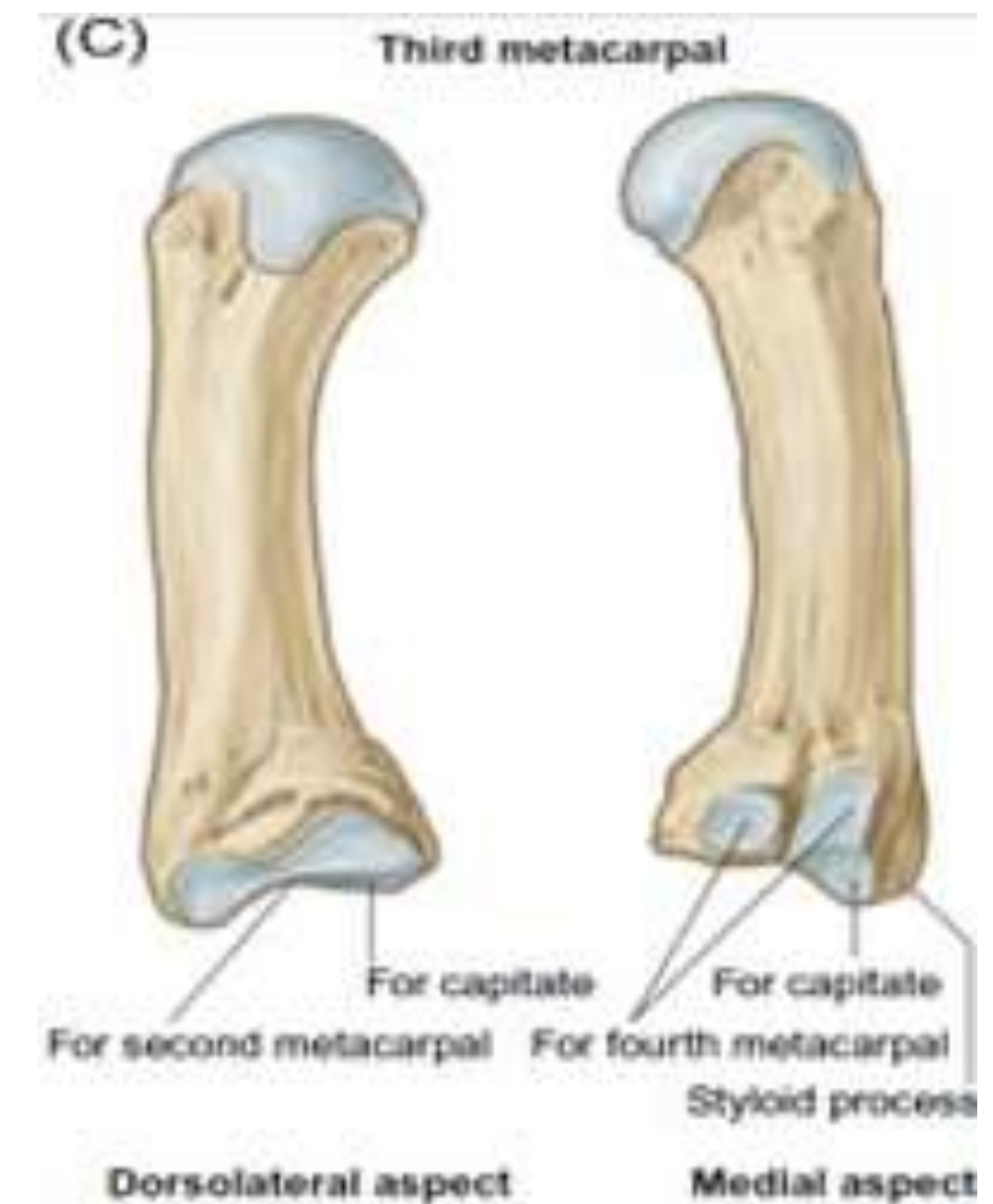### Articulation

**Base :** With the capitate and the 2nd and 4th metacarpals.

**Head :** Articulates with the base of proximal phalanx of middle finger (3<sup>rd</sup> finger)

# 3<sup>rd</sup> METACARPAL BONE – Side Determination

- a. The styloid process is dorsolateral.
- b. The lateral side of the base bears an articular strip which is constricted in the middle.
- c. The medial side of the base has two small oval facets for the 4th metacarpal





# 3<sup>rd</sup> METACARPAL BONE – Muscle Attachment



## ORIGIN :

- The oblique head of the adductor pollicis → palmar surface of the base.
- The transverse head of the adductor pollicis → distal two-thirds of the palmar surface of the shaft

## INSERTION

- slip from the flexor carpi radialis → palmar surface of the base.
- extensor carpi radialis brevis → dorsal surface of the base



# 4<sup>th</sup> METACARPAL BONE



The base has two small oval facets on its lateral side for the third metacarpal, and on its medial side it has a single elongated facet for the 5th metacarpal

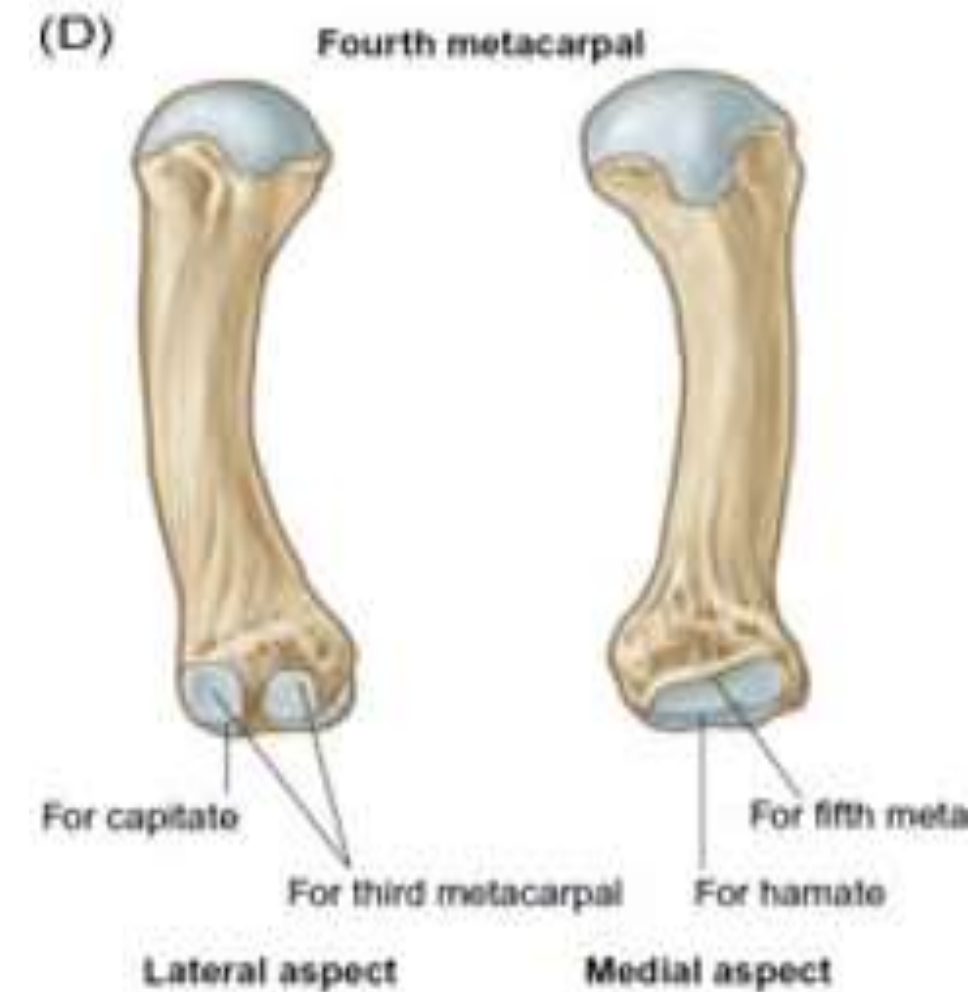
## Articulations

**Base :** With the capitate, hamate 3<sup>rd</sup> and 5th metacarpal

**Head :** Articulates with the base of proximal phalanx of ring finger (4<sup>th</sup> digit)

# 4<sup>th</sup> METACARPAL BONE – Side Determination

- a. The lateral side of the base has two small oval facets for the 3rd metacarpal.
- b. The medial side of the base has an elongated articular strip for the 5th metacarpal





# 4<sup>th</sup> METACARPAL BONE- Muscle Attachment



Only the interossei arise from it



# 5<sup>th</sup> METACARPAL BONE



The base has an elongated articular strip on its lateral side for the 4th metacarpal. The medial side of the base is nonarticular and bears a tubercle

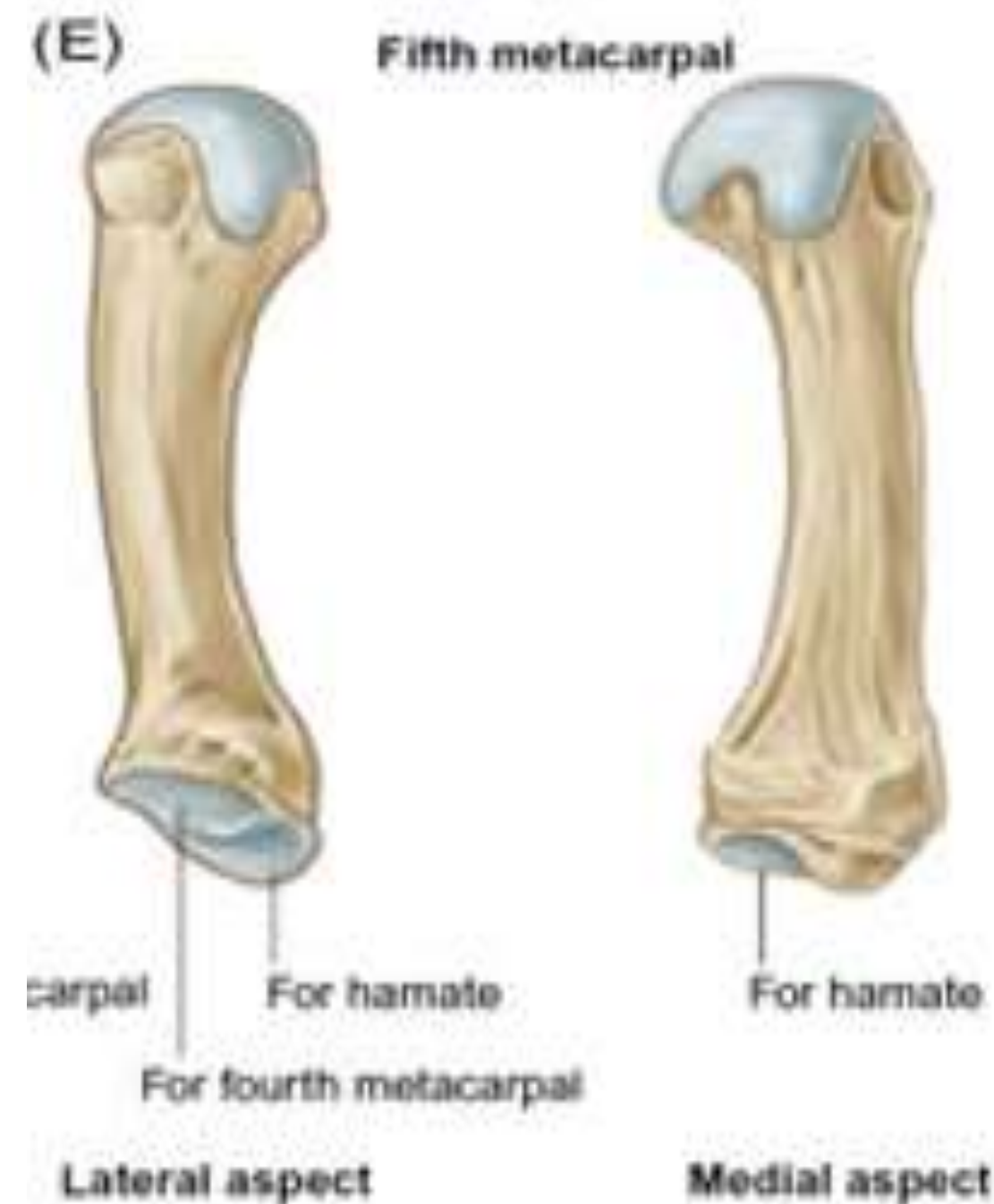
## Articulation

**Base :** With the hamate and 4<sup>th</sup> metacarpal

**Head :** Articulates with the base of proximal phalanx of little finger (5<sup>th</sup> digit)

# 5<sup>th</sup> METACARPAL BONE- Side Determination

- ❖ Lateral side of the base has an elongated articular strip for the 4th metacarpal.
- ❖ Medial side of the base is non articular and has a tubercle.



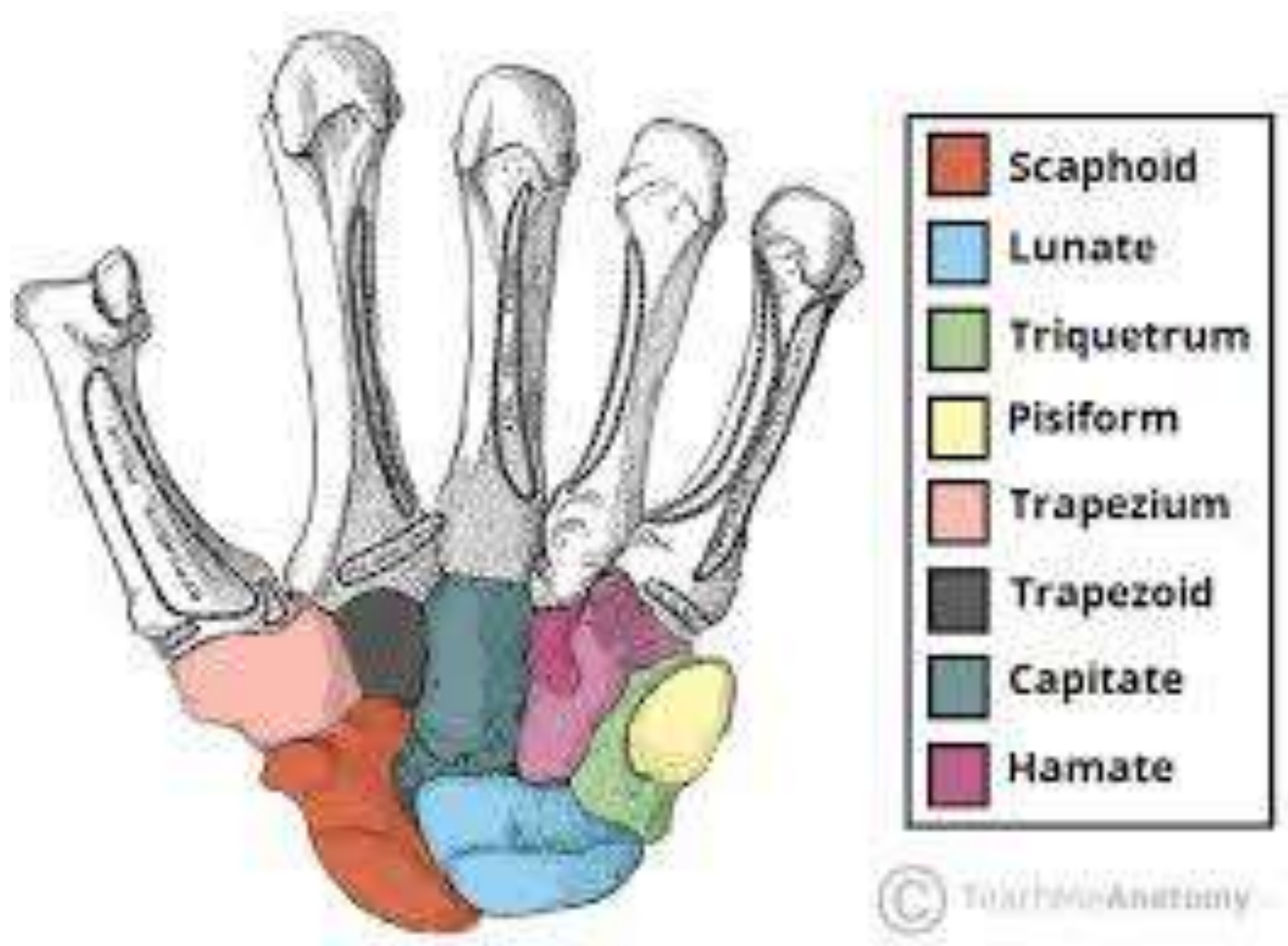


# 5<sup>th</sup> METACARPAL BONE- Muscle Attachment



## INSERTION :

- ❖ Extensor carpi ulnaris → tubercle at the base
- ❖ Opponens digiti minimi → medial surface of the shaft





# OSSIFICATION



Center	Time of appearance	Fusion
Primary centre for shaft	9th week of IUL	
Secondary centre for head of second, third, fourth, and fifth metacarpal	2 years	16 years
Secondary centre for base for first metacarpal	2 years	18 years



# Clinical correlation

# Bennets's Fracture

Fracture of the base of the first metacarpal.

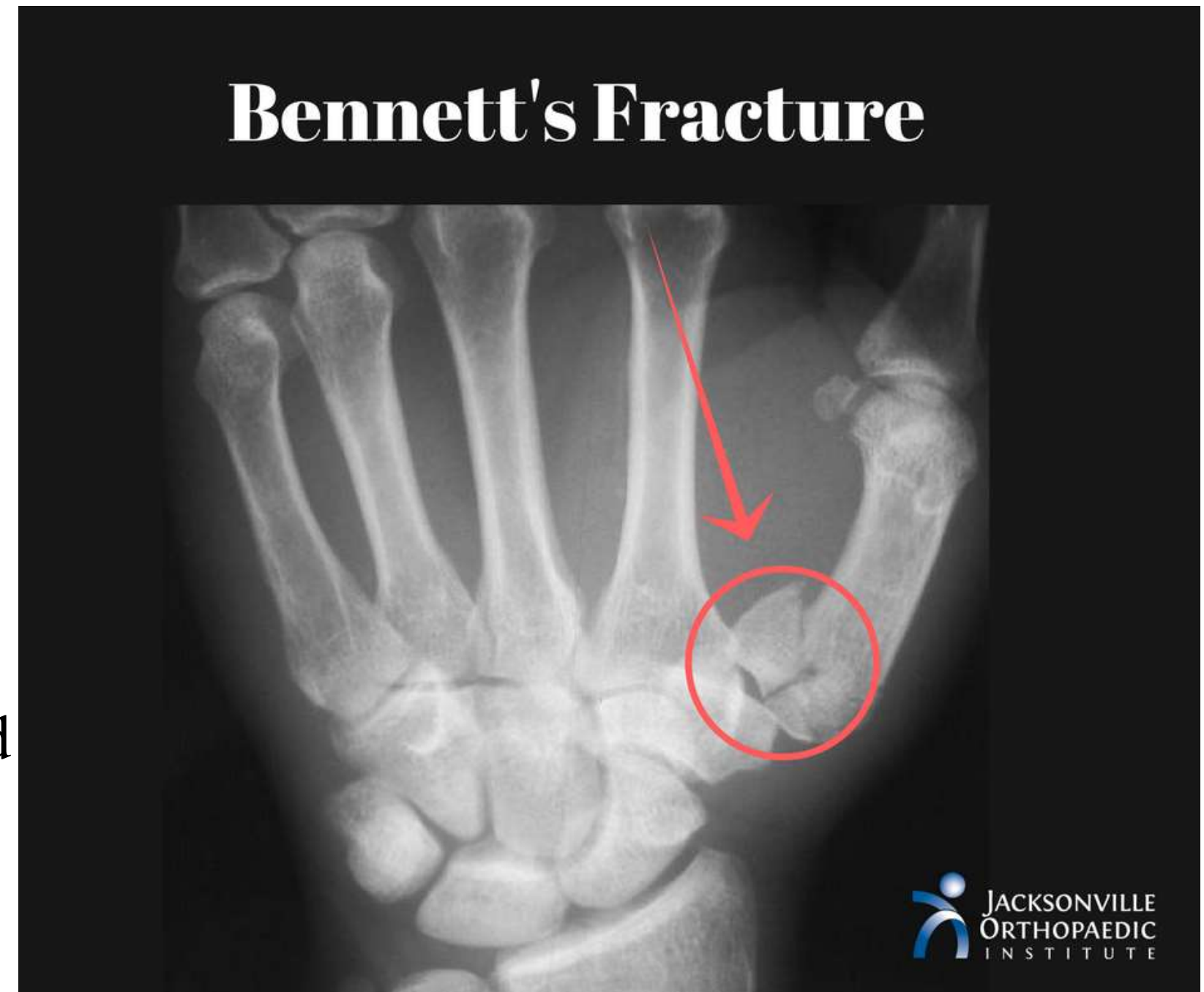It involves the anterior part of the base

## **Mechanism:**

Force along its long axis.

## **Deformation:**

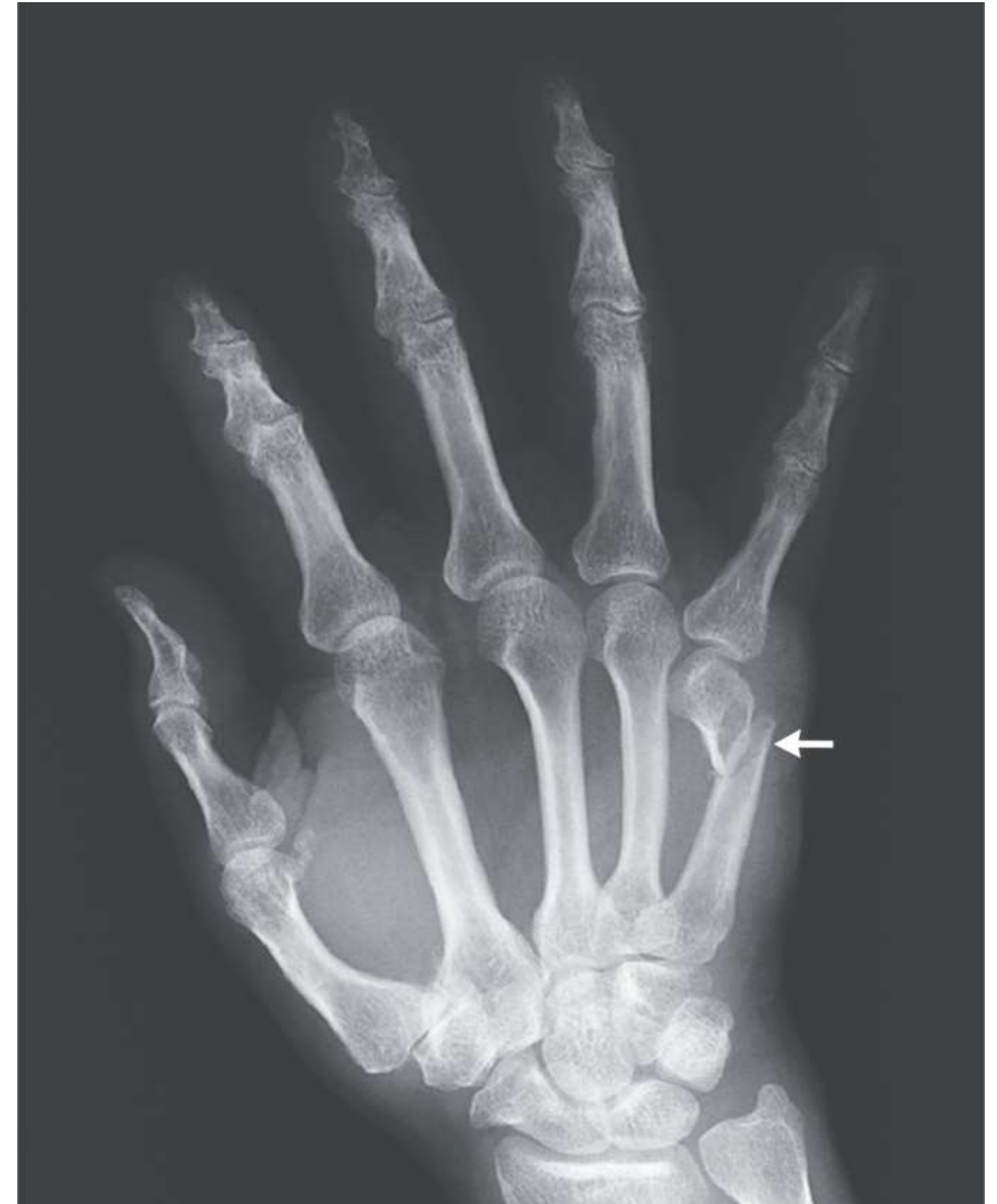- The thumb is forced into a semiflexed position and cannot be opposed.
- The fist cannot be clenched





# Boxer's fracture

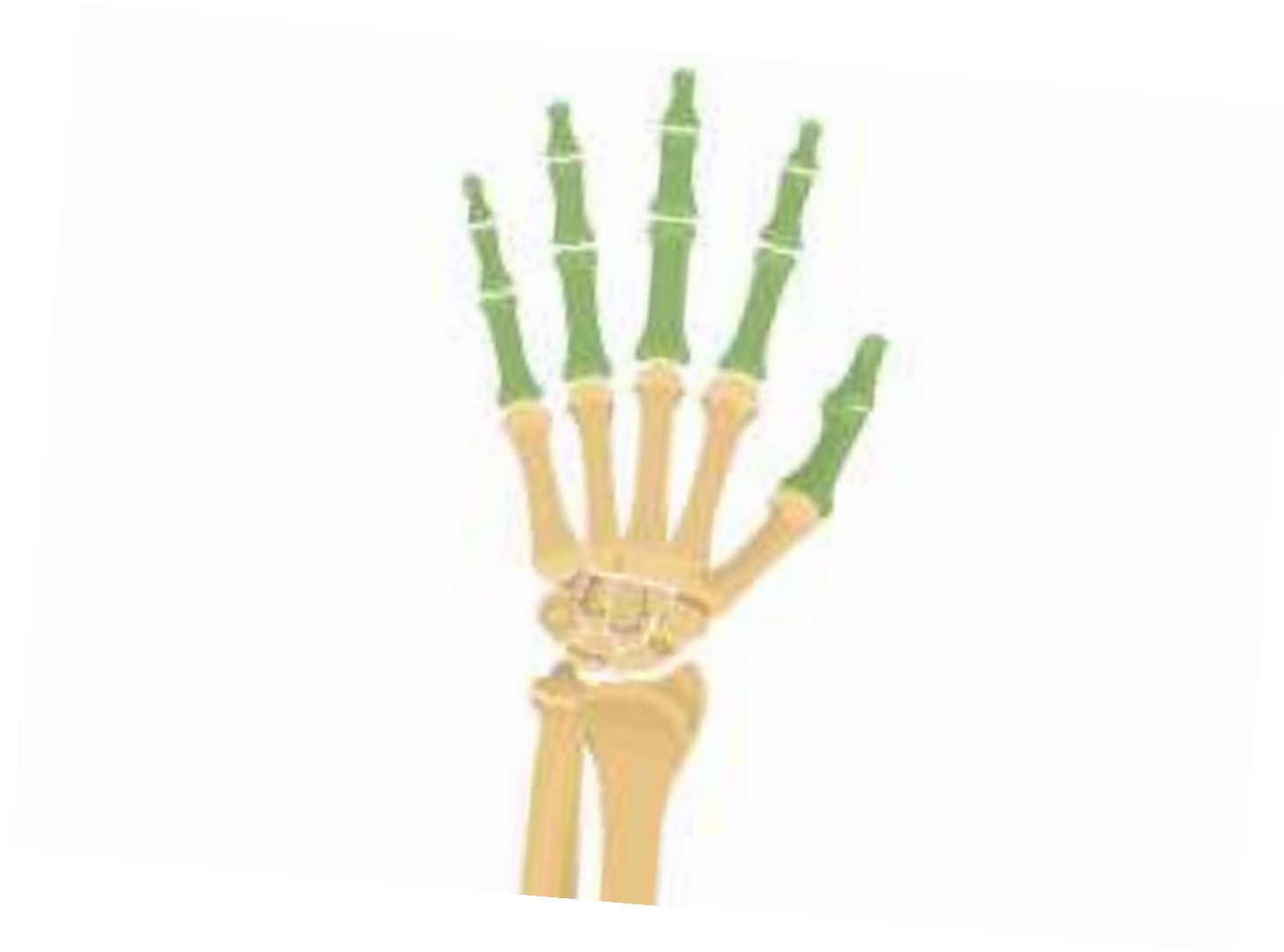- It is fracture of neck of metacarpal
- Most commonly involves neck of 5th metacarpal





# PHALANGES

- Each phalanx is a short long bone
- There are 14 phalanges in each hand
- ❖ **2** in thumb (Proximal and Distal)
- ❖ **3** in each finger (Proximal, Middle and Distal)





# PHALANGES - PARTS



Three parts:

- (a) Base (proximal end)
- (b) Head (distal end)
- (c) Shaft (extending between the two ends).



# PHALANGES - PARTS



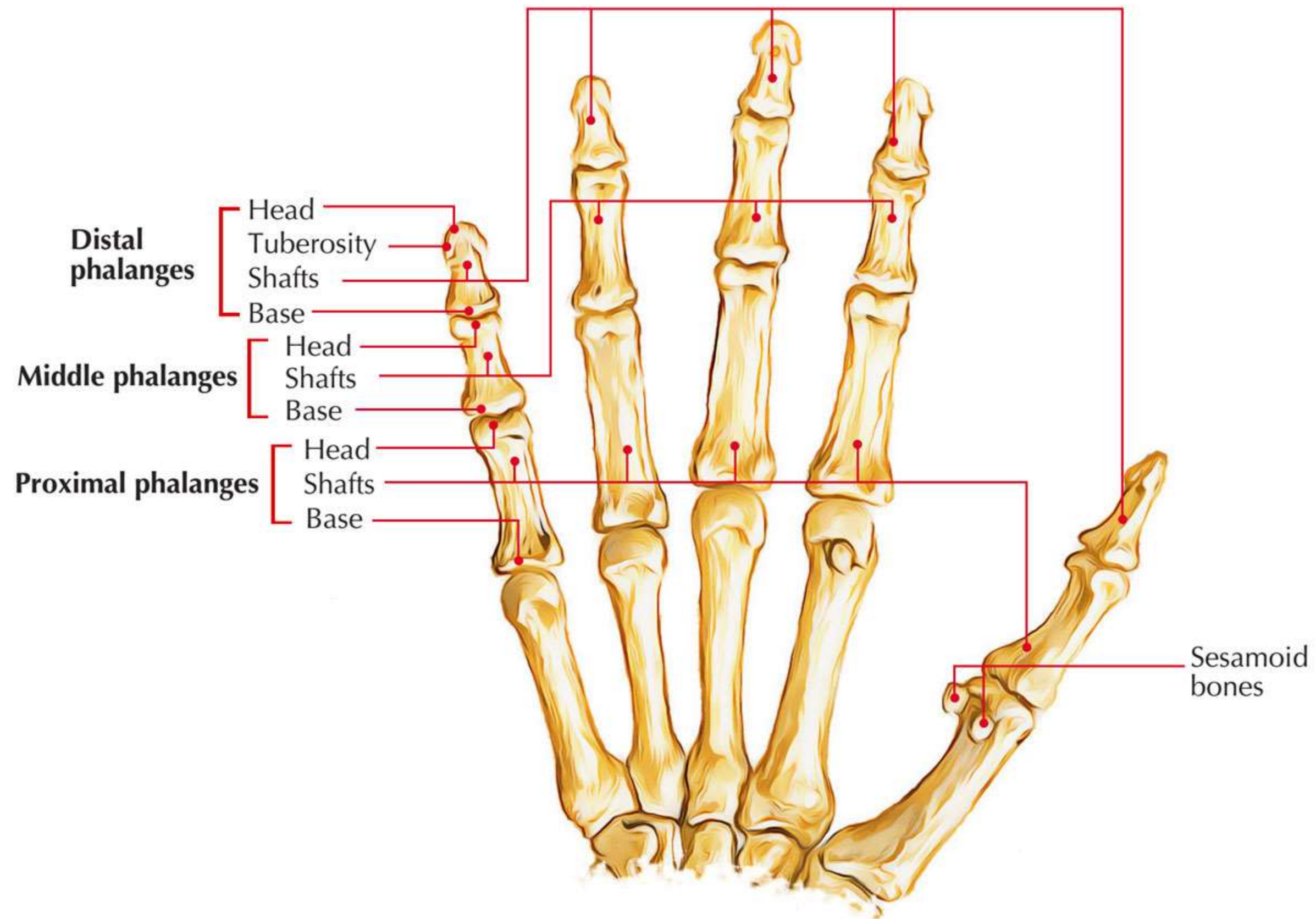
Three parts:

- (a) Base (proximal end)
- (b) Head (distal end)
- (c) Shaft (extending between the two ends).



# PHALANGES - Head

1. The heads of proximal and middle phalanges are pulley shaped.
2. The heads of distal phalanges is non-articular and has rough horseshoe-shaped tuberosity.





# PHALANGES - Shaft

1. The shaft tapers towards the head.
2. The dorsal surface is convex from side to side.
3. The palmar surface is flat from side to side but gently concave in the long axis



# PHALANGES - Base



1. The bases of proximal phalanges have concave oval facet for articulation with the heads of metacarpals.
2. The bases of middle and distal phalanges possess pulleyshaped articular surfaces.



# OSSIFICATION



Each phalanx ossifies by the two centres:

- one primary centre for the shaft
- one secondary centre for the base.

Their time of appearance is as follows:

## **Primary centres**

- For proximal phalanx: 10th week of IUL.
- For middle phalanx: 12th week of IUL.
- For distal phalanx: 8th week of IUL.

## **Secondary centres**

Appearance: 2 years. Fusion: 16 years.





# OSSIFICATION



